

# A Rare Complication During Oxcarbazepine Use, Complete Atrioventricular Block: Case Report

## Oksikarbazepin Kullanımı Sırasında Nadir Görülen Bir Komplikasyon, Atrioventriküler Tam Blok

Turgut KARABAĞ,<sup>a</sup>  
Mustafa AYDIN,<sup>a</sup>  
Sait Mesut DOĞAN<sup>a</sup>

<sup>a</sup>Department of Cardiology,  
Bülent Ecevit University  
Faculty of Medicine, Zonguldak

Geliş Tarihi/Received: 28.01.2011  
Kabul Tarihi/Accepted: 10.04.2011

Yazışma Adresi/Correspondence:  
Turgut KARABAĞ  
Bülent Ecevit University  
Faculty of Medicine,  
Department of Cardiology, Zonguldak,  
TÜRKİYE/TURKEY  
turgutkarabag@yahoo.com

**ABSTRACT** Oxcarbazepine, 10-keto analogue of carbamazepine, is an antiepileptic drug used primarily for the treatment of focal and generalized tonic-clonic seizures in adults and children. Oxcarbazepine has been observed to have a positive effect also on psychiatric diseases and trigeminal neuralgia. Oxcarbazepine like most of antiepileptic drugs, inhibits voltage-dependent fast sodium channels. During oxcarbazepine treatment, side effects such as hyponatremia, headache, vertigo, somnolence, nausea, double vision, vomiting and ataxia can be seen. However, to date, no specific and/or severe cardiac complications of oxcarbazepine have been reported. In this paper, we present a case of complete atrioventricular block that was considered to be caused by oxcarbazepine and that improved after cessation of the drug in a 67-year old female patient with no underlying cardiac etiology.

**Key Words:** Oxcarbazepine; atrioventricular block; partial epilepsies

**ÖZET** Oksikarbazepin, karbamazepinin 10 keto analogu olup, başlıca erişkin ve çocuklarda fokal ve generalize tonik-klonik nöbetlerin tedavisinde kullanılan antiepileptik ilaçtır. Oksikarbazepinin psikiyatrik hastalıklarda ve trigeminal nevraljide de olumlu etkileri olduğu bilinmektedir. Oksikarbazepin birçok antiepileptik ilaç gibi voltaj bağımlı hızlı sodyum kanallarını inhibe ederek etki göstermektedir. Oksikarbazepin tedavisi sırasında, hiponatremi, baş ağrısı, vertigo, somnolans, bulantı, çift görme, ataksi gibi yan etkiler görülebilmektedir. Ancak bugüne kadar oksikarbazepine bağlı spesifik ve/veya ciddi bir kardiyak yan etki bildirilmemiştir. Bu yazıda altta yatan herhangi bir kardiyak etken bulunmayan 67 yaşındaki kadın hastada oksikarbazepine bağlı olduğu düşünülen, ilaç kesildikten sonra düzelen atrioventriküler tam blok olgusu sunulmakta ve olası nedenler tartışılmaktadır.

**Anahtar Kelimeler:** Oksikarbazepin; atriyoventriküler blok; parsiyel epilepsiler

Türkiye Klinikleri J Cardiovasc Sci 2013;25(1):26-8

Oxcarbazepine (OXC), a 10-keto analogue of carbamazepine, is an antiepileptic drug used in the treatment of focal and generalized tonic-clonic seizures as a monotherapy or adjunctive therapy in children and adults.<sup>1</sup> OXC, which has a more favorable adverse effect profile, was developed since carbamazepine has been shown to have unfavourable side effects (dizziness, allergy, nausea, leukopenia), although it has proven to be an effective drug and maintained its antineuralgic effects. In oxcarbazepine treatment, systemic adverse effects such as hyponatremia, diarrhea, insomnia, dizziness, hepatitis and neutropenia have been reported; however, there

are only a few published reports on cardiac adverse effects of OXC in human.<sup>2-5</sup> Even though potential side effects include conduction disturbances,<sup>6</sup> to the best of our knowledge, there is no such a case reported in the literature. In this study, we present a case of complete atrioventricular (AV) block in a 67-year old female patient with a 2-year history of oxcarbazepine use due to partial seizures who presented to our clinic with complaints such as headache and fatigue.

## CASE REPORT

A 67-year old female patient who had been receiving OXC 300 mg twice a day for two years because of partial seizures, presented to the emergency service with severe headache and fatigue. The patient stated that she had complaints of intermittent headache and fatigue since administration of the drug, however, she did not abandon the drug. She reported to have no diseases other than hypertension and hence, she had only been receiving cilazapril/hydrochlorothiazid, 5/12.5 mg. On admission to the emergency department, the patient was conscious and alert. Vital signs were as follows: blood pressure 100/ 60 mmHg, pulse 30/min. Cardiac examination revealed no findings other than the bradycardia. Other system examinations were normal. An electrocardiogram (ECG) showed that the patient was bradycardic and complete AV block was present (Figure 1). The analysis of blood samples revealed that kidney, liver and thyroid functions were normal and cardiac enzymes were also within normal limits. Electrolyte levels were also found to be normal (Na: 133 mEq/l, K:4.1 mEq/l). The patient was transferred to the cardiol-

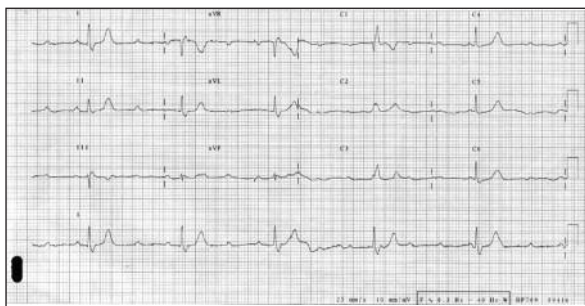


FIGURE 1: Figure showing complete atrioventricular block.

ogy clinic due to the diagnosis of complete atrioventricular block. A temporary pacemaker was implanted in the patient. On the electrocardiogram, normal ejection fraction and grade 1 diastolic dysfunction were observed. After consultation with the neurology department, OXC was discontinued and the patient was begun on levetiracetam 500 mg 2x1. The electroencephalogram revealed no pathology. Coronary arteries were normal on the coronary angiogram performed to exclude a coronary etiology, due to the age of the patient. Three days after the cessation of OXC, the patient developed 2:1 AV block (Figure 2), followed by normal sinus rhythm (Figure 3). A 24-hour holter monitor revealed no arrhythmia. The temporary pacemaker was removed and the patient was discharged with levetiracetam 500 mg 2x1 and same antihypertensive therapy. No bradycardia or conduction disorders were detected during follow-up examinations.

## DISCUSSION

OXC is structurally and chemically similar to carbamazepine, however, it is not metabolized to epoxide metabolites, which are responsible for toxic effects of carbamazepine. Carbonyl group of the OXC undergoes systemic 10-keto reduction and is converted to a 10-monohydroxy derivate (MHD), which is responsible for in vivo pharmacological effects.<sup>7</sup> Although MHD and carbamazepine share a common mechanism of action in blocking sodium channels, they modulate different calcium channels<sup>6</sup>. MHD blocks voltage-sensitive sodium channels and reduces the rate of phase 4 depolarization in cardiac pacemaker cells.<sup>6,7</sup> OXC prolongs inactive periods of sodium channels. An effect on potassium channels was demonstrated by McLean et al. in an experimental study.<sup>8</sup> Since potassium plays major role in phase 4, we speculate that another reason of complete AV block might be the effect of OXC on potassium channels. Because of these reasons, OXC may suppress idioventricular pacemaker and may aggravate the bradycardia of complete heart block.<sup>5</sup>

There are few studies demonstrating effects of OXC on conduction pathways.<sup>2</sup> In a prescription-

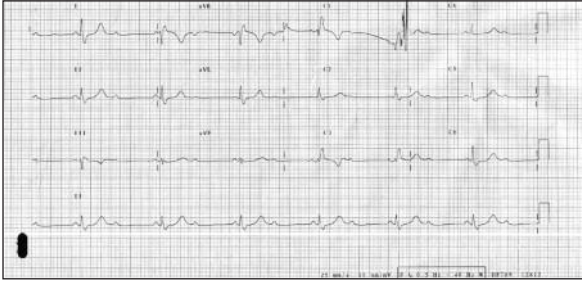


FIGURE 2: Figure showing 2:1 atrioventricular block.

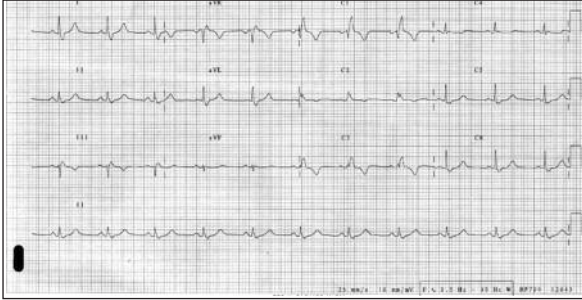


FIGURE 3: Figure showing normal sinus rhythm.

event monitoring study of 2243 patients prescribed oxcarbazepine in England, only one patient developed tachycardia, with no need for follow-up and no cases of conduction disorders were reported.<sup>6</sup> In another study involving 174 children with epilepsy, effects of antiepileptic drugs, including OXC, on QT interval on the surface ECG were examined and it was concluded that these drugs did not prolong QT interval. However, it was demonstrated that patients receiving these drugs were at risks for electrolyte disorders, liver-renal failure and interaction with other drugs used.<sup>9</sup>

Patients receiving OXC therapy, particularly those with cardiovascular disease, liver-renal failure and electrolyte disorders, should be closely followed up for the possibility of a conduction disorder. However, conduction pathway disorders can also be seen in healthy individuals. Patients should be closely monitored and evaluated for this condition.

## REFERENCES

1. Bozdemir H, Aslan K, Koç F, Sarıca Y. [The efficiency of carbamazepine and oxcarbazepine in partial seizures]. *Turkiye Klinikleri J Med Sci* 2005;25(4):513-8.
2. Jolliff HA, Fehrenbacher N, Dart RC. Bradycardia, hypotension and tinnitus after accidental oxcarbazepine overdose. *Clin Toxicol* 2001;39(3):316-7.
3. Raja M. Oxcarbazepine, risperidone and atenolol overdose with benign outcome. *Int J Neuropsychopharmacol* 2003;6(3):309-10.
4. Hsu HF, Huang SY. Severe hepatitis associated with administration of oxcarbazepine. *Pediatr Int* 2010;52(4):677-8.
5. Hsiao YT, Wei IH, Huang CC. Oxcarbazepine-related neutropenia: a case report. *J Clin Psychopharmacol* 2010;30(1):94-5.
6. Buggy Y, Layton D, Fogg C, Shakir SAW. Safety profile of oxcarbazepine: results from a prescription-event monitoring study. *Epilepsia* 2010;51(5):818-29.
7. Van Opstal JM, Janknegt R, Cilissen J, L'Ortije WHVM, Nel JE, et al. Severe overdose with the antiepileptic drug oxcarbazepine. *Br J Clin Pharmacol* 2004;58(3):329-31.
8. McLean MJ, Schmutz M, Wamil AW, Olpe HR, Portet C, Feldmann KF. Oxcarbazepine: mechanisms of action. *Epilepsia* 1994;35 (Suppl 3):S5-9.
9. Kwon S, Lee S, Hyun M, Choe BH, Kim Y, Cho Y. The potential for QT prolongation by antiepileptic drugs in children. *Pediatr Neurol* 2004;30(2):99-101.