

Variation of the Mandibular Canal: Case Report

Mandibular Kanal Varyasyonu

Eray KOLSUZ,^a
Şebnem KURŞUN,^b
Kemal Özgür DEMİRALP^c

^aDepartment of Dentomaxillofacial
Radiology,
Ankara University Faculty of Dentistry,
Ankara

^bDivision of Dentomaxillofacial Radiology,
Bolu Oral and Dental Health Center,
Bolu

^cMinistry of Health,
Public Hospitals Agency of Türkiye
Ankara

Geliş Tarihi/Received: 13.11.2014
Kabul Tarihi/Accepted: 16.02.2015

Yazışma Adresi/Correspondence:
Şebnem KURŞUN
Bolu Oral and Dental Health Center,
Division of Dentomaxillofacial Radiology,
Bolu,
TÜRKİYE/TURKEY
sebnemkursun@yahoo.com.tr

ABSTRACT It has vital importance to know the details of anatomical variations of mandibular canal such as double mental foramen, bifid mandibular canal for surgical intervention. One bifid mandibular canal is so-called retromolar canal is an anatomical structure on the alveolar surface of the retromolar area. The presence of a retromolar canal may hamper obtaining anaesthesia of buccal and retromolar mucosa. Lower third molar region has complicated anatomical structure. The detection of the anatomical variations such as retromolar canal is important because of its clinical implications. Cone beam computed tomography (CBCT) provides valuable diagnostic information in the detection of anatomical structures. In this case report, the incidentally found retromolar canal in a 30-year-old female patient is presented by using panoramic and CBCT views.

Key Words: Mandibular nerve; cone-beam computed tomography; radiography, panoramic

ÖZET Çift mental foramen, çift mandibular kanal gibi mandibular kanaldaki anatomik varyasyonların bilinmesi cerrahi müdahale için hayati önem teşkil etmektedir. "Retromolar kanal" olarak adlandırılan çift mandibular kanal retromolar bölgenin alveolar yüzeyinde izlenen anatomik yapıdır. Retromolar kanal mevcudiyeti bukkal ve retromolar mukozanın anestezisini engelleyebilir. Alt yirmi yaş diş bölgesinin anatomik yapısı karmaşıktır. Retromolar kanal gibi anatomik varyasyonların tespiti klinik sonuçlar bakımından önemlidir. Konik Işınlı Bilgisayarlı Tomografi (KİBT) anatomik yapıların tespitinde teşhis açısından değerli bilgi sağlar. Bu vaka raporunda, 30 yaşındaki kadın hastada panoramik ve KİBT kullanılarak tesadüfen tespit edilmiş retromolar kanal sunulmaktadır.

Anahtar Kelimeler: Nervus mandibula; konik ışınli bilgisayarlı tomografi; radyografi, panoramik

Türkiye Klinikleri J Dental Sci Cases 2015;1(1):22-6

The mandibular canal (MC) is usually a single channel, enclosed by bony tissue, forming an upward concave curve.¹ Visibility of the MC may vary between patients and even between different areas of the mandible. The canal is usually more readily identified in posterior areas and the visibility tends to decrease gradually towards the mental foramen.²

The canal which houses the inferior alveolar nerve and blood vessels, begins at the mandibular foramen, curves downward and forward, and turns into a horizontal course below the roots of the molars. In the region of premolars the mandibular canal splits into two canals of unequal width: the narrower incisive canal continues the course of the mandibular canal to-

ward the midline; the wider branch, the mental canal, turns laterally, superiorly, and posteriorly to open at the mental foramen.³ In medical imaging, its appearance has been described as “a radiolucent ribbon between two white lines”.⁴

Although the canal has generally been known to be a single structure since 1973, variations such as bifid and trifid canals have been reported.⁵ The term bifid is derived from the Latin word meaning cleft into 2 parts of branches.⁶ The various types of bifid mandibular canals have been classified according to anatomical location and configuration.

Retromolar canal (RMC) is often treated as a subtype of the bifid mandibular canal.⁷ Some researchers suggest that the contents of this canal originate from the mandibular neurovascular bundle before it enters the mandibular canal, while others suggest that these elements arise from the neurovascular bundle in the mandibular canal and lie in the buccal region.⁸

Ossenberg classified the RMC into three types. The first type branches of the mandibular canal distal to the 3rd molar region and courses posterosuperiorly to open into the retromolar fossa. The second type also branches from the mandibular canal just beneath the mandibular foramen and runs anterosuperiorly to exit the mandible higher up in the retromolar fossa. The third type which is rarely seen, has its posterior opening behind the temporal crest and its anterior opening in front of the temporal crest in the retromolar fossa.^{9,10}

Up to now, there has been numerous of studies regarding MC variations with panoramic radiographies, computed tomography (CT) and cone-beam computed tomography (CBCT). Dental panoramic radiographies have limitations in the detection of MC variations because of their 2 dimensional characteristics. When compared to conventional CT, data from the craniofacial region obtained by CBCT are often collected at higher resolution, at lower cost and absorbed doses.¹¹

This case report presents incidentally found retromolar canal which is a mandibular canal variant of a 30-year-old patient by using panoramic radiography and CBCT.

CASE REPORT

A 30-year-old female patient was attended to Department of Dentomaxillofacial Radiology in 2012 with a complaint of pain in the left maxilla because of the impacted canine tooth. Medical history indicated that the patient was in excellent health. On the panoramic radiography (Figure1), retromolar canal was observed on the left side of the mandible ramus. CBCT (Planmeca ProMax 3D Proface, Helsinki, Finland) evaluation with multiplanar and 3 dimensional reconstructed images confirmed the existence of retromolar canal splitting higher up near the foramen and coursing to the anterior region and terminating with an opening beneath coronoid process and over the retromolar fossa (Figure 2, 3a and 3b, 4, 5a, 5b). The patient experienced severe pain during the palpation of the soft tissue where the retromolar canal opening exist because of the direct relation with soft tissue. Because of the absence of spontaneous pain, the patient is now in routine follow-up.

DISCUSSION

Retromolar foramen is an opening in the triangular area, posterior to the third molar tooth which is named as retromolar fossa.¹² The frequency of retromolar foramen was stated between 3.2% and 72% in the previously published reports.^{5,7,8,12,13} Kawai et al., stated that the blood vessels and the nerve in the RMC that diverged from the mandibular canal had an orifice from the mandible through the RMF.⁷ Anderson et al., affirmed that the predominant components in the retromolar foramen and canal are nerves that provide innervation of

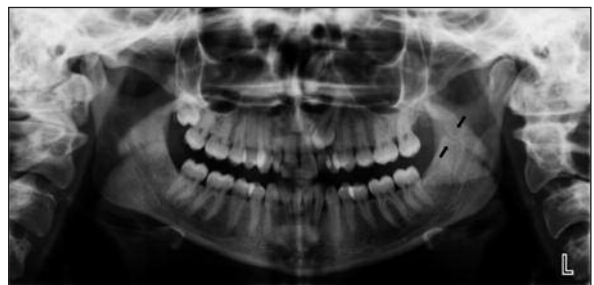

FIGURE 1: Panoramic radiograph of the patient. Retromolar canal is observed between the black arrows.

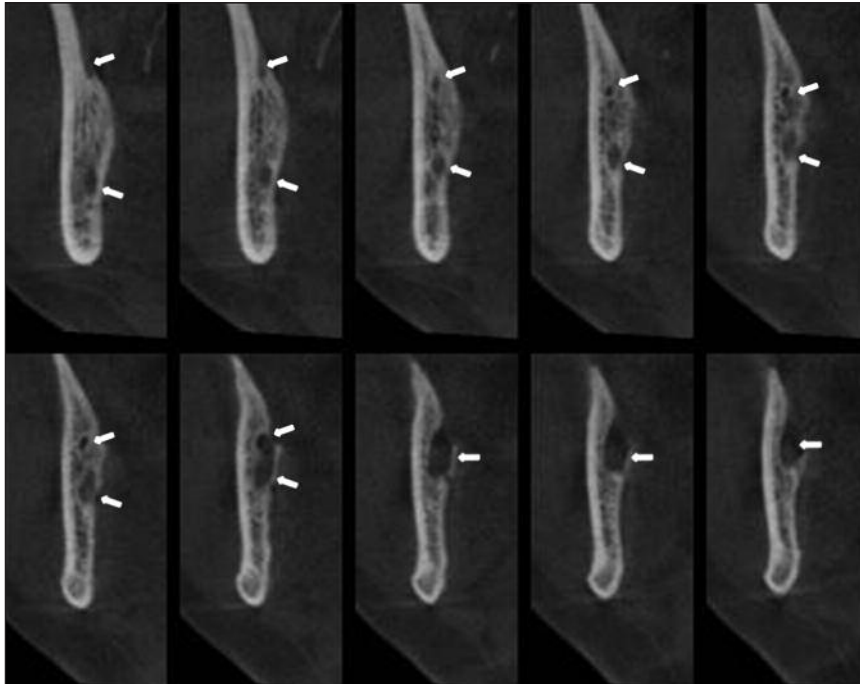


FIGURE 2: Reconstructed cross-sectional images showing retromolar canal bifurcated from the main canal. Upper arrows: retromolar canal, Inferior arrows: mandibular canal.

the pulp of third molar, retromolar region, fibers of the temporalis and buccinator muscles.¹⁴

Since the RMC is generally very narrow, it is difficult to detect smaller sized RMCs on panoramic radiographs. In addition because the images in the retromolar region overlap the shadow of the opposite mandible, such as soft palate, the detailed status of the RMC may be difficult to depict on panoramic radiographs.⁷ So routine two-dimensional investigations are not reliable for identifying these anatomical variants and three-dimensional image examination is the only means of diagnosing anatomical variants.¹⁵

Naitoh et al., investigated the RMC by using clinical CBCT images and observed the RMC at a frequency of 25.4% per mandible and 13.5% per side.¹⁶ Lizio et al., evaluated the 233 hemi-mandibles by using CBCT for analysing the prevalence of RMC and retromolar foramen (RMF).¹⁵ They have stated thirty-four retromolar canals with a foramen with a frequency of 14.6%.

von Arx et al., analysed 121 mandibular posterior area in 100 patients with CBCT. The frequency of RMC was stated 31 with ratio 25.6%.¹⁷ Of these only 7 canal were observed in

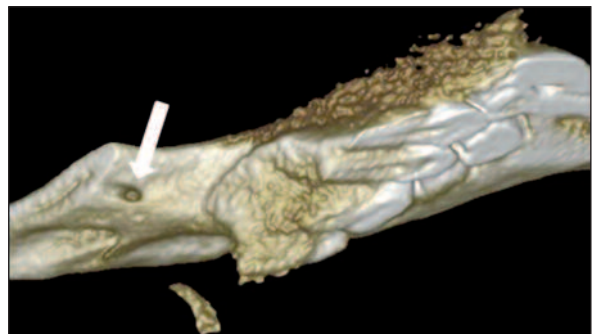


FIGURE 3a: Medial view of the 3D reconstructed image. Arrow shows the retromolar foramen in the retromolar fossa.

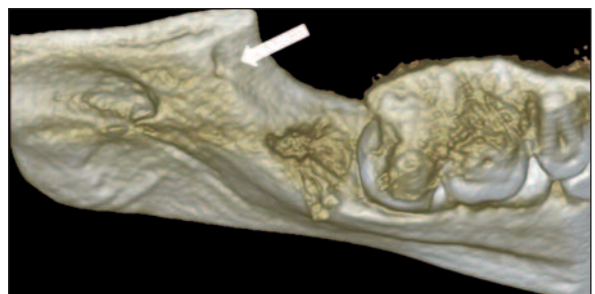


FIGURE 3b: Superior view of the 3D reconstructed image. Arrow shows the retromolar foramen in the retromolar fossa.

panoramic radiography. They found no correlation between gender, side and the existence of RMC.

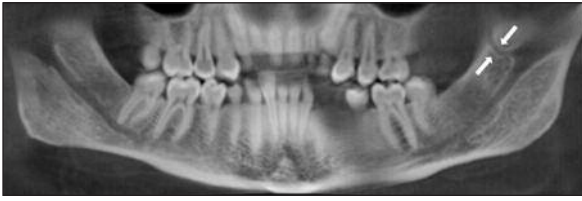


FIGURE 4: Reconstructed panoramic image of the patient. Retromolar canal is observed between the white arrows.

In different populations including Japan, Eskimos, Latin America, Italy, the incidence of RMF and RMC have been evaluated by several researchers. The incidence of RMF in eighty sides of 40 mandibles has been found 25% in a population of Turkey by Bilecenoğlu and Tuncer.⁸ Most of the studies in the literature have stated that retromolar canals commonly occur unilaterally as observed in the present case report.¹⁸ Minority of cases were bilaterally in the studies of Bilecenoğlu and Tuncer, Lizio et al., with the ratios 20% and 8.7%, respectively. Patil et al. did not observe any difference in the occurrence of retromolar canal

with regard to gender similar to the studies of Bilecenoğlu and Tuncer, Narayana et al., and von Arx et al.^{8,12,15,17,19}

The presence of anatomical variations such as the retromolar canal and foramen can cause complications if not previously identified. These elements may be injured in the diresis procedures, flap lifting, bone tissue for autologous bone grafts, osteotomy for the surgical extraction of lower third molars, placement of osseointegrated implants for orthodontic or during the division of the mandibular ramus in the sagittal split osteotomy surgery.¹⁹

Pinsolle et al., cited that RMC allow the passage of vascular components and this may facilitate the spread of infection and metastases from the oropharynx.²⁰

In sum, the lower third molar region has great importance in dental practice because of the complicated anatomical structure. Clinicians should be aware of the anatomical variations such as retromolar canals in order to avoid undesirable complications.

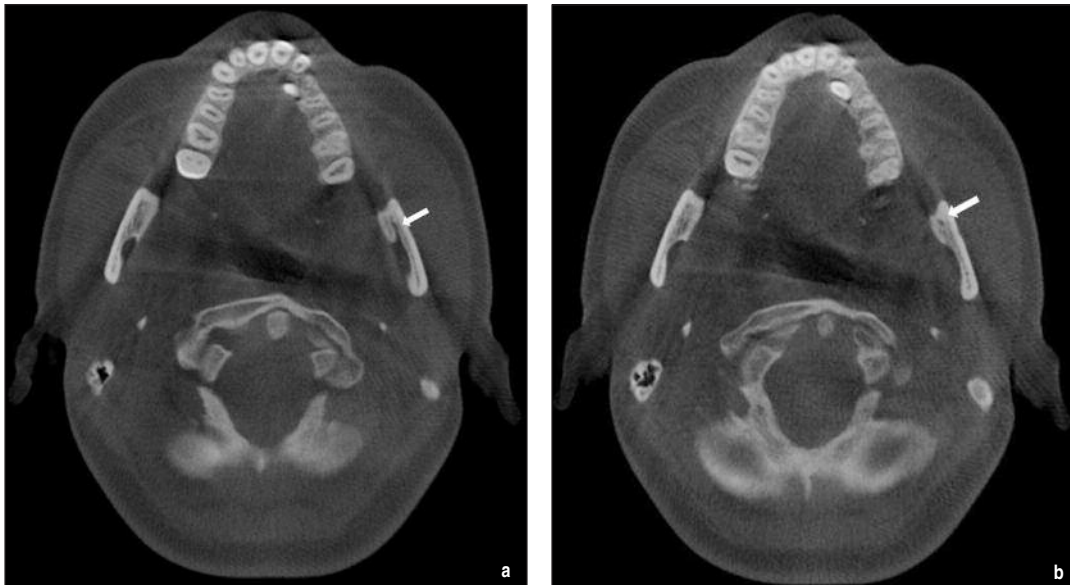

FIGURE 5a, b: In axial image arrow shows the retromolar foramen.

REFERENCES

- Rouas P, Nancy J, Bar D. Identification of double mandibular canals: literature review and three case reports with CT scans and cone beam CT. *Dentomaxillofac Radiol* 2007;36(1): 34-8.
- Oliveira-Santos C, Capelozza AL, Dezzoti MS, Fischer CM, Poleti ML, Rubira-Bullen IR. Visibility of the mandibular canal on CBCT cross-sectional images. *J Appl Oral Sci* 2011;19(3): 240-3.
- Sicher H, DuBrul EL. *The Skull*. Oral Anatomy. 6th ed. St. Louis: Mosby Co;1975. p.7-133.
- Worth HM. Normal radiographic appearances of the teeth and jaws and variations within the normal. *Principals and Practice of Oral Radiologic Interpretation*. 1st ed. Chicago:IL: Year Book Medical Publishers;1963.p.15-79.
- Orhan K, Aksoy S, Bilecenoglu B, Sakul BU, Paksoy CS. Evaluation of bifid mandibular canals with cone-beam computed tomography in a Turkish adult population: a retrospective study. *Surg Radiol Anat* 2011;33(6):501-7.
- Auluck A, Mupparapu M. Multiple mandibular nerve canals: radiographic observations and clinical relevance. Report of 6 cases. *Quintessence Int* 2007;38(9):781-7.
- Kawai T, Asaumi R, Sato I, Bhat JG, Devaiah BA. Observation of the retromolar foramen and canal of the mandible: a CBCT and macroscopic study. *Oral Radiol* 2012;28(1): 10-4.
- Bilecenoglu B, Tuncer N. Clinical and anatomical study of retromolar foramen and canal. *J Oral Maxillofac Surg* 2006;64(10):1493-7.
- Ossenberg NS. Temporal crest canal: case report and statistics on a rare mandibular variant. *Oral Surg Oral Med Oral Pathol* 1986; 62(1):10-2.
- Ossenberg NS. Retromolar foramen of the human mandible. *Am J Phys Anthropol* 1987; 73(1):119-28.
11. Tyndall DA, Rathore S. Cone-beam CT diagnostic applications: caries, periodontal bone assessment, and endodontic applications. *Dent Clin N Am* 2008;52(4):825-41.
- Narayana K, Nayak UA, Ahmed WN, Bhat JG, Devaiah BA. The retromolar foramen and canal in South Indian dry mandibles. *Eur J Anat* 2002;6(3):141-6.
- Potu BK, Kumar V, Salem AH, Abu-Hijleh M. Occurrence of the retromolar foramen in dry mandibles of South-eastern part of India: a morphological study with review of the literature. *Anat Res Int* 2014; 2014:296717.
- Anderson LC, Kosinski TF, Mentag PJ. A review of the intraosseous course of the nerves of the mandible. *J Oral Implantol* 1991;17(4): 394-403.
- Lizio G, Pelliccioni GA, Ghigi G, Fanelli A, Marchetti C. Radiographic assessment of the mandibular retromolar canal using cone-beam computed tomography. *Acta Odontol Scand* 2013;71(3-4): 650-5.
- Naitoh M, Hiraiwa Y, Aimiya H, Arijii E. Observation of bifid mandibular canal using cone-beam computerized tomography. *Int J Oral Maxillofac Implants* 2009;24(1):155-9.
- von Arx T, Hänni A, Sendi P, Buser D, Bornstein MM. Radiographic study of the mandibular retromolar canal: an anatomic structure with clinical importance. *J Endod* 2011;37(12): 1630-5.
- Patil S, Matsuda Y, Nakajima K, Araki K, Okano T. Retromolar canals as observed on cone-beam computed tomography: their incidence, course, and characteristics. *Oral Surg Oral Med Oral Pathol Oral Radiol* 2013;115(5): 692-9.
- Reyneke JP, Tsakiris P, Becker P. Age as a factor in the complication rate after removal of unerupted/impacted third molars at the time of mandibular sagittal split osteotomy. *J Oral Maxillofac Surg* 2002;60(6):654-9.
- Pinsolle V, Truilhe Y, Majoufre C, Michelet V, Pinsolle J. Posterior marginal mandibulectomy for cancer of the oral cavity and oropharynx. Experience with 14 clinical cases. *Ann Chir Plast Esthet* 1997;42(3):223-7.