

# Jejunal Diverticulosis Cases Involving Massive Gastrointestinal Bleeding and Diagnosed Incidentally: A Report of Two Cases

## Tesadüfen Saptanan ve Masif Gastrointestinal Kanamaya Neden Olan Jejunal Divertikülozis Olguları: İki Olgunun Sunumu

Rojbin KARAKOYUN,<sup>a</sup>  
Ayşe ARDUÇOĞLU MERTER,<sup>a</sup>  
Hasan ALTUN,<sup>b</sup>  
Barış Rafet KARAKAŞ,<sup>a</sup>  
Oktay BANLI<sup>c</sup>

<sup>a</sup>Clinic of Surgery,  
Antalya Training and Research Hospital,  
Antalya

<sup>b</sup>Clinic of Surgery,  
Liv Hospital, İstanbul,

<sup>c</sup>Department of Surgery,  
Bozok University Faculty of Medicine,  
Yozgat

Geliş Tarihi/Received: 24.12.2013

Kabul Tarihi/Accepted: 23.04.2014

Yazışma Adresi/Correspondence:

Hasan ALTUN  
Liv Hospital,  
Clinic of Surgery, İstanbul,  
TÜRKİYE/TURKEY  
haltun@hotmail.com.tr

**ABSTRACT** Jejunal diverticulosis is a rarely encountered condition typically diagnosed incidentally during laparotomy or radiological examination. Despite its rarity, this condition poses a serious risk of mortality and morbidity in the event of complications. Massive gastrointestinal (GI) bleeding due to jejunal diverticulosis is a particularly serious risk, evidenced by its high rate of mortality as a result of delayed diagnosis. A 60-year old female and a 75-year old female patients were admitted to the emergency department due to gastrointestinal bleeding. The diagnosis of jejunal diverticulosis was established during the operation. Here we present two cases in which we incidentally diagnosed jejunal diverticulosis during surgical treatment of massive lower and upper GI hemorrhage originating from the subject matter condition.

**Key Words:** Gastrointestinal hemorrhage; emergency treatment

**ÖZET** Jejunal divertikülozis nadir görülür ve genellikle laparotomi veya radyolojik araştırmalarda tesadüfi olarak saptanır. Fakat, bu durum komplikasyonlara yol açtığında mortalite ve morbiditeye neden olabilir. Özellikle jejunal divertikülozise bağlı masif gastrointestinal kanamada gecikmiş tanıya bağlı mortalite oranı oldukça yüksektir. 60 yaşında ve 75 yaşında bayan hastalar acile gastrointestinal kanama şikayeti ile başvurdular. Hastalara jejunal divertikülozis tanısı ameliyat esnasında konuldu. Biz bu çalışmada sebebi bulunamayan alt ve üst gastrointestinal kanama nedeniyle ameliyat edilen hastalarda insidental saptanan jejunal divertikülozis olguları sunuyoruz.

**Anahtar Kelimeler:** Gastrointestinal kanama; acil tedavi

**Türkiye Klinikleri J Case Rep 2015;23(3):239-42**

Jejunal diverticulosis is a rare condition typically diagnosed incidentally during laparotomy or radiological examination. Although its incidence remains unclear, it is estimated to range between 0.073% and 1.3%, specifically between 0.073% and 1.3% on radiological examination and between 0.073% and 0.8% on autopsy.<sup>1</sup> The condition may be congenital or acquired and is associated with advanced age, with the incidence increasing in the sixth and seventh decades of life.<sup>2</sup> Among small-intestine diverticulum cases other than those involving the duodenum, 80% have been observed in the jejunum, 15% in the ileum, and 5% in both.<sup>3</sup> The probability of a complication is approximately 10% to 30%, among which acute complications include diverticulitis with perforation and abscess, bleeding, and mechanical intestinal obstruction.<sup>4</sup>

doi: 10.5336/caserep.2013-38254

Copyright © 2015 by Türkiye Klinikleri

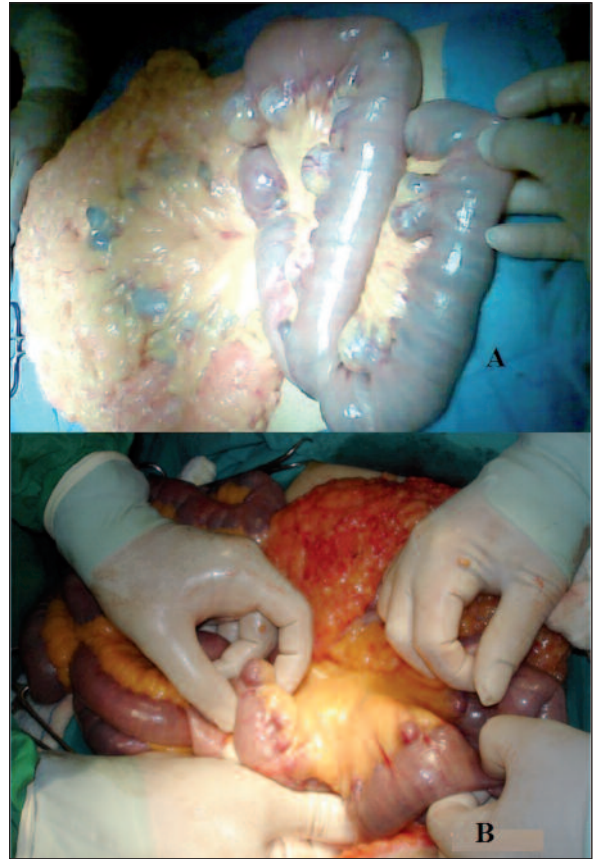
Here we describe our incidental diagnosis and treatment of two cases of asymptomatic jejunal diverticulosis causing massive gastrointestinal (GI) bleeding during surgery to treat upper GI hemorrhage.

## CASE REPORTS

### CASE REPORT 1

A 60-year-old female was admitted to the emergency medical service with lower GI hemorrhage that had been continuous for a 24 h. Her vital signs upon admittance were blood pressure of 110/70 mmHg and pulse of 95 beats/min. The abdomen was tender in the epigastric area without rebound or guarding on physical examination, and maroon stools were observed on rectal examination. Routine hematological analysis revealed a hematocrit (Htc) level of 27%, hemoglobin (Hb) level of 9 g/dL, and biochemical values within normal parameters. Active bleeding was not observed on upper GI endoscopy. Colonoscopy revealed maroon stools throughout the colon and several diverticula in the sigmoid segment of the colon, but no active hemorrhage source for any of the latter. The patients was treated with transfusion of 4 units of blood.

Upon follow-up examination, the patient displayed symptoms of shock, a decrease in blood pressure to 90/50 mmHg, and an increase in pulse to 100 beats/min. After measurement of an Htc level of 15% and an Hb level of 5 g/dL, she was rushed to surgery. On surgical examination, multiple diverticula at the mesenteric side were found to be distributed from 20 to 50 cm distal to the ligament of Treitz (Figure 1) and the segment of the small intestine and colon to be filled with blood. Enteroscopy was performed from the distal part of the diverticular segment using an intraoperative colonoscopy device. During this procedure, active hemorrhage in one of the jejunal diverticulum was observed. Forty centimeters of the small intestine covering the entire jejunal diverticulum was resected and end-to-end anastomosis was performed. On postoperative follow-up, the patient's vital signs were stable and no signs of hemorrhage were observed. The patient began to feed orally on the fifth



**FIGURE 1:** (A) Case 1 presenting with bleeding from diverticula. (B) Case 2 presenting with bleeding from duodenal ulcer.

postoperative day. By the eighth postoperative day, her general condition had improved to an extent sufficient for discharge. On pathological examination, multiple diverticulum, the largest being 3 cm in diameter in the segment of the jejunum, as well as an ulcerous lesion including epithelium erosion on a 2-cm diverticulum base were observed.

### CASE REPORT 2

A 75-year-old female was admitted to the emergency service complaining of coffee-ground vomitus. No pathological symptom was observed other than tenderness in the epigastric area on physical examination, and a normal stool smear was obtained on rectal examination. Upon admittance, her vital signs were blood pressure of 90/60 mmHg and pulse of 100 beats/min, and her laboratory values were Htc level of 21% and Hb level of 6.7 g/dL. All other parameters were within normal ranges.

After treatment by transfusion of 5 units of blood, no pathologies were observed on subsequent colonoscopy. On initial endoscopic examination, bright red blood in the stomach and a pulsatile hemorrhagic focus was observed on the ulcer base at the bulbous. Bleeding could not be stopped with the administration of injection treatment. When stabilization could not be achieved in spite of resuscitation, the patient was rushed to surgery. On surgical examination, multiple diverticula at the mesenteric side distributed from 30 to 100 cm distal to the ligament of Treitz were observed (Figure 1B). The active bleeding source at the bulbous was reached by means of a duodenotomy, and after hemostasis was achieved through suturing on the base of the ulcer, the duodenum was primarily repaired. Intraoperatively, blood pressure increased to 120/70 mmHg and pulse decreased to 80 beats/min. As no bleeding source was observed in the segment of the diverticular jejunum, resection was not performed. During the postoperative period, no bleeding symptoms were observed. The patient began to feed orally on the fourth day as her vital signs displayed a stable trend. The patient was discharged on the sixth day after further medical treatment was arranged.

## DISCUSSION

Jejunal diverticulosis is typically asymptomatic and its diagnosis primarily incidental. However, symptoms such as nonspecific stomach pain, dyskinesia, chronic anemia, and malabsorption are sometimes observed, and 15% of patients who develop complications may need surgery.<sup>3,5</sup>

It is difficult and sometimes not possible to diagnose preoperative hemorrhage of jejunal diverticulosis. In many studies, techniques such as selective angiography, nuclear scanning, endoscopic analysis, and contrast-radiology examination have been used to localize the site of the hemorrhage. However, preoperative methods of diagnosis are usually unsuccessful.<sup>6</sup> This challenge was encountered with the first case presented here, for which the source of bleeding could not be determined on preoperative colonoscopy or endoscopy. Diagnosis was only possible intraoperatively after the patient had been rushed to emergency surgery

upon displaying unstable hemodynamics. In the second case presented here, an ulcer with active bleeding was identified in the bulbous.

According to some researchers, intraoperative endoscopy can be an alternative method of diagnosis. However, the risk of contamination of the surgical area must be taken into consideration when considering this method. In our first case, diagnosis of the active source of hemorrhage in the jejunum was possible by means of intraoperative enteroscopy. Several studies have reported that other methods of analysis, such as video capsule endoscopy and double balloon endoscopy, are also effective in determining the source of hemorrhage in the small intestine.<sup>7</sup> These methods were unable to be applied to the cases described here due to their lack of availability at our hospital.

In general, treatment is not administered to nonsymptomatic cases of jejunal diverticulosis that are incidentally diagnosed. In our second case, the segment of the jejunal diverticulosis was not resected. In contrast, jejunal diverticulosis with massive hemorrhage generally requires urgent surgical intervention, although the appropriate surgical procedure cannot generally be precisely specified. If the diverticulosis segment is not excessively long, the pathologic segment is resected and end-to-end anastomosis is performed. However, if the affected jejunal segment is relatively long, surgical removal of the symptomatic diverticular segment is most appropriate. In our first case, the entire segment of jejunal diverticulosis was resected and end-to-end anastomosis was performed.

The results obtained for surgical treatment of jejunal diverticulosis have generally been positive.<sup>3,8</sup> Nonetheless, challenges remain for its diagnosis and treatment, including difficulty in intraoperative diagnosis and lack of knowledge of the pathology of hemorrhage in the diverticular of the small intestine. Fortunately, diagnosis is generally possible by means of histopathologic examination, and two mechanisms have been proposed with regard to the etiology. One hypothesis is that the condition arises from ulceration of the mucosa in the diverticulum or the tearing of the blood vessels in response to irritation in the intestines due to the contents and/or

distention.<sup>2</sup> However, ulceration in the specimen has not been observed in several cases.<sup>8</sup> In our second case, a lesion with ulceration involving loss of epithelium on the base of the diverticulum was observed on pathological examination.

Although rare, jejunal diverticulosis must be considered as a cause of bleeding in patients experiencing GI hemorrhage when neither an upper nor lower GI source of bleeding can be determined on endoscopic examination.

## REFERENCES

1. Miller RE, McCabe RE, Salomon PF, Knox WG. Surgical complications of small bowel diverticula exclusive of Meckel's. *Ann Surg* 1970;171(2):202-10.
2. Baskin RH Jr, Mayo CW. Jejunal diverticulosis; a clinical study of 87 cases. *Surg Clin North Am* 1952;1185-96.
3. Longo WE, Vernava AM 3rd. Clinical implications of jejunoileal diverticular disease. *Dis Colon Rectum* 1992;35(4):381-8.
4. Kassahun WT, Fangmann J, Harms J, Bartels M, Hauss J. Complicated small-bowel diverticulosis: a case report and review of the literature. *World J Gastroenterol* 2007;13(15):2240-2.
5. Wilcox RD, Shatney CH. Surgical implications of jejunal diverticula. *South Med J* 1988; 81(11):1386-91.
6. Wilcox RD, Shatney CH. Massive rectal bleeding from jejunal diverticula. *Surg Gynecol Obstet* 1987;165(5):425-8.
7. Gerson LB, Van Dam J. Wireless capsule endoscopy and double-balloon enteroscopy for the diagnosis of obscure gastrointestinal bleeding. *Tech Vasc Interv Radiol* 2004;7(3):130-5.
8. Taylor MT. Massive hemorrhage from jejunal diverticulosis. *Am J Surg* 1969;118(1):117-20.