

## Vaginal Choriocarcinoma: A Rare Reason for Postpartum Haemorrhage

Hüseyin Çağlayan ÖZCAN,<sup>a</sup>  
 Mete Gürol UĞUR,<sup>a</sup>  
 Zehra BOZDAĞ,<sup>b</sup>  
 Seyhun SUCU,<sup>c</sup>  
 Aynur MUSTAFA,<sup>a</sup>  
 Özcan BALAT<sup>a</sup>

Departments of

<sup>a</sup>Obstetrics and Gynecology,

<sup>b</sup>Pathology,

Gaziantep University Faculty of Medicine,

<sup>c</sup>Clinic of Obstetrics and Gynecology,

Gaziantep Cengiz Gökçek Obstetrics and

Children's Hospital,

Gaziantep

Received: 24.04.2016

Accepted: 14.07.2016

Available online: 15.02.2018

Correspondence:

Aynur MUSTAFA

Gaziantep University Faculty of Medicine,

Department of Obstetrics and Gynecology,

Gaziantep, TURKEY

dr.aynur.moustafa@hotmail.com

This study was presented as a poster  
 presentation at 14<sup>th</sup> Turkish National  
 Gynecologic Oncology Congress,  
 November 2014, Antalya, Turkey.

**ABSTRACT** Choriocarcinoma, which occurs most commonly following term pregnancies, is a highly vascular tumor. The fragile and hypervascular structures of metastatic lesions pose a serious risk of massive hemorrhage. We present a 25-year-old patient, who was admitted due to profuse vaginal hemorrhage in the fourth postpartum month, and diagnosed with choriocarcinoma depending on clinical findings, high Beta-human chorionic gonadotropin levels and pathological result. In hemorrhages resistant to postnatal treatment, Beta-human chorionic gonadotropin levels should be examined, and the possibility of choriocarcinoma should always be kept in mind. Thus, we can prevent morbidity and mortality, which is related to surgical and medical interventions carried out in managing the resistant hemorrhages until the diagnosis is established.

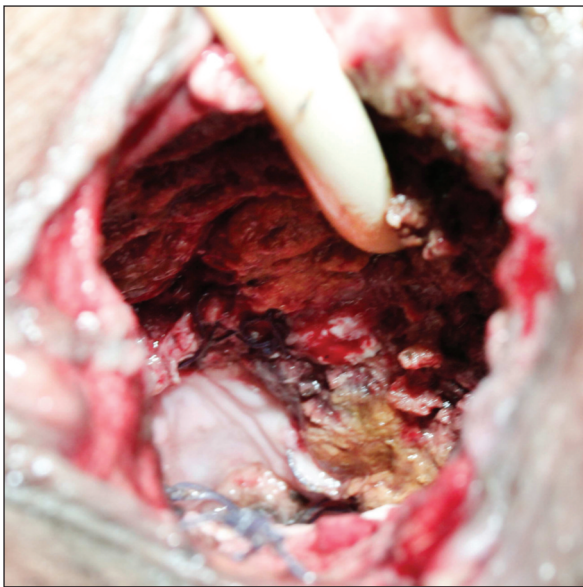
**Keywords:** Postpartum hemorrhage; choriocarcinoma

The lungs are the site in which choriocarcinoma most frequently causes metastasis. The second site in which metastasis is most often seen, with a rate of 30%, is the vagina.<sup>1,2</sup> Choriocarcinoma, approximately 50% of which occurs following term pregnancies and 25% of which occurs following molar pregnancies and the other 25% of which occurs following other gestational events, is a highly vascular tumor.<sup>2,3</sup> Metastatic choriocarcinoma can be diagnosed by anamnesis, clinical findings and high Beta-Human Chorionic Gonadotropin ( $\beta$ -HCG) levels.<sup>4</sup> Chemotherapy continues to be the main treatment for vaginal metastasis.<sup>5</sup> The fragile and hypervascular structures of metastatic lesions pose a serious risk of hemorrhage. A 25-year-old patient, who was admitted in the fourth postpartum month due to vaginal hemorrhage, and diagnosed with choriocarcinoma by biopsy as a result of an incidental finding of high  $\beta$ -HCG levels, was presented in this report.

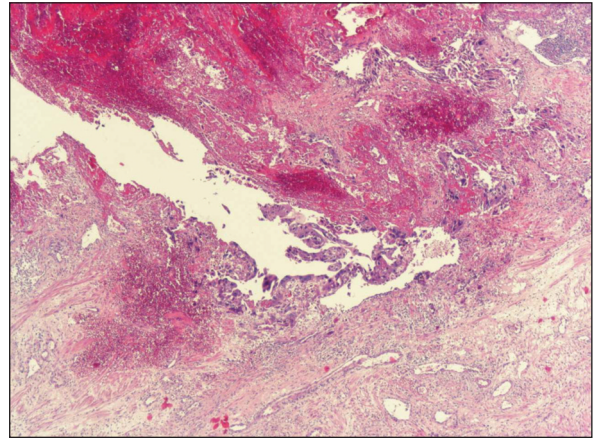
### CASE REPORT

A 25-year-old patient, who had vaginal hemorrhage in the fourth postpartum month, was admitted to our clinic during August 2014. The patient had previously undergone vaginal repair in another center, due to vaginal hemorrhage occurring twice before. It was observed that there were multiple lacerations on the front wall of the vagina and no hemorrhage coming from cervix (Figure 1), the endometrial cavity was found to be 7 mm; during transvaginal ultrasound scan (TVUS) and her urethra was found to be totally

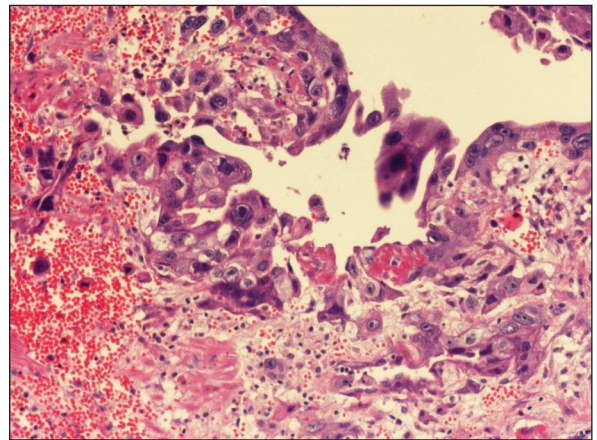
damaged. The blood values of the patient, were found to be hemoglobin: 8.5 g/dl, platelet: 21.000 / $\mu$ l, fibrinogen: 68 mg/dl, de-dimer: 1.16  $\mu$ g/ml, she was diagnosed with disseminated intravascular coagulation (DIC). The multiple lacerations were repaired by suturation and as a result of urological consultations an indwelling catheter was inserted for three months. Although DIC treatment and vaginal packing had been carried out, selective vaginal and cervical artery embolization were applied because of the continuation of haemorrhage. One month later, our patient was again admitted to our clinic because of vaginal haemorrhage. During the gynecological examination, fragile tissues were observed, while during TVUS and abdominopelvic MRI, no gestation focus was observed. Interestingly and incidentally an intern doctor ordered a  $\beta$ -HCG test and level was found to be 185.000 mIU/ml. Then the diagnosis of vaginal choriocarcinoma has emerged. Biopsies were obtained to support the diagnosis (Figures 2 and 3). The hemorrhage continued and bilateral hypogastric artery ligation was applied to the patient. Multiple hypermetabolic lesions were detected in the ischium bone and lungs on positron emission tomography (PET) and CT scans, and etoposide, methotrexate, actinomycin D, cyclophosphamide, vincristine (EMA/CO) combination chemotherapy



**FIGURE 1:** Image of fragile vaginal choriocarcinoma.



**FIGURE 2:** Microscopic image of choriocarcinoma developed from biphasic proliferation of trophoblastic cells. H&Ex 200.



**FIGURE 3:** Microscopic image of lesion, which consists of stromal haemorrhage and necrotic tissues , H&Ex40.

protocol was initiated. The serum  $\beta$ -HCG level was measured at 2850 mIU/ml following the first course of chemotherapy. Haemorrhage of the patient stopped five days after chemotherapy had been applied. The  $\beta$ -HCG level of the patient, who was given six courses of EMA/CO treatment and considered to be in complete remission, is currently at normal limits. The follow-up of the patient was uneventful.

## DISCUSSION

Vaginal metastasis in gestational trophoblastic neoplasia (GTN) is considered as a bad prognostic factor.<sup>6</sup> GTN, followed by a normal pregnancy, always results in choriocarcinoma. One out of 150,000 to 160,000 normal pregnancies is followed by chorio-

carcinoma, which is associated with an unfavorable outcome.<sup>2,3</sup> Metastatic choriocarcinoma can be diagnosed by anamnesis, clinical findings and high serum  $\beta$ -HCG levels.<sup>4</sup> Biopsy is not recommended and in studies carried out by Berkowitz et al. and Wong et al., biopsy is contraindicated in GTN patients with vaginal metastases.<sup>2,5</sup> But in our case we did not consider this diagnosis until the incidental HCG test. We did not hesitate to take a biopsy from the vaginal lesions to confirm the diagnosis and biopsies were performed easily without significant bleeding. It was found in studies carried out by Vardar et al. and Goldberg et al. that, vaginal metastases were considered to be a high-risk factor, and combination chemotherapy (EMA-CO) could be used as first-line treatment.<sup>6,7</sup> Due to ongoing vaginal haemorrhage, unnecessary surgical interventions are carried out along with the possibility of metastatic choriocarcinoma after normal pregnancy being left unnoticed, which constitutes the main problem with obstetric practice. Investigators have suggested various options, such as intravaginal packing, hemostatic deep figure-of-eight mattress suturing, or more extensive surgical interventions, such as hysterectomy, along with the ligation of feeding vessels.<sup>4,6</sup> The packing method, used for hemorrhages that occur as a result of large fragile metastatic vaginal lesions, usually fails.<sup>8</sup> The area starting from vaginal fornix to the vaginal outlet should be covered with gauze. When the gauze needs to be changed, it should be paid great attention not to touch the wound with bare fingers. Fingers should be put between the gauze and its package, and then its strip should be pulled to prevent the wound from bleeding or getting injured more. The gauze packing should be changed every 24 hours to prevent secondary infection. When severe bleeding cannot be stopped with vaginal packing, the internal iliac artery, internal pudendal artery, obturator foramen artery, and uterine artery can be embolized using a spring coil and gelatin sponge.<sup>4</sup> Conventional methods are not effective in controlling haemorrhage occurring in the metastases of fornices or suburethral region; therefore, internal iliac artery needs to be ligated or embolized.<sup>2,5</sup> Selective arterial embolization was reported in a study carried out by Shen et

al. to have been effective in successfully controlling intraperitoneal haemorrhage in four patients with trophoblastic tumors.<sup>9</sup> The selective arterial embolization operation, carried out on our patient with DIC caused by severe haemorrhage was effective for one month.

We should recognize that any woman in the postpartum period, who has widespread vascular lesions, metastases of unknown origin, or vaginal haemorrhage resistant to surgery, could have choriocarcinoma. The serum concentrations of  $\beta$ -HCG in such patients should be measured when there is suspicion. Even with a widely disseminated disease, cure rates in patients having undergone chemotherapy are high. The longer time between pregnancy and outset of treatment is, the more difficult it is to eliminate the disease.<sup>10</sup> We can deduce from our case that  $\beta$ -HCG levels in hemorrhages resistant to postnatal treatment should be examined, and the possibility of choriocarcinoma should always be kept in mind. Therefore, morbidity and mortality, which may occur depending on the surgical and medical interventions carried out in order to stop the resistant hemorrhages until the diagnosis is established, can be prevented.

#### **Source of Finance**

*During this study, no financial or spiritual support was received neither from any pharmaceutical company that has a direct connection with the research subject, nor from a company that provides or produces medical instruments and materials which may negatively affect the evaluation process of this study.*

#### **Conflict of Interest**

*No conflicts of interest between the authors and / or family members of the scientific and medical committee members or members of the potential conflicts of interest, counseling, expertise, working conditions, share holding and similar situations in any firm.*

#### **Authorship Contributions**

**Idea/Concept:** Hüseyin Çağlayan Özcan, Özcan Balat; **Design:** Zehra Bozdağ; **Control/Supervision:** Mete Gürol Uğur; **Data Collection and/or Processing:** Özcan Balat; **Analysis and/or Interpretation:** Seyhun Sucu; **Literature Review:** Aynur Mustafa; **Writing the Article:** Hüseyin Çağlayan Özcan; **Critical Review:** Mete Gürol Uğur; **References and Fundings:** Hüseyin Çağlayan Özcan; **Materials:** Zehra Bozdağ.

## REFERENCES

1. Ghaemmaghami F, Ashraf-Ganjooie T. Gestational trophoblastic neoplasia. *Asia Pac J Clin Oncol* 2006;(2):9-21.
2. Berkowitz RS, Goldstein DP. Gestational trophoblastic neoplasia. In: Berek JS, Hacker NF, eds. *Practical Gynecological Oncology*. 4th ed. Philadelphia: Lipincott Williams & Wilkins; 2005. p.603-25.
3. Soper JT, Mutch DG, Schink JC. Diagnosis and treatment of gestational trophoblastic disease: ACOG Practice Bulletin No. 53. *Gynecol Oncol* 2004;93(3):575-85.
4. Yingna S, Yang X, Xiuyu Y, Hongzhao S. Clinical characteristics and treatment of gestational trophoblastic tumor with vaginal metastasis. *Gynecol Oncol* 2002;84(3):416-9.
5. Wong LC, Ngan HY, Collins RJ, Ma HK. Vaginal metastases in gestational trophoblastic disease. *Asia Oceania J Obstet Gynaecol* 1990;16(2):123-6.
6. Goldberg GL, Yon DA, Bloch B, Levin W. Gestational trophoblastic disease: the significance of vaginal metastases. *Gynecol Oncol* 1986;24(2):155-61.
7. Vardar MA, Altıntaş A, Demir SC. Gestational trophoblastic disease: the significance of vaginal metastases. *Eur J Gynaecol Oncol* 2000;21(2):184-6.
8. Ghaemmaghami F, Behroozi S, Mousavi A, Ashrafgangooei T, Gilani MM, Behtash N, et al. Assessment of the response to chemotherapy in gestational trophoblastic neoplasia with vaginal metastases. *Arch Gynecol Obstet* 2008;278(4):315-8.
9. Shen K, Yang X, Song H, Liu W, Zhang C. Selective arterial embolization in the management of internal bleeding caused by trophoblastic diseases. *Chinese Med J* 1996;109(2):151-6.
10. Bower M, Brock C, Fisher RA, Newlands ES, Rusten GJ. Gestational choriocarcinoma. *Ann Oncol* 1995;6(5):503-8.