

A Rare Clinical Presentation of Behçet's Disease with Life-Threatening Extensive Multiple Thrombosis and Recurrent Cardiac Arrest

Naoto SHIMBORI,^a
 Mücteba Enes YAYLA,^b
 Adalet Elçin YILDIZ,^c
 Duygu KELEŞ KARAHACIOĞLU,^c
 Nurşen DÜZGÜN^d

Departments of

^aInternal Medicine,

^bRheumatology,

^cRadiology,

Ankara University Faculty of Medicine,

^dDepartment of Internal Medicine,

Division of Rheumatology,

Ankara University Faculty of Medicine,

Ankara

Received: 27.01.2018

Received in revised form: 23.02.2018

Accepted: 23.02.2018

Available online: 17.09.2018

Correspondence:

Nurşen DÜZGÜN

Ankara University Faculty of Medicine,

Department of Internal Medicine,

Division of Rheumatology,

Ankara, TURKEY

duzgun@medicine.ankara.edu.tr

ABSTRACT Behçet's disease (BD) is (also known as Behçet Syndrome) a chronic inflammatory disease with unknown etiology. Researchers continue to explore possible genetic, bacterial, viral and environmental causes of BD, is frequent among the Mediterranean, Middle East, and Far Eastern populations. Cardinal symptoms are composed of recurrent oral ulcer, genital ulcer, skin lesions and eye involvement. Musculoskeletal, neurological, gastrointestinal and vascular system can also be affected. Diagnosis of BD is made on the basis of the combination of clinical findings, and widely accepted criterion such as International Study Group (ISG) is used. However, some cases unfulfilled by the criteria are not uncommon in the endemic geographical regions like Turkey and 'Silk-road' countries. Here we report a case of 15-year old male who presented with life-threatening multiple thrombosis and who had no signs which met any of the criteria making its diagnosis challenging.

Keywords: Behçet's disease; deep vein thrombosis; dural sinus thrombosis; pulmonary vascular involvement; HLA-B51 positivity

Behçet's disease (BD) is a multisystemic inflammatory disorder classified among the vasculitides, which can affect all types and sizes of blood vessels. Vascular involvement may be seen in one-third of BD patients. Most vascular events consist of recurrent superficial or deep vein thrombosis. Arterial thrombosis is less frequent. Severe complications such as vascular and pulmonary involvement are mostly related to the male gender.^{1,2}The diagnosis is primarily based on clinical criteria because there is no specific diagnostic laboratory test. It may take several months or years for all the common symptoms of the disease to appear, often making it difficult to obtain a definitive diagnosis.

Herein, we describe a juvenil patient with BD who presented life-threatening vascular manifestations, and discuss during diagnostic evaluation of BD with only widespread vascular involvement and also anticoagulant therapy in BD.

CASE REPORT

Pre-admission to our clinic: In January 2013, a 15-year old male presented to a local hospital with his complain of gluteal pain with redness and swelling which started 4 days earlier on right side then included both sides.

Magnetic resonance imaging (MRI) of pelvis showed hyperintensities in gluteus maximus, internal obturator muscles, adductor muscles, vastus lateralis on T2 weighted (T2W) images. After contrast medium injection linear fascial contrast enhancement was obtained which is more intense in the abductor muscles. In addition, edematous signal changes inside subcutaneous fat tissues were seen bilaterally at the levels of the hips. Contrast enhancement was also seen in bilateral ilio-femoral veins. With a possible diagnosis of gluteal abscess or fasciitis, antibiotic treatment was empirically began in an orthopedic clinic.

Parenteral antibiotic treatment relieved the symptoms, but on the seventh day, the patient complained of left trunk pain and was slightly hypotensive (90/60mmHg). He was unconscious and cardio-pulmonary arrest occurred. The patient was intubated and resuscitated but cardiac arrest repeated four times within the same day. Pulmonary CT angiography revealed bilateral massive pulmonary emboli completely occluding the vessels. Echocardiogram showed severe pulmonary hypertension with grade III tricuspid insufficiency. Thrombolytic treatment with tPA and intravenous prednisolone 80 mg were administered. On the day 2 after arrests, the patient was conscious and extubated. Cefoperazon/sulbactam, meropenem, and low molecular weight heparin (LMWH) were given. On Doppler ultrasonography (US) acute thrombosis of both deep veins of the lower limbs extending to both iliac veins and lower end of IVC was obtained. Warfarin was added to LMWH. During follow-up, the patient's lip deviated to the left side and cranial MR revealed hemorrhage on right basal ganglion. Anticoagulant treatment was discontinued. Further investigation revealed positive family history of BD in his father and post-partum DVT in his mother. In February 2013, LMWH was restarted due to persistence of massive thrombosis. Autoimmune serology tests: in March 2013, ANA and ANCA were negative by immunofluorescence assay, anticardiolipin antibody (ACA)-IgG: 2.5 and ACA-IgM: 1.9 (normal value: <7 U/mL); anti-Beta 2 glycoprotein 1 (β 2 GP 1)-IgG: 3.6 and anti- β 2GP 1-IgM: 4.0 (normal

value <5 U/ml); anti-phosphatidylserine antibody IgG: 4.9 and anti-phosphatidylserine antibody IgM: 5.2 (normal value <10 U/ml) by ELISA and Lupus anticoagulant: negative. Homocysteine level was normal. Genetic mutations in prothrombin and MTHFR were heterozygous positive. Factor V Leiden mutation was normal. Pathergy test was negative. Prednisolone 60 mg/day and cyclophosphamide infusion (500 mg/m²) with two weeks interval for two times were given. Clinic findings improved and inflammatory markers decreased. Abdominal Doppler USG showed thin calibers in hepatic vein and inferior vena cava, and post thrombotic effect was suggested here. Control pulmonary CT angiography showed post thrombotic changes but no signs of aneurysm. Control Doppler USG showed persistent thrombosis in left external iliac vein and right popliteal vein. It was suggested that thrombosis was likely caused by inflammatory process rather than by hematologic pathologies. The patient with paternal history of BD did not have recurrent oral aphthous ulcer, genital ulcer, eye or skin lesions and pathergy positivity.

On admission to our clinic: In April 2013, the patient's general condition was stable. In physical examination, signs of venous stasis were present on both limbs. Laboratory tests were as follows, Hb: 12.7 g/L, Hct: 37.5%, MCV: 92.4, RBC: 4,000x10³/ μ L, WBC: 9,8x10³ / μ L Neutrophil: 64.2%, Lymphocyte: 27.5%, Monocyte: 7.4%, Eosinophil: 0.08%, Basophil: 0.0%, Thrombocyte: 215x10³/ μ L, ESR: 64 mm/h, CRP: 307.5 mg/dL. Biochemical tests were within normal limits. INR: 1.25, aPTT: 36, Urinalysis: normal, HLA-B51 was positive. Abdominal and lower extremities of CT angiography indicated extended acute thrombosis in lower segment of inferior vena cava (Figure 1), bilateral external iliac veins, bilateral deep and superficial femoral veins, popliteal veins and deep crural veins. All were indicating active thrombosis in extended areas. Control cranial MRI showed heterogenic intensity in hematoma on right basal ganglion indicating possibility of multiple bleeding, which suggested that thrombolytic agent induced bleeding was more likely. MRI venography

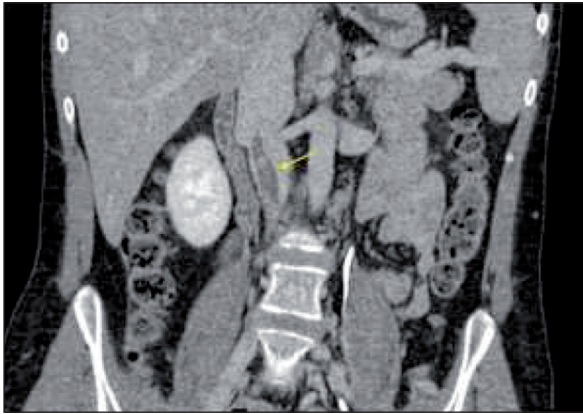


FIGURE 1: Coronal reformatted contrast enhanced CT image shows hypodense thrombus in inferior vena cava.

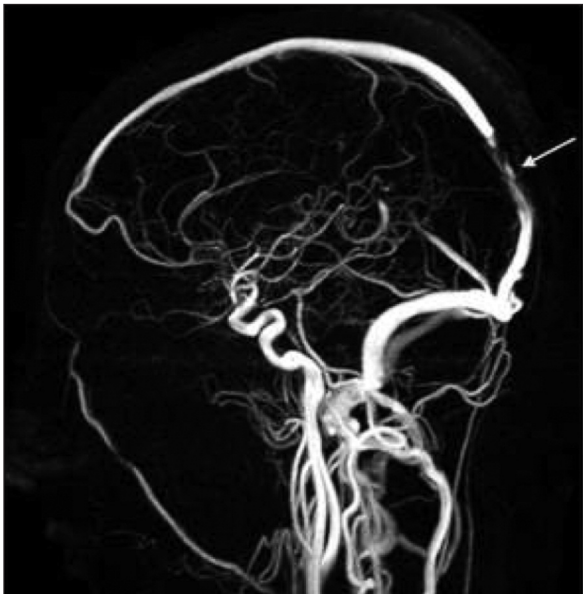

FIGURE 2: Posterolateral view of 3D reformatted MR venography image shows inconsistency of contrast intensity in posterior part of superior sagittal vein.

revealed the possibility of dural venous thrombosis (Figure 2).

Together with facts like male sex, positive familial history and diffuse thrombosis both in arteries and veins with no obvious etiology other than heterogenic mutation of prothrombin and MTHFR, vasculo-*Behçet* with atypical presentation was diagnosed. Cyclophosphamide (CYC) treatment was terminated considering his age and risk of infertility. Azathioprine (AZA) 2.5 mg/kg plus prednisolone 1 mg/kg were administered. In follow-up, levels of inflammatory markers decreased and the patient's clinic improved.

DISCUSSION

Diagnosis: According to the diagnostic criteria of International Study Group for *Behçet's* disease (ISG), in the presence of recurrent oral ulcers at least 3 times in a year, the minimum of 2 out of 4 following findings are necessary;³

Present genital ulcer or scar of previous episode, examined by dermatologist

Papulopustular lesion or erythema nodosum like lesion

Anterior uveitis, posterior uveitis, or vitreous on slit lamp examination or retinal vasculitis observed by ophthalmologist

Positive Pathergy test

Here in this case, any of criteria above was absent. Five features leading to the diagnosis of BD were as follows;

Diffuse systemic thrombosis both in arteries and veins. Other coagulopathy causes were excluded such as congenital coagulopathy, thrombophilic disorders (APS, protein C and S deficiencies, antithrombin III deficiency, homocysteinemia) immobility, malignancy, dehydration, and medication.

Positive familial history in his father

Positive HLA- B51 antigen

BD is endemic in the region

Vasculitis is the central mechanism in the pathology of BD. The pathogenetic mechanism of thrombus formation in BD is still unclear. It is attributed to vascular inflammation and endothelial ischemia. Involvement of both arteries and veins, all size of vessels are characteristic. Vascular involvement is more common and clinically more severe in male patients.^{1,2} Positive familial history has been linked to several aspects of the disease.⁴ Early onset of symptoms and higher severity are known. Asking familial history was the key in this case for direction of its treatment. Despite of the exclusion from major diagnostic criteria, HLA-B51 positivity is still an important finding for BD with clinical picture.⁵ In endemic region, severe and atypical presentations may be seen more commonly.

With its high specificity, ISG criterion is effective in the Western countries where BD is relatively rare. But in the endemic regions like Turkey and “Silk Road” countries, ISG’s claimed sensitivity of 91% might be much lower. Vascular involvement is the major cause for mortality and the second line after uveitis for morbidity. In BD endemic regions, a criterion with vascular component (eg. ICBD) seems more preferable because of higher incidence and more serious outcomes.⁶ Juvenil presentation of BD is reportedly similar to that of adult.^{7,8} But as this case may indicate, the possibility of undiagnosed cases in these patients with generalized thrombosis must be considered in endemic regions. The cause of his first presentation with gluteal inflammation remained unclear.

Anticoagulation: With hindsight, this case was just another example of possible hazardous situation caused by aggressive anticoagulation in vasculo-BD related thrombosis. Several studies showed different mechanism of thrombogenesis in BD where the inflammation of vessels are major factor rather than increased coagulability of the blood. Also, embolus formation in BD is unlikely because thrombus is strictly attached to inflamed vessel wall.⁹ Therefore main strategy is anti-inflammatory treatment rather than anticoagulation.¹⁰

Dural venous thrombosis itself can cause the hemorrhage and ischemia. However, the localization of venous hemorrhage in dural venous thrombosis is more characteristic in brain stem region. In this case, its location is less characteristic for the hemorrhage in dural venous thrombosis.

Treatment for dural venous thrombosis in BD is not clearly established. Effectiveness of anticoagulation is unclear. There’s also a study including venous involvement supporting the concomitant use of warfarin with immunosuppression.¹¹ Ahn et al. showed that there were no significant differences in the recurrence rate of thrombosis between immunosuppressive therapy and those combined with anticoagulants therapy.¹²

Anti-inflammation: Justice for the cessation of cyclophosphamide that had been started for 2 cycles could be discussed. With absence of active

aneurysm, systemic corticosteroid and AZA combination are proven to be effective. And moreover, the patient age of 15 and potential adverse effect like infertility of CYC were considered against its use.

The patient had massively diffuse thrombosis still active in peripheral veins. And in follow-up, during tapering down the dose of corticosteroid while taking 2.5mg/kg/day of AZA, the activation of disease was observed in the form of increased inflammatory markers.

Follow up: Our particular patient has been followed closely on recurrence of vasculitis/thrombosis and has remained in remission with low dose corticosteroid and AZA combination for 4 years.

CONCLUSION

Multiple thrombi without thrombophilic etiology should remind the possibility of vasculo-BD in the endemic area. Inclusion of vascular involvement in the diagnostic criteria might be beneficial. Anti-inflammatory and immunosuppressive treatment should be preferred as first line in thrombosis of BD. Anti-coagulation can cause harm, its indication still remains unclear. However, more clinical studies are needed for its use in BD. Features like familial history, vascular manifestations, HLA-B51 positivity, male sex can help the diagnosis of BD in some cases.

Source of Finance

During this study, no financial or spiritual support was received neither from any pharmaceutical company that has a direct connection with the research subject, nor from a company that provides or produces medical instruments and materials which may negatively affect the evaluation process of this study.

Conflict of Interest

No conflicts of interest between the authors and / or family members of the scientific and medical committee members or members of the potential conflicts of interest, counseling, expertise, working conditions, share holding and similar situations in any firm.

Authorship Contributions

All authors contributed equally while this study preparing.

REFERENCES

1. Yazici H, Fresko I, Yurdakul S. Behçet's syndrome: disease manifestations, management, and advances in treatment. *Nat Clin Pract Rheumatol* 2007;3(3):148-55.
2. Düzgün N, Ateş A, Aydintuğ OT, Demir Ö, Olmez U. Characteristics of vascular involvement in Behçet's disease. *Scand J Rheumatol* 2006;35(1):65-83.
3. International Study Group for Behçet's disease. Criteria for diagnosis of Behçet's disease. *Lancet* 1990; 335(8697):1078-80.
4. Koné-Paut I, Geisler I, Wechsler B, Ozen S, Ozdoğan H, Rozenbaum M, et al. Familial aggregation in Behçet's disease: high frequency in siblings and parents of pediatric probands. *J Pediatr* 1999;135(1):89-93.
5. Verity DH, Marr JE, Ohno S, Wallace GR, Stanford MR. Behçet's disease, the Silk Road and HLA-B51: historical and geographical perspectives. *Tissue Antigens* 1999;54(3):213-20.
6. Davatchi F, Assad-Khalil S, Calamia KT, Crook JE, Sadeghi-Abdollahi B, Schirmer M, et al. The International Criteria for Behçet's Disease (ICBD): a collaborative study of 27 countries on the sensitivity and specificity of the new criteria. *J Eur Acad Dermatol Venereol* 2014;28(3):338-47.
7. Kitaichi N, Ohno S. Behçet disease in children. *Int Ophthalmol Clin* 2008;48(3):87-91.
8. Kitaichi N, Miyazaki A, Stanford MR, Iwata D, Chams H, Ohno S. Low prevalence of juvenile-onset Behçet's disease with uveitis in East/South Asian people. *Br J Ophthalmol* 2009;93(11):1428-30.
9. Calamia KT, Schirmer M, Melikoglu M. Major vessel involvement in Behçet disease. *Curr Opin Rheumatol* 2005;17(1):1-8.
10. Leiba M, Seligsohn U, Sidi Y, Harats D, Sela BA, Griffin JH, et al. Thrombophilic factors are not the leading cause of thrombosis in Behçet's disease. *Ann Rheum Dis* 2004;63(11):1445-9.
11. Ferro JM, Canhão P. Cerebral venous sinus thrombosis: update on diagnosis and management. *Curr Cardiol Rep* 2014;16(9):523.
12. Ahn JK, Lee YS, Jeon CH, Koh EM, Cha HS. Treatment of venous thrombosis associated with Behçet's disease: immunosuppressive therapy alone versus immunosuppressive therapy plus anticoagulation. *Clin Rheumatol* 2008;27(2):201-5.