

Presented with Uncommon Complaints in a Case of Pediatric Ocular Myasthenia Gravis

Nadir Görülen Şikayetlerle Başvuran Pediatrik Oküler Miyastenia Gravis Olgusu

Uğur ACAR,^a
Fatma AKBAŞ KOCAOĞLU,^b
Özlem YALÇIN TÖK,^c
Firdevs ÖRNEK^b

^aDepartment of Ophthalmology,
Hacettepe University Faculty of Medicine,

^bClinic of Ophthalmology,
Ankara Training and Research Hospital,
Ankara

^cDepartment of Ophthalmology,
Süleyman Demirel University
Faculty of Medicine,
Isparta

Geliş Tarihi/Received: 05.08.2015
Kabul Tarihi/Accepted: 09.01.2016

Yazışma Adresi/Correspondence:
Uğur ACAR
Hacettepe University Faculty of Medicine,
Department of Ophthalmology, Ankara,
TURKEY/TÜRKİYE
druguracar@gmail.com

This study was presented as a poster
presentation at 42nd National Ophthalmology
Congress, 19-23 November 2008,
Antalya, Turkey.

ABSTRACT We aimed to report 5-years follow-up result of a case who admitted with complaints of enlargement and irritation of the left eye and she was diagnosed as ocular myasthenia gravis (OMG) in her follow-up. A 8-years-old girl patient who admitted to our clinic with the symptoms of enlargement and irritation in the left eye for 6 months. It has been learned that the symptoms were increasing especially towards the end of the day. On ophthalmological examination; there was ptosis in the right eye whereas eyelid retraction in the left eye, and moderate limitation at gaze up and gaze out in both eyes. Single fiber electromyography result was compatible with myasthenia gravis. The level of acetylcholine receptor antibody, and the findings of chest and orbital computerized tomography were normal. Oral pyridostigmine treatment was sufficient for improving the complaints of the patient.

Keywords: Blepharoptosis; eyelids; Myasthenia gravis; Pyridostigmine bromide

ÖZET Sol gözde büyüme ve oküler irritasyon şikayetleri ile başvuran ve takiplerde oküler miyastenia gravis (OMG) tanısı konulan olgunun 5 yıllık takip sonuçlarını sunmayı amaçladık. Sekiz yaşında kız hasta, sol gözünde 6 aydır var olan büyüme ve irritasyon şikayetleri ile kliniğimize başvurdu. Semptomlarının özellikle günün sonuna doğru arttığı öğrenildi. Hastanın oftalmik muayenesinde sağ gözünde pitozis, sol gözünde kapak retraksiyonu ve her iki gözde dışa ve yukarı bakışta orta derecede kısıtlılık mevcut idi. Tek lif elektromiyografi raporu miyastenia gravis ile uyumlu idi. Hastanın asetilkolin reseptör antikoru düzeyi, göğüs ve orbital bilgisayarlı tomografi bulguları normal idi. Oral piridostigmin tedavisi ile hastanın şikayetlerinde iyileşme gözlemlendi.

Anahtar Kelimeler: Blefaropitozis; göz kapakları; miyastenia gravis; piridostigmin bromid

Myasthenia Gravis (MG) is an autoimmune disorder characterized by worsening muscle weakness, pain and fatigability towards the end of the day.^{1,2} MG is the most common ones among the neuromuscular junction diseases caused by the presence of antibodies that are directed to the acetylcholine receptor (AChR) at the postsynaptic membrane.² It is named as Ocular MG (OMG) when the symptoms of MG are limited to the oculomotor muscles for at least two years without systemic involvement.^{1,3} Mullaney et al. indicated that 5 (36%) of 14 OMG patients, and Kupersmith et al. indicated that 94 (64%) of 147 MG patients who have presented with OMG developed generalization of disease within two years.^{4,5} However, Ortiz and Borchert suggested that only 3 (15%) of 21 chil-

dren who have presented with OMG progressed to generalization after 6-years mean follow-up period.⁶ It is known that generalization of symptoms are more common in adult OMG compared to pediatric OMG.^{4,7}

It is well-known that the most common ocular manifestations of MG are fluctuating eyelid ptosis, strabismus, extraocular muscle weakness and diplopia, respectively.²⁻¹⁰ The patients with generalised MG also complain of painless fatigability of the bulbar and limb musculature. However complaint of eyelid retraction as in our case, is an uncommon symptom.

We aimed to report 5-years follow-up result of an OMG case who presented with eyelid retraction and ocular irritation symptoms.

CASE REPORT

A healthy 8-year-old girl patient suffering from enlargement and ocular irritation symptoms such as burning, stinging, itching etc. in the left eye, especially towards the end of the day for 6 months. On detailed ophthalmological examination, visual acuity was 20/20 in each eye, anterior and posterior segments of the both eyes were normal, the intraocular pressures were 11 mmHg in the right eye and 12 mmHg in the left eye. Punctate fluorescein staining was observed at superior quadrant of the cornea in the left eye under the slit-lamp micro-

scope with cobalt blue light. There were 2 mm ptosis in the right eyelid and 2 mm retraction and 1 mm scleral show in the left eyelid and moderate limitation at upward and outward gaze in both eyes (Figure 1). It was observed that when the ptotic right eye was covered, contralateral retracted eyelid improved, and it turned out to be pseudo lid retraction (Figure 2). Direct and indirect light reflexes were normal, pupils were isochoric. Other physical examination was normal.

Values of cell blood count, biochemistry, thyroid stimulating hormone (TSH), T3, T4 and TSR receptor antibody were normal, thyroid ultrasonography (USG) was normal, while levels of anti-thyroid peroxidase (anti-TPO) and anti-thyroglobulin were 2-times higher of upper-normal limit. These condition was interpreted as thyroid dysfunction and it was recommended follow-up by department of pediatric endocrinology.

Since, her parents noticed the alteration of her eyelid position throughout the day, we performed single fiber electromyography (EMG), and it was reported as compatible with MG. AchR antibody level was 0.20 nmol/mL (normal range is 0.00-0.50 nmol/mL) and the findings of chest and orbital computerized tomography (CT) were normal. Depending on clinical and laboratory findings, 7 mg/kg pyridostigmine bromide which is an acetylcholinesterase (AChE) inhibitor, was administered in

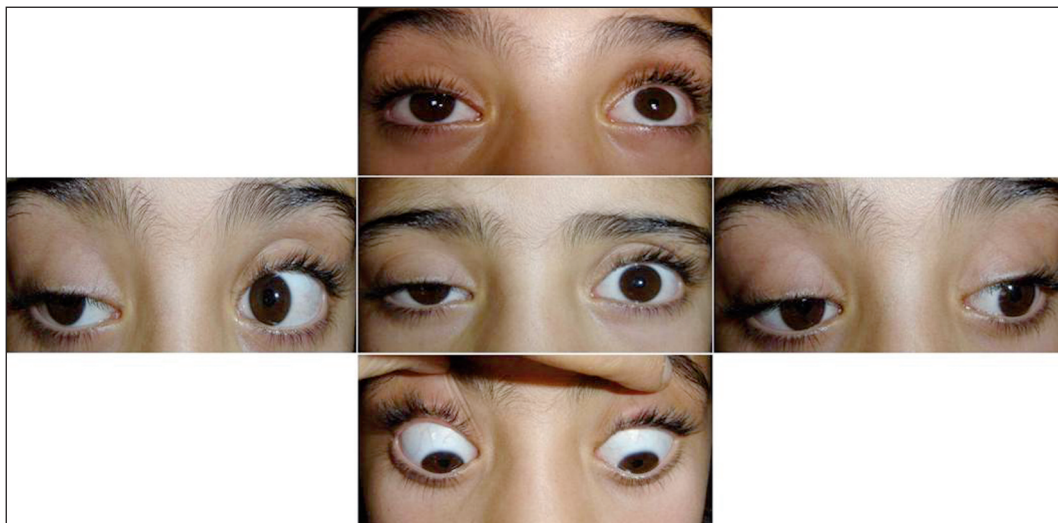

FIGURE 1: Images of the patient at initial examination.

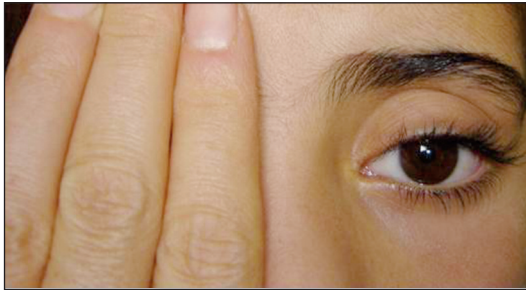

FIGURE 2: It is seen that when the ptotic eyelid was covered, contralateral retracted eyelid improved.

accordance with the recommendations of pediatric neurology department. Six months and two years after the treatment, gradual improvement was observed in the right eyelid ptosis and in the left eyelid retraction (Figure 3 A, B). The symptoms of patient resolved completely at the end of the fourth year of the treatment (Figure 3 C). Results of two-times repeated TSH, T3, T4, TSR receptor antibody tests, thyroid USG and AchR antibody test, were reported to be normal.

DISCUSSION

Puklin et al. categorized three different types of upper eyelid retraction in three patients with MG according to the duration of the retraction, in 1976.¹¹ The first type, fleeting eyelid retraction which is known as the 'lid twitch' or 'Cogan's sign' was described by Cogan.⁸ When the patient look primary gaze from downward gaze, an overshoot which occurs less than one second in the ptotic eyelid is observed. This fleeting is believed to be associated with easy fatigue and fast healing of levator palpebrae superioris muscle (LPSM).^{8,11} The second type, transient eyelid retraction which lasts many seconds, may depend posttetanic fascilitation of LPSM.¹¹ The third type, characterized long-standing eyelid retraction (months or years) as seen

in our patient. Due to Hering's law of equal innervation, weakness of the LPSM in the ptotic eyelid caused to increased innervation of both levators, thus resulting in pseudoretraction of the enhanced contralateral eyelid.^{3,11} Since this retraction type persists for a long time, ocular irritation symptoms may be seen because of exposure in the affected side, as in our case.³ For confirmation of this situation depend on MG, ophthalmologist should cover or elevate the ptotic eyelid manually (Figure 2). When the ptotic eyelid is covered, improvement of eyelid retraction is commonly considered specific for MG.^{3,11} For example, Graves Ophthalmopathy (GO) may imitate OMG, because it can cause limitations of extraocular muscles and eyelid retraction. Furthermore GO may coexistence with MG, because both of which are autoimmune disease. However ptosis is not observed in the patients with GO. Since, thyroid USG and thyroid function tests (T3, T4, TSH) of our patient were normal and extraocular muscles had normal caliber in orbital CT, diagnosis of GO was ruled out.

Most common ocular findings of MG are ptosis, strabismus and limitation of ductions. Limitation of abduction are seen more frequently than limitation of adduction.⁹ Ortiz and Borchert determined 95% ptosis, 81% limitation of ductions, and 76% strabismus and Cogan's lid twitch in 21 pediatric OMG patients.⁶ Pineles et al. found 100% ptosis, 56% strabismus and 51% ocular duction deficits in 39 childhood OMG patients.⁷ Similarly, Kim et al. indicated 96% ptosis, 88% strabismus in 24 childhood OMG patients.⁹ Ortiz and Borchert and Kim et al. suggested that the majority of strabismic cases had exotropia, and exotropia combined with vertical heterotropia respectively.^{6,9} Diplopia is seen frequently in the patients with late-onset MG, whereas it is quite rare in early-onset MG. In our

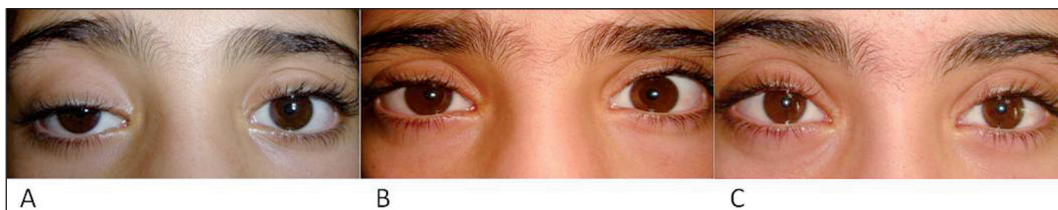


FIGURE 3: Image of the patient at A) 6-months, B) 2- years, and C) 4- years after oral pyridostigmine bromide treatment.

patient, moderate limitation at upward gaze and abduction in both eyes were present, strabismus and diplopia were not.

Exacerbation of symptoms such as muscle weakness, fatigue and ptosis towards at the end of the day, is usually diagnostic for MG. Some diagnostic tests such as edrophonium, ice pack, rest tests, serum AchR antibody measurement, electrodiagnostic evaluation (EMG) may be used in order to confirm the diagnosis.^{3,12} In OMG, serum AchR antibody are undetectable in 40 to 60% of the patients.^{1,3,11} After diagnosis of MG, physician should make additional tests such as thyroid function tests to detect coexistence of other autoimmune disorders and thorax CT to rule out thymoma. In our case, we confirmed the MG diagnosis with EMG test, despite the result of AchR antibody test was negative. In OMG, serum AchR antibody are undetectable in 40 to 60% of the patients.^{1,3,12} GO was ruled out with normal thyroid USG, normal orbital CT and normal thyroid function test values. There was no evidence of thymoma in the thorax CT.

The aim of the therapy is to resolve the symptoms of the patient. For the treatment of OMG, AchE inhibitors are commonly considered as the first-line option, and it is successful to alleviate the ptosis and visual deficit of OMG, but it may be insufficient for diplopia and ocular muscle limitations.^{3,12} At this stage immunosuppressive treatment modalities such as corticosteroids, methotrexate, azathioprine, cyclosporine, mycophenolate mofetil, tacrolimus, and/or intravenous immunoglobulin or plasmapheresis can be helpful. Thymectomy should be performed in the patients with a thymoma surely, however it is not recommended in seronegative MG and generally be avoided during childhood.^{3,12} In our case, pyridostigmine (7 mg/kg) treatment was sufficient in the amelioration of the patient's symptoms and findings.

A controversial issue is whether corticosteroid treatment for OMG may prevent the development of generalized MG. Although most of the retrospective studies have indicated that the reduced rates of generalization in patients with OMG who were administered early corticosteroid treatment, it has not been confirmed with a randomized prospective controlled study, yet.^{5,13,14}

MG is an autoimmune, multifactorial, clinically broad spectrum of disease which is seen more frequent in females and related to the neuromuscular junction. It is commonly easy to diagnose if suspected, however it is also easy to be misdiagnosed. Since, extraocular and orbicularis muscles usually affected, most of the patients are primarily referred to an ophthalmologist. Differential diagnosis of MG must be carried out and some diseases with similar symptoms such as GO, Horner's syndrome, third nerve palsy, chronic progressive external ophthalmoplegia and other neuromuscular junction disorders should be ruled out.³ After the correct diagnosis, management of MG must be performed with a multidisciplinary approach. Since, children may not complain of generalized MG symptoms, the ophthalmologist must also observe at each follow-up visit for the potential progression to generalized MG such as difficulty breathing, dysphagia, dysphonia and proximal limb weakness.

Conflict of Interest

Authors declared no conflict of interest or financial support.

Authorship Contributions

Idea/Concept: Uğur Acar, Fatma Akbaş Kocaoğlu, Özlem Yalçın Tök, Firdevs Örnek; **Design:** Uğur Acar, Fatma Akbaş Kocaoğlu.; **Control/Supervision:** Özlem Yalçın Tök, Firdevs Örnek; **Data Collection and/or Processing:** Uğur Acar, Fatma Akbaş Kocaoğlu; **Analysis and/or Interpretation:** Uğur Acar, Özlem Yalçın Tök, Firdevs Örnek; **Literature Review:** Uğur Acar; **Writing the Article:** Uğur Acar, Fatma Akbaş Kocaoğlu, Özlem Yalçın Tök, Firdevs Örnek.

REFERENCES

1. Le Panse R, Berrih-Aknin S. Autoimmune myasthenia gravis: autoantibody mechanisms and new developments on immune regulation. *Curr Opin Neurol* 2013;26(5):569-76.
2. Finnis MF, Jayawant S. Juvenile myasthenia gravis: a paediatric perspective. *Autoimmune Dis.* 2011;2011:404101.
3. Luchanok U, Kaminski HJ. Ocular myasthenia: diagnostic and treatment recommendations and the evidence base. *Curr Opin Neurol* 2008;21(1):8-15.
4. Mullaney P, Vajsar J, Smith R, Buncic JR. The natural history and ophthalmic involvement in childhood myasthenia gravis at the hospital for sick children. *Ophthalmology* 2000;107(3):504-10.
5. Kupersmith MJ, Latkany R, Homel P. Development of generalized disease at 2 years in patients with ocular myasthenia gravis. *Arch Neurol* 2003;60(2):243-8.
6. Ortiz S, Borchert M. Long-term outcomes of pediatric ocular myasthenia gravis. *Ophthalmology* 2008;115(7):1245-8.
7. Pineles SL, Avery RA, Moss HE, Finkel R, Blinman T, Kaiser L, et al. Visual and systemic outcomes in pediatric ocular myasthenia gravis. *Am J Ophthalmol* 2010;150(4):453-9.e3.
8. Cogan DG. Myasthenia gravis: a review of the disease and a description of lid twitch as a characteristic sign. *Arch Ophthalmol* 1965;74:217-21.
9. Kim JH, Hwang JM, Hwang YS, Kim KJ, Chae J. Childhood ocular myasthenia gravis. *Ophthalmology* 2003;110(7):1458-62.
10. Nair AG, Patil-Chhablani P, Venkatramani DV, Gandhi RA. Ocular myasthenia gravis: a review. *Indian J Ophthalmol* 2014;62(10):985-91.
11. Puklin JE, Sacks JG, Boshes B. Transient eyelid retraction in myasthenia gravis. *J Neurol Neurosurg Psychiatry* 1976;39(1):44-7.
12. Parr JR, Jayawant S. Childhood myasthenia: clinical subtypes and practical management. *Dev Med Child Neurol* 2007;49(8):629-35.
13. Zach H, Cetin H, Hilger E, Paul A, Wuschitz B, Jung R, et al. The effect of early prednisolone treatment on the generalization rate in ocular myasthenia gravis. *Eur J Neurol* 2013;20(4):708-13.
14. Benatar M, Kaminski HJ; Quality Standards Subcommittee of the American Academy of Neurology. Evidence report: the medical treatment of ocular myasthenia (an evidence-based review): report of the Quality Standards Subcommittee of the American Academy of Neurology. *Neurology* 2007;68(24):2144-9.