

# Iliac Lymph Node Resection with Modified J Shaped Incision for Improved Exposure in Iliac Metastases: Case Report

## İliak Metastazlarda Ekspozuru Artırmak İçin Modifiye J Şekinde İnsizyonla İliak Lenf Nodu Diseksiyonu

Saime İRKÖREN,<sup>a</sup>  
Heval Selman ÖZKAN,<sup>a</sup>  
Hüray KARACA,<sup>a</sup>  
Pars TUNÇYÜREK,<sup>b</sup>  
Nazan SİVRİOĞLU<sup>a</sup>

Departments of  
<sup>a</sup>Plastic and Reconstructive Surgery,  
<sup>b</sup>General Surgery,  
Adnan Menderes University  
Faculty of Medicine, Aydın

Geliş Tarihi/Received: 04.09.2013  
Kabul Tarihi/Accepted: 14.04.2014

Yazışma Adresi/Correspondence:  
Saime İRKÖREN  
Adnan Menderes University  
Faculty of Medicine,  
Department of Plastic and  
Reconstructive Surgery, Aydın,  
TÜRKİYE/TURKEY  
saimeirkoren@hotmail.com

**ABSTRACT** Fatty abdomen or inguinal hernia is typical situations where every effort for perfect exposure of iliac lymph nodes may be difficult. We present a modification that improves the exposure of the iliac nodes whilst reducing nerve, artery and peritoneal damaging. The longitudinal portion of the incision runs from the umbilical line downward, and curves gently at anterior superior iliac spine. The transverse component extends medially, approximately 1 cm above the inguinal ligament and ends at the junction of the lateral two-third and medial one-thirds of the inguinal ligament. When required, the incision combined with the femoral incision and a cephalic cut is made for additional exposure. We present our experience in two patients who had iliac lymph node metastasis. We find the incision useful and versatile that provides excellent exposure of the iliac region with protection of the iliac vessels.

**Key Words:** Melanoma; lymph node excision; wound closure techniques

**ÖZET** Yağlı karın veya kasık fıtığı mevcut bazı hastalarda iliak lenf nodlarına ulaşmak zor olabilir. Biz iliak lenf nodu diseksiyonu planlanan 2 hastada sinir, arter ve periton hasarını azaltmak ve cerrahi alan hakimiyetini artırmak için yeni bir modifiye insizyon kullandık. Bu insizyon umblikus hizasından anterior süperior iliak spine vertikal olarak uzanırken insizyonun transvers parçası ise inguinal ligamanın yaklaşık 1 cm üzerinden mediale doğru uzanarak inguinal ligamanın 1/3 medialinde sonlanır. Gerektiğinde insizyon femoral bölgeye doğru uzatılarak kasık diseksiyonu insizyonu ile birleştirilebilir. Bu çalışmada iliak metastazı mevcut 2 hastadaki deneyimlerimizi sunduk ve bu insizyonun iliak damarlara zarar vermeden yeterli cerrahi alan hakimiyeti sağladığımızı gösterdik.

**Anahtar Kelimeler:** Melanom; lenf düğümü çıkartma; yara kapatma teknikleri

**Türkiye Klinikleri J Case Rep 2015;23(2):186-9**

The ideal incision for ilioinguinal dissection permits maximum exposure of the operative field, provides viability of the skin flaps with protection of the major vessels and an acceptable cosmetic result.<sup>1-6</sup> Classical vertical and oblique incisions generally don't provide adequate exposure and have an increase risk of vessel and nerve injury.<sup>1-6</sup> Therefore, we have used the modified hockey stick incision in iliac melanoma metastasis patients to maximize surgical exposure and decrease morbidity and would commend on this technique.

doi: 10.5336/caserep.2013-37516

Copyright © 2015 by Türkiye Klinikleri

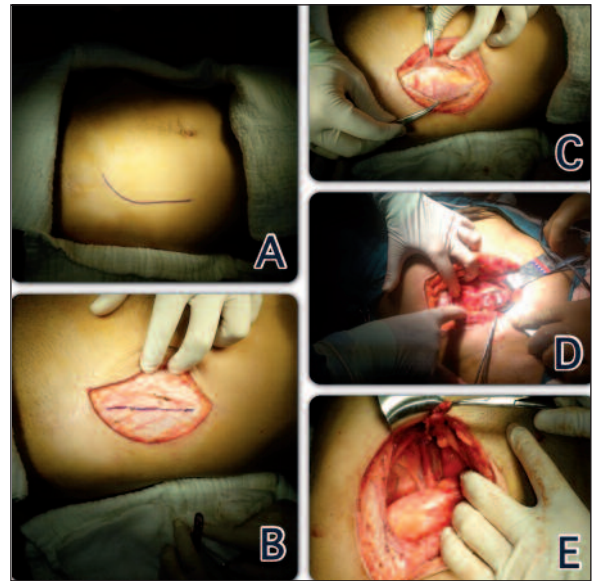
## CASE REPORT

Two patients who underwent superficial groin dissection (SGD) with radiologically detectable metastases of the iliac fossa were presented in this retrospective study. Patients had malign melanoma of the lower extremities. Both patients were males, and ages were 55 and 65 years. Breslow scores were 2,5 and 1,5 mm. Lymph node's dissections were performed as SGD in the first operation? In postoperative follow up PET scans within six months after the first operation metastatic iliac lymph nodes were identified, therefore, deep groin and iliac dissection had been planned. Patients signed written informed consent form and underwent the operation within one week after detection of iliac metastasis.

## SURGICAL TECHNIQUE

Incision planning starts with marking of anterior superior iliac spine (ASIS), transverse umbilical line, and inguinal ligament. The longitudinal portion of the incision starts from the crossing point of straight lines connecting umbilicus and ASIS, continues downward, and curves gently at ASIS. The transverse component extends medially, approximately 1 cm above the inguinal ligament and ends the junction of the lateral two-third and medial one-thirds of the inguinal ligament. At the level of the inguinal ligament, the incision is continued in oblique fashion parallel to the inguinal ligament (Figure 1A). Different from the standard hockey stick incision which starts at the subcostal margin, runs medially and finishes at pubic tubercle as previously described for retroperitoneal operations, our incision starts from the level with the umbilicus, runs more laterally and finishes at lateral portion of inguinal ligament. After the markings, the incision was started inferiorly from the inguinal ligament, and the deep groin nodes were dissected. Then the upper part was incised, lateral border of the external oblique muscle is identified, and the external iliac and para iliac nodes were dissected (Figure 1B,C,D,E).

Hospitalization period was two and three days. All pathology specimens revealed malignant



**FIGURE 1:** Intraoperative views (A); Skin marking (B); incision of the external oblique fascia (C); exposure of the external oblique muscle (D); visualization of the para iliac region and metastatic lymph node (E); After the complete dissection of the para iliac area.

melanoma metastasis, total numbers of excised nodes were 14 and 19. Post operative radiotherapy was given to patients. There was no inguinal relapse, inguinal and abdominal hernia in six mounts follows up.

## DISCUSSION

Block dissection of the inguinal lymph nodes is the routine management for palpable metastatic melanoma confined to this node basin. Involvement of the next tier external iliac and obturator lymph nodes within the pelvis is common, and untreated pelvic nodal disease can become advanced before becoming clinically apparent. Management of patients with clinically detectable lymph node metastasis to the groin is by ilia-inguinal or combined superficial and deep groin dissection (CGD) according to most literature.<sup>1,3-9</sup> There are classical, incision procedures in ilioinguinal lymph node dissection as vertical incision and oblique incision. When CGD was performed, an additional incision was made approximately 3-5 cm above the line of the inguinal ligament. CGD included dissection of the inguinofemoral and external iliac nodes up to the common iliac artery (if necessary up to the aor-

tic bifurcation) and dissection of the obturator nodes). Ilioinguinal lymph node dissections (LND) were carried out as a standard technique in two stages via the same long lazy-S incision. The contents of the femoral triangle were block dissected, denuding the anterior surface of the femoral vessels and clearing the femoral canal. The pelvis was accessed by a muscle splitting, preperitoneal approach in the iliac fossa preserving the inguinal ligament. The iliac vessels and pelvic sidewall (obturator fossa) were skeletonized, thereby removing all pelvic nodal tissue. Drains were sited in the pelvis and groin; the abdominal wall repaired in two layers of non absorbable suture, and skin closed in a standard fashion. Laparoscopic iliac node dissection may be a valuable management option because it allows performance of the same procedure as in open surgery but with significant benefits such as decreased operative morbidity due to reduced surgical trauma, less violation of the abdominal muscles or the inguinal ligament, reduced postoperative pain, and increased patient satisfaction with the cosmetic appearance.<sup>1,3,9</sup> Lawton et al. advocated fascia-preserving ilioinguinal LND as another modification.<sup>5</sup> Besides that, video-assisted endoscopic inguinal LND is currently investigated as a minimally invasive and less morbid approach.<sup>2</sup> However, laparoscopic dissection techniques are not easy to master and have a steep learning curve.<sup>7,8</sup>

A “J”-shaped incision known as the “hockey stick” has become increasingly popular for kidney transplantation in recent years.<sup>4</sup> This pararectus incision is prolonged medially to the midline above the pubic symphysis. The ipsilateral rectus muscle is usually divided, and the incision can be extended upward to the subcostal margin. These incisions are easy to perform and allow satisfactory extraperi-

toneal exposure of the iliac vessels and the bladder for the kidney transplantation. The hockey-stick approach was advocated for renal transplantation in children because it yields excellent access to the common iliac vessels and inferior vena cava, in case of intraperitoneal transplantation and in other surgical options.<sup>4</sup>

To our knowledge, there is no study in the literature using hockey-stick incisions for iliac dissection in metastatic disease. The modified hockey stick incision affords excellent exposure of the iliac fossa to permit en bloc resection of all levels. It is a versatile incision, which can be combined with classic Lazy S incision for SGD when required for complete oncological clearance. The flap raised is similar to that described by Starzl et al. used for renal transplantation.<sup>6</sup> However, has some modifications as starting from the level with the umbilicus, running more laterally and finishing at lateral part of the inguinal. In conclusion, by performing the incision more laterally, the rectus muscle is not divided, and this provides lower possibility of abdominal weakness, thus decrease incidence of possible abdominal and inguinal hernia. Another advantage of this technique is a lower risk of injuring iliac vessels and obturator nerve because it is possible to reach the retroperitoneal space far from these neurovascular structures. Its drawbacks are definite risk of enlargement and weakening of the scar, due to its direction against the Langer skin lines.

In conclusion, we recommend modified hockey stick incision to be considered for ilioinguinal LND. Although, multicenter, randomized prospective trials with a standardized definition of complications are required.

## REFERENCES

1. Karakousis CP, Driscoll DL. Groin dissection in malignant melanoma. *Br J Surg* 1994; 81(12): 1771-4.
2. Schneider C, Brodersen JP, Scheuerlein H, Tamme C, Lippert H, Köckerling F. Combined endoscopic and open inguinal dissection for malignant melanoma. *Langenbecks Arch Surg* 2003; 388(1):42-7.
3. Allan CP, Hayes AJ, Thomas JM. Ilioinguinal lymph node dissection for palpable metastatic melanoma to the groin. *ANZ J Surg* 2008; 78(11):982-6.
4. Nanni G, Tondolo V, Citterio F, Romagnoli J, Borgetti M, Boldrini G, et al. Comparison of oblique versus hockey-stick surgical incision for kidney transplantation. *Transplant Proc* 2005;37(6): 2479-81.
5. Lawton G, Rasque H, Ariyan S. Preservation of muscle fascia to decrease lymphedema after complete axillary and ilioinguinofemoral lymphadenectomy for melanoma. *J Am Coll Surg* 2002;195(3):339-51.
6. Starzl TE, Marchioro TL, Morgan WW, Waddell WR. A technique for use of adult renal homografts in childrens. *Surg Gynecol Obstet* 1964;119:106-8.
7. Alvarez-Maestro M, Rios Gonzalez E, Martinez-Piñero L, Sanchez Gomez FJ. Modified endoscopic left inguinal lymphadenectomy. *Actas Urol Esp* 2013;37(10):663-6.
8. Ichimiya M, Goishi K, Muto M. Endoscopic groin lymph node dissection as a preferable technique for malignant skin neoplasms. *J Plast Surg Hand Surg* 2013;47(4):248-51.
9. Pohar KS. The anatomic extent and completeness of pelvic lymphadenectomy is what matters. *Curr Opin Urol* 2013;23(5):444-8.