

Primary Coronary Angioplasty with Stenting for Acute Myocardial Infarction in a Patient with Congenital Coronary Artery Anomaly: Case Report

Akut Miyokard İnfarktüsü Geçiren Konjenital Koroner Arter Anomalisi Olan Bir Hastada Primer Koroner Anjiyoplasti ve Stent

Önder ÖZTÜRK,^a
Ünal ÖZTÜRK^b

^aDepartment of Cardiology,
Diyarbakır Training and
Research Hospital, Diyarbakır
^bMinistry of Health,
Provincial Directorate of Health, Mardin

Geliş Tarihi/Received: 28.12.2010
Kabul Tarihi/Accepted: 02.03.2011

Yazışma Adresi/Correspondence:
Önder ÖZTÜRK
Diyarbakır Training and
Research Hospital,
Department of Cardiology, Diyarbakır,
TÜRKİYE/TURKEY
droozturk21@hotmail.com

ABSTRACT Coronary artery anomalies have been identified in 0.6% to 1.5% of coronary angiograms. The anomalous origin of the left coronary artery from the right sinus of valsalva is a relatively rare anatomical variation. Difficulties may occur in the diagnostic procedure, but recognition and adequate visualization of the anomaly is essential for proper patient management, especially in patients undergoing evaluation for percutaneous coronary intervention, coronary artery surgery or prosthetic valve replacement. In the present report, we describe a patient who had undergone primary PCI for a LAD lesion in acute lateral myocardial infarction, in whom primary PCI of the anomalous origin of the LAD arising from the right sinus of valsalva was previously undetected.

Key Words: Angina, unstable; coronary vessel anomalies; angioplasty, transluminal, percutaneous coronary

ÖZET Koroner arter anomalileri, koroner anjiyogramların %0,6 ile %1,5'inde saptanmaktadır. Sağ sinus valsalvadan çıkan sol koroner arter anomalisi, son derece nadir bir anatomik farklılıktır. Tanı esnasında güçlükler olabilir. Ancak koroner arter anomalisinin tanımlanması ve tam olarak gösterilmesi özellikle perkutan koroner girişim, koroner arter cerrahisi veya prostetik kapak replasmanı gereken hastalarda önemlidir. Bu yazıda, akut lateral miyokard infarktüsünde daha önceden saptanmamış sağ sinus valsalvadan çıkan anormal orjinli LAD'nin lezyonu için primer perkutan koroner girişim yapılan bir hastayı tanımladık.

Anahtar Kelimeler: Anjina, kararsız; koroner damar anomalileri; anjiyoplasti, translüminal, perkutan koroner

Türkiye Klinikleri J Cardiovasc Sci 2012;24(3):349-52

Coronary artery anomalies have been identified in 0.6% to 1.5% of coronary angiograms.^{1,2} The anomalous origin of the left coronary artery from the right sinus of valsalva is a relatively rare anatomical variation. Difficulties may occur in the diagnostic procedure, but recognition and adequate visualization of the anomaly is essential for proper patient management, especially in patients undergoing evaluation for percutaneous coronary intervention, coronary artery surgery or prosthetic valve replacement.^{3,4}

In the present report, we describe a patient who had undergone primary PCI for a left anterior descending (LAD) lesion in acute lateral myocardial infarction (MI), in whom primary PCI of the anomalous origin

of the LAD arising from the right sinus of valsalva was previously undetected.

CASE REPORT

A 62-year-old female patient experienced anterior chest oppression while resting for about 2 hours, with no history of previous episodes. She was transported to hospital with persistent chest pain. She had several risk factors including hypertension, diabetes mellitus and dyslipidemia. On admission she was diaphoretic and restless. Her pulse was regular at 85 beats/min and blood pressure 140/90 mmHg. Physical examination showed no remarkable findings. Electrocardiography showed Q waves and ST elevation in leads I and aVL and ST depression in derivations of II, III and aVF (Figure 1). Cardiac biomarkers on admission; CK: 84 U/L, CKMB: 23 IU/L, troponin I: <0.01 µg/L. Cardiac biomarkers after 6 hours on admission; CK: 483 U/L, CKMB: 78 IU/L, troponin I: 2.7 µg/L. Cardiac biomarkers after 2 days on admission CK: 843 U/L, CKMB: 63 IU/L, troponin I: 10/82 µg/L. Echocardiography showed that left ventricular hypertrophy, left ventricular diastolic dysfunction, lateral mid and apical wall hypokinetic. The estimated ejection fraction was 50%. Informed consent was obtained from the patient.

A coronary angiography of the left system was unable to be visualized in the standard angiography views. Afterwards, the right coronary angiogram was performed and it was shown that the right coronary artery (RCA) had got plaque (Figure 2). After locating the ostium of the RCA, left coronary artery arising independently from the right sinus of Valsalva was selectively catheterized by directing the catheter tip more posteriorly and at times more inferiorly. Left coronary angiogram revealed that the LAD was totally occluded at the proximal level before first diagonale branch. Cx artery had got plaque. There was severe stenosis (99%) at the proximal artery of the intermedier. Intermedier artery was very thin (Figure 3). Thus, the patient had undergone primary PCI to the LAD lesion. A metal stent was implanted in the stenotic segment of the LAD artery (Figure 4a,b). The patient was discharged on the fourth day of stent implantation without any complications.

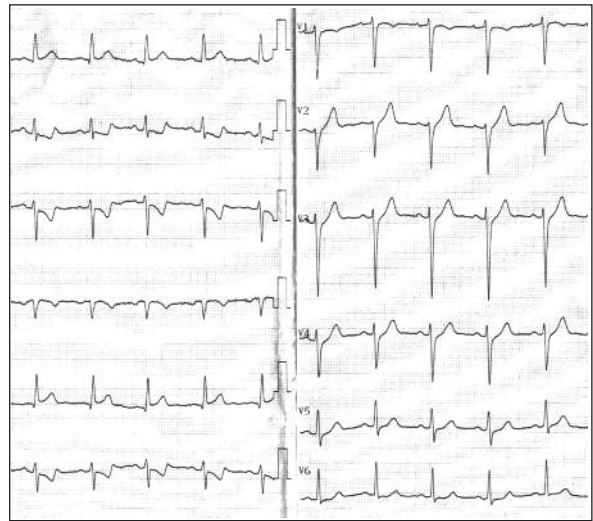


FIGURE 1: Electrocardiography on admission shows Q waves and 1-to 2-mm elevations of the ST segment in I, aVL and 2-to 3- mm depression of the ST segment II, III and aVF.

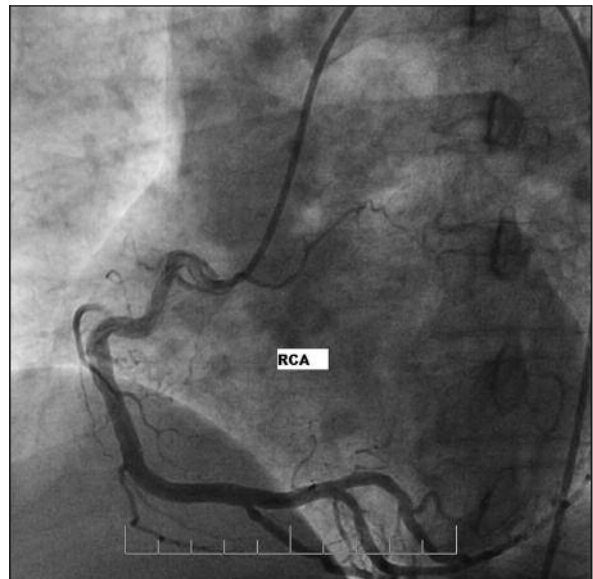

FIGURE 2: Right coronary angiogram revealed no significant narrowing of RCA which was originated from the right sinus of valsalva.
RCA: Right coronary artery.

DISCUSSION

Coronary artery anomalies are not seen frequently during routine cardiac catheterization and the incidence of anomalous coronary artery is reported to range from 0.2% to 1% in patients undergoing CAG and 0.3% in autopsies.^{5,6} Anomalous origin of the LMCA from the RSV is extremely rare and reported to constitute 0.017% coronary arteriogra-

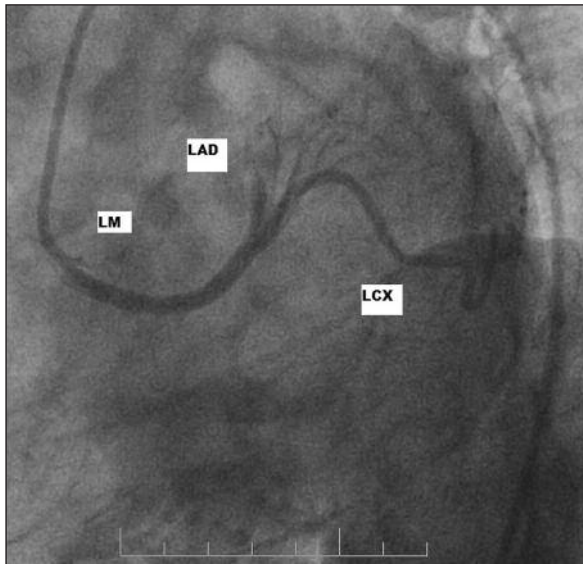


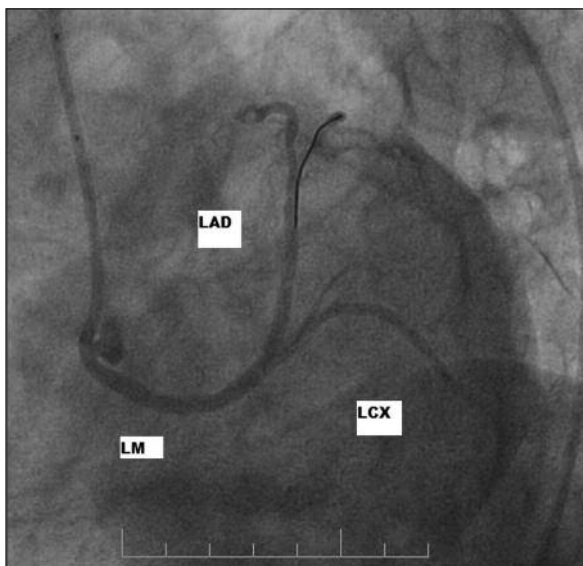
FIGURE 3: Pre-intervention image: An anomalous left coronary artery arising independently from the right sinus of valsalva is seen by coronary arteriography. Left coronary angiogram shows totally occluded proximal LAD. LM: Left main, LAD: Left anterior descending, LCX: Left circumflex.

phy examinations.⁷ However, Taylor et al. reported the incidence of sudden cardiac death to be 57% among 49 cases of anomalous left coronary artery in an autopsy study.⁸

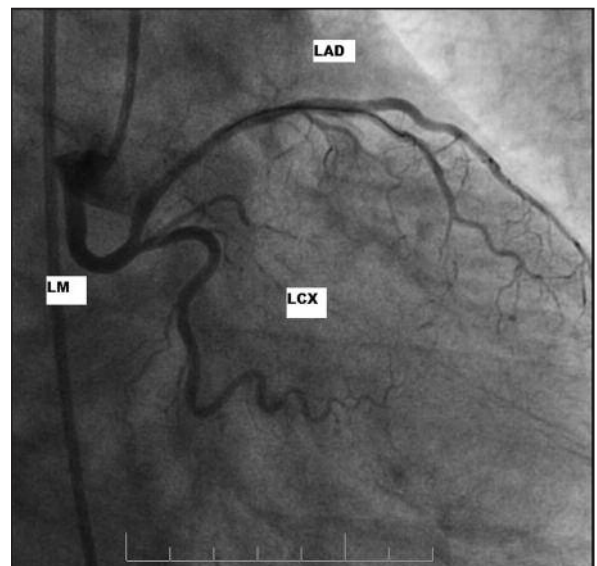
It is very important to identify the culprit vessel as soon as possible in an acute myocardial infarction. Recognition and angiographic demon-

stration of the anomalous artery assumes high priority. The clinical significance of the anomaly is obvious in patients undergoing PCI or cardiac surgery. However, in a patient with a coronary artery with an anomalous origin, it is difficult to quickly and precisely cannulate all three coronary arteries and to determine the subsequent treatment strategy. The selective cannulation of anomalous arteries can be a formidable challenge due to the unusual ostial location, take-off orientation and aberrant course of the artery.³

The first case series of PCI performed on such aberrant vessels was described in 1982.⁹ A failure to recognize and properly demonstrate the anomaly can be hazardous to patient management. On the other hand, coronary anomalies are quite unusual to find during routine coronary angiography. Two angiographic signs have been previously described and have proven to be reliable in recognizing the anomalous artery before its selective demonstration.¹⁰ One sign is a profile view of the artery behind the aortic root during left ventriculography (the 'aortic root sign'), and the other sign is a recognition of absent arterial inflow to a significant area of the posterior lateral left ventricle during selective injections of the main left coronary artery (the 'sign of nonperfused myocardium').¹¹



a



b

FIGURE 4: Post intervention image: Stents were successfully deployed in the proximal LAD, and the final angiogram showed an optimal result. LM: Left main, LAD: Left anterior descending, LCX: Left circumflex.

We have described a patient with the anomalous origin of the LAD arising from the right sinus of valsalva who had underwent succesful primary coronary intervention for acute myocardial infarction. Coronary angioplasty with stenting may be a feasible therapeutic option for a congenital anomalous of coronary artery.

Although this topic is still open in cardiology, the left coronary artery originating from the right coronary sinus is a rare common anomaly, and its

prognosis and treatment are less known than for other coronary anomalies.

We have described a cases with a congenital coronary artery anomaly who underwent succesful primary coronary intervention for acute myocardial infarction. Coronary angioplasty with stenting may be a feasible therapeutic option for a anomalous coronary artery. However, the operator should be aware of the potential risk of complications and the limitations of the procedure.

REFERENCES

1. Yamanaka O, Hobbs RE. Coronary artery anomalies in 126,595 patients undergoing coronary arteriography. *Cathet Cardiovasc Diagn* 1990;21(1):28-40.
2. Wilkins CE, Betancourt B, Mathur VS, Massumi A, De Castro CM, Garcia E, et al. Coronary artery anomalies: a review of more than 10,000 patients from the Clayton Cardiovascular Laboratories. *Tex Heart Inst J* 1988;15(3):166-73.
3. Hendiri T, Alibegovic J, Bonvini RF, Camenzind E. Successful angioplasty of an occluded aberrant coronary artery: a rare cause of acute myocardial infarction. *Acute Card Care* 2006;8(2):125-7.
4. Balkanay M, Eren E, Toker ME, Polat A, Keleş C, Güler M, et al. [Surgical treatment of tetralogy of Fallot with abnormal course of the coronary artery]. *Turkish J Thorac Cardiovasc Surg* 2010;18(4):330-3.
5. Akcay A, Tuncer C, Batyraliev T, Gokce M, Eryonucu B, Koroglu S, et al. Isolated single coronary artery: a series of 10 cases. *Circ J* 2008;72(8):1254-8.
6. Çilingiroğlu S. [Evaluation of coronary artery anomalies with angiography in Turkish adult population]. *Türkiye Klinikleri J Cardiovasc Sci* 2009;21(3):363-9.
7. Okamoto R, Saito K, Miyahara M, Okamoto S, Makino K, Hirano R, et al. Acute myocardial infarction in a patient with anomalous left coronary artery origin and primary antiphospholipid syndrome. *Jpn Circ J* 2000;64(3):214-7.
8. Taylor AJ, Byers JP, Cheitlin MD, Virmani R. Anomalous right or left coronary artery from the contralateral coronary sinus: "high-risk" abnormalities in the initial coronary artery course and heterogeneous clinical outcomes. *Am Heart J* 1997;133(4):428-35.
9. Schwartz L, Aldridge HE, Szarga C, Cseplo RM. Percutaneous transluminal angioplasty of an anomalous left circumflex coronary artery arising from the right sinus of Valsalva. *Cathet Cardiovasc Diagn* 1982;8(6):623-7.
10. Page HL Jr, Engel HJ, Campbell WB, Thomas CS Jr. Anomalous origin of the left circumflex coronary artery. Recognition, antiographic demonstration and clinical significance. *Circulation* 1974;50(4):768-73.
11. Dursunoğlu D, Ozalp G, Taşköylü O, Semiz E. Anomalous origin of the left circumflex coronary artery: A case report. *Exp Clin Cardiol* 2007;12(4):207-8.