

CASE REPORT

DOI: 10.5336/caserep.2019-70780

Bardet-Biedl Syndrome Diagnosed at an Advanced Age

^{ID} Hatice ŞAHİN^a, ^{ID} Ebru GÖK OĞUZ^a, ^{ID} Kadir Gökhan ATILGAN^a, ^{ID} Levent AKTAŞ^b, ^{ID} Tamer SELEN^a

^aAnkara Dışkapı Yıldırım Beyazıt Training and Research Hospital, Clinic of Nephrology, Ankara, TURKEY

^bAnkara Dışkapı Yıldırım Beyazıt Training and Research Hospital, Clinic of Internal Medicine, Ankara, TURKEY

ABSTRACT Bardet-Biedl syndrome (BBS) is a rare autosomal recessive multi-systemic genetic disorder caused by defects in genes affecting the centrosome and ciliary transport. It is primarily characterized by rod-cone dystrophy, postaxial polydactyly, central obesity, genital abnormalities, renal defects, and mental retardation. Twenty-one genes (BBS1-BBS20 and NPHP1) have been identified to date; the most common genes are BBS1 (Locus 11q13) and BBS10. Chronic kidney disease is a major cause of morbidity and mortality. Herein we presented a patient with chronic renal failure who had delayed diagnosis of BBS. The early diagnosis and a multidisciplinary management of BBS with renal involvement has a critical importance.

Keywords: Bardet-Biedl syndrome; chronic renal failure; obesity; dialysis

Bardet-Biedl syndrome (BBS) was first described in 1920 by Bardet and Biedl.¹ The prevalence of BBS is 1:100,000 in North America and Europe, whereas in isolated communities, high prevalence of 1/18,000 in Newfoundland is noted.² The syndrome is diagnosed based on the presence of at least four major features (rod-cone dystrophy, polydactyly, obesity, genital abnormalities, renal defects, and learning difficulties) or three major and at least two minor features (developmental delay, speech deficit, brachydactyly or syndactyly, dental defects, ataxia or poor coordination, olfactory deficit, diabetes mellitus, and congenital heart disease).^{3,4} Herein, a patient with renal failure who had late diagnosis of BBS is presented.

CASE REPORT

A 49-year old female with chronic fatigue was admitted to the Nephrology Clinic to manage renal replacement therapy. She was single, unemployed, graduated from primary school with poor perform-

ance. She was reported to be obese since adulthood and her menstrual cycles were regular, had vision problems with only the perception of light for the last few years.

The patient had a 10-year history of hypertension, and a 5-year history of type 2 diabetes mellitus. She was undergoing hemodialysis (HD) 3 times in a week for 10 years and was taking glargine insulin, calcitriol, and lecanidipine. The parents did not have consanguineous marriage whereas one younger brother of 7 siblings had similar physical examination findings.

On physical examination, the vital signs were normal except elevated blood pressure, the conjunctiva was pale and the neck was short. The body mass index (BMI) of the patient was 32.5 kg/m² and the extremity examination revealed 6 fingers on the left hand and 7 on the right, with syndactyly between the 4th and 5th fingers of the right hand (Figure 1). There was a brachiocephalic fistula on the left forearm. Examination of the other systems were normal.

Correspondence: Ebru GÖK OĞUZ

Ankara Dışkapı Yıldırım Beyazıt Training and Research Hospital, Department of Nephrology, Ankara, TURKEY

E-mail: ebrugokoguz@hotmail.com



Peer review under responsibility of Türkiye Klinikleri Journal of Case Reports.

Received: 18 Jul 2019

Accepted: 02 Oct 2019

Available online: 08 Oct 2019

2147-9291 / Copyright © 2020 by Türkiye Klinikleri. This is an open access article under the CC BY-NC-ND license (<http://creativecommons.org/licenses/by-nc-nd/4.0/>).

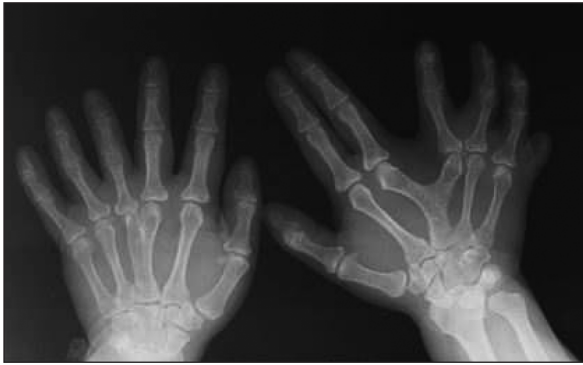


FIGURE 1: 6 fingers on the left hand and 7 on the right, with syndactyly between the 4th and 5th fingers of the right hand.

The laboratory test results of the patient are shown in Table 1. In the urine test, the density: 1004, protein: +, erythrocyte <1, and 2 leukocytes were seen.

In the urinary system ultrasonography (USG), the dimensions of both kidneys were seen to be small (left 70 x 36 mm, right 71.5 x 35 mm), parenchyma echoes increased to Grade 2 and the contours of both kidneys were seen to be lobular and several parapelvic cysts were seen in both kidneys, the largest of which were 10 mm diameter in the upper pole of the left kidney and 21.7 mm diameter in the mid-pole of the right kidney. Ophthalmology consultation was requested because of the loss of sight, and bilateral retinitis pigmentosa was reported. On echocardi-

graphy, left ventricle hypertrophy was determined. In the psychiatric evaluation, a moderate level of mental retardation was determined. No gonadal failure was detected with hormone levels and lower abdomen USG. In the external genital structures, hypoplasia was seen in the labium minora. The dental examination revealed no dental malformation. The audiometry test revealed a mild level of mixed hearing loss bilaterally.

With the findings determined of mental retardation, obesity, polydactyly, learning difficulties and retinitis pigmentosa, the patient was diagnosed with BBS.

Written informed consent was obtained from the patient's parent for publishing this case report.

DISCUSSION

Bardet-Biedl syndrome is a clinical and genetically heterogenous ciliopathy. Ophthalmological findings are seen in varying forms starting from the age of 4-10 years. Although the classical form is retinitis pigmentosa; optic atrophy, nystagmus, iris coloboma, cataract, aniridia, myopia can also be seen.^{5,6} Trunkal obesity is also one of the most commonly seen findings. Of BBS cases, 48% are morbidly obese.^{3,7} The current patient had retinitis pigmentosa and trunkal obesity.

TABLE 1: Laboratory findings on admission.

Blood chemistry		Blood chemistry (hormones)		Peripheral blood	
Glucose (mg/dL)	154	Ferritin (ng/mL)	305	WBC (μL)	7200
Albumin (g/dL)	4.34	PTH (pg/mL)	171.4	Hemoglobin (g/dL)	9.6
Urea (mg/dL)	147	TSH (uIU/mL)	1.13	Platelet (μL)	167x10 ⁹
Creatinine (mg/dL)	4.8	FSH (IU/L)	5.99		
Na (mmol/L)	132	LH (IU/L)	14.51	Serological study	
K (mmol/L)	4.43	Oestradiol (pg/mL)	122	CRP (mg/L)	9.85
Ca (mg/dL)	9	Progesterone (ng/mL)	2.05		
P (mg/dL)	3.8	Total testosterone (ng/mL)	0.72		
TG (mg/dL)	1490	Prolactin (ng/mL)	15.27		
LDL-C (mg/dL)	230	DHEA-S(μg /dL)	39.2		
ALT (U/L)	12	Cortisol (μg/dL)	13.16		
		GH (ng/mL)	1.24		

CRP: C-reactive protein, TG: Triglyceride, LDL-C: Low density lipoprotein cholesterol, PTH: Parathyroid hormone, TSH: Thyroid stimulating hormone, GH: Growth hormone, Na: Sodium, K: Potassium, Ca: Calcium, P: Phosphorous, ALT: Alanine aminotransferase, FSH: Follicle stimulant hormone, LH: Luteinizing hormone, DHEA-S: Dehydro-epiandrosterone sulphate, WBC: White blood cell.

Polydactyly is seen in the feet of 89% of patients and in the hands of 50%. Cranial and dental deformities have been occasionally reported.^{7,8} The patient had post-axial polydactyly with fusion of the 4th and 5th fingers of the right hand. Mental retardation is seen in 87% of cases and intelligence quotient (IQ) points <79 have been reported in 44% of cases. The patient's IQ test score was 55.^{3,7}

In approximately 88% of the patients, there is hypogonadism and small external genitals, with hypogonadism reported more in males.³ The patient had labia minora hypoplasia, but there were no findings of hypogonadotropic hypogonadism.

The prevalence of renal disease in BBS has been reported as 53%-82%.⁹ In the kidney histology, chronic interstitial nephritis, structural changes in the glomerular basal membrane and mesangial proliferative glomerulopathy may be seen.^{10,11} Impaired urine concentration and recurrent urinary system infections are the most common symptoms. Chronic pyelonephritis, and focal segmental glomerulosclerosis may cause renal failure.¹² The syndrome has also been associated with polycystic kidney disease, which is a ciliopathy.¹¹

The most common radiological findings in BBS are renal cyst, diverticulae, calyceal deformity, fetal lobulation, scarring and renal agenesis.¹³ Vesico-ureteral reflux may cause cystic renal disease and calyceal deformity. Therefore, routine investigation for renal anomalies should be made in these patients.^{3,13}

In the majority of the patients, end-stage renal disease develops before the age of 5 years, dialysis is required in most cases within the first year of life. It is difficult to determine the risk factors for kidney disease progression. More severe renal disease has been reported to develop in BBS cases with BBS2, BBS10 and BBS12 gene mutations compared to those with BBS1 gene mutation.⁹

Treatment of BBS is usually symptomatic. Peritoneal dialysis, HD and kidney transplantation options should be presented to the patients with chronic renal

failure. F. Tattoli et al. presented positive results of renal transplantation applied to a BBS patient.¹⁴ No treatment has been found as yet that can delay or halt the loss of vision. Regular ophthalmology examinations should be recommended. Extra fingers can be surgically removed and support should be given for the treatment of obesity. The development of multi-gene sequencing technologies offers hope in BBS, which has a complicated genetic diagnosis.¹⁵ If the patient had been diagnosed early, the potential kidney failure could have been avoided. As the current patient was diagnosed late, the treatment was symptomatic. The patient was offered the option of cadaveric kidney transplantation. Genetic analysis could not be applied because of the high costs involved.

In conclusion, if a patient with renal failure also presents with findings such as polydactyly, mental retardation, obesity and retinitis pigmentosa, BBS should be considered and a multi-disciplinary approach should be applied.

Source of Finance

During this study, no financial or spiritual support was received neither from any pharmaceutical company that has a direct connection with the research subject, nor from a company that provides or produces medical instruments and materials which may negatively affect the evaluation process of this study.

Conflict of Interest

No conflicts of interest between the authors and / or family members of the scientific and medical committee members or members of the potential conflicts of interest, counseling, expertise, working conditions, share holding and similar situations in any firm.

Authorship Contributions

Idea/Concept: Hatice Şahin; **Design:** Hatice Şahin; **Control/Supervision:** Hatice Şahin, Ebru Gök Oğuz, Levent Aktaş; **Data Collection and/or Processing:** Hatice Şahin, Levent Aktaş; **Analysis and/or Interpretation:** Hatice Şahin, Kadir Gökhan Atılğan, Ebru Gök Oğuz; **Literature Review:** Hatice Şahin, Kadir Gökhan Atılğan, Tamer Selen; **Writing the Article:** Hatice Şahin, Tamer Selen, Ebru Gök Oğuz; **Critical Review:** Hatice Şahin, Ebru Gök Oğuz.

REFERENCES

- Green JS, Parfrey PS, Harnett JD, Farid NR, Cramer BC, Johnson G, et al. The cardinal manifestations of Bardet-Biedl syndrome, a form of Laurence-Moon-Biedl syndrome. *N Engl J Med.* 1989;321(15):1002-9. [[Crossref](#)] [[PubMed](#)] [[PubMed](#)]
- Moore SJ, Green JS, Fan Y, Bhogal AK, Dicks E, Fernandez BA, et al. Clinical and genetic epidemiology of Bardet-Biedl syndrome in Newfoundland: a 22-year prospective, population-based, cohort study. *Am J Med Genet A.* 2005;132A(4):352-60. [[Crossref](#)] [[PubMed](#)] [[PMC](#)]
- Beales PL, Elcioglu N, Woolf AS, Parker D, Flinter FA. New criteria for improved diagnosis of Bardet-Biedl syndrome: results of a population survey. *J Med Genet.* 1999;36(6):437-46. [[PubMed](#)]
- Forsythe E, Beales P. Bardet-Biedl syndrome. *Eur J Hum Genet.* 2013;21(1):8-13. [[Crossref](#)] [[PubMed](#)] [[PMC](#)]
- Riise R, Andréasson S, Wright AF, Tornqvist K. Ocular findings in the Laurence-Moon-Bardet-Biedl syndrome. *Acta Ophthalmol Scand.* 1996;74(6):612-7. [[Crossref](#)] [[PubMed](#)]
- Qureshi T, Ayub Nasti AR, Ashai M. Laurence-Moon (Bardet) Biedl syndrome. *JK-Practitioner.* 2003;10(3):217-8.
- Iannello S, Bosco P, Cavaleri A, Camuto M, Milazzo P, Belfiore F. A review of the literature of Bardet-Biedl disease and report of three cases associated with metabolic syndrome and diagnosed after the age of fifty. *Obes Rev.* 2002;3(2):123-35. [[Crossref](#)] [[PubMed](#)]
- Rudling O, Riise R, Tornqvist K, Jonsson K. Skeletal abnormalities of hands and feet in Laurence Moon Bardet Biedl (LMBB) syndrome: a radiographic study. *Skeletal Radiol.* 1996;25(7):655-60. [[Crossref](#)] [[PubMed](#)]
- Forsythe E, Sparks K, Best S, Borrows S, Hoskins B, Sabir A, et al. Risk factors for severe renal disease in Bardet-Biedl syndrome. *J Am Soc Nephrol.* 2017;28(3):963-70. [[Crossref](#)] [[PubMed](#)] [[PMC](#)]
- Price D, Gartner JG, Kaplan BS. Ultrastructural changes in the glomerular basement membrane of patients with Laurence-Moon-Biedl syndrome. *Clin Nephrol.* 1981;16(6):283-8. [[PubMed](#)]
- Tieder M, Levy M, Gubler MC, Gagnadoux MF, Broyer M. Renal abnormalities in the Bardet Biedl syndrome. *Int J Pediatr Nephrol.* 1982;3(3):199-203. [[PubMed](#)]
- Harnett JD, Green JS, Cramer BC, Johnson G, Chafe L, McManamon P, et al. The spectrum of renal disease in Laurence-Moon-Biedl syndrome. *N Engl J Med.* 1988;319(10):615-8. [[Crossref](#)] [[PubMed](#)]
- Dippell J, Varlam DE. Early sonographic aspects of kidney morphology in Bardet-Biedl syndrome. *Pediatr Nephrol.* 1998;12(7):559-63. [[Crossref](#)] [[PubMed](#)]
- Tattoli F, Falconi D, Bottaro C, Gherzi M, Marazzi F, Marengo M, et al. [Bardet-Biedl syndrome and Kidney failure: a case report]. *G Ital Nefrol.* 2018;35(1). [[PubMed](#)]
- Suspitsin EN, Imyaninov EN. Bardet-Biedl syndrome. *Mol Syndromol.* 2016;7(2):62-71. [[Crossref](#)] [[PubMed](#)] [[PMC](#)]