

# Left Internal Carotid Compression Due to Deviation of Elongated Styloid Process: Case Report

## Bir Olguda Uzun ve Deviye Stiloid Çıkıntıya Bağlı Sol İnternal Karotis Darlığı

Mustafa ATEŞÇİ, MD,<sup>a</sup>  
Aydın KARABACAKOĞLU, MD,<sup>a</sup>  
Ufuk GÜLMEZ, MD<sup>b</sup>

Clinics of  
<sup>a</sup>Radiology,  
<sup>b</sup>Cardiology,  
Denizli State Hospital, Denizli

Geliş Tarihi/Received: 16.07.2009  
Kabul Tarihi/Accepted: 24.11.2009

Yazışma Adresi/Correspondence:  
Aydın KARABACAKOĞLU, MD  
Denizli State Hospital,  
Clinic of Radiology, Denizli,  
TÜRKİYE/TURKEY  
radaydin@hotmail.com

**ABSTRACT** Eagle syndrome is an aggregate of symptoms that includes cervicofacial pain and other symptoms caused by an elongated ossified styloid process. More uncommonly, directly attributable to compression of the carotid artery may be seen. In this case, 70 % stenosis was determined at the level of the left internal carotid associated with elongated styloid process. We present the CT angiography findings of this 75-year-old woman with deviation of elongated ossified styloid process.

**Key Words:** Carotid stenosis; Eagle syndrome

**ÖZET** Eagle sendromu, uzun kalsifiye stiloid çıkıntı nedeniyle oluşan servikofasiyal ağrı ve diğer bulguların oluşturduğu semptomlar topluluğudur. Çok nadir olarak karotis arterine direkt kompresyona sebep olabilir. Olgumuzda sol karotis interna düzeyinde stiloid çıkıntıya bağlı olarak %70 darlık saptandı. Bu yazımızda uzun ve deviye stiloid çıkıntıya sahip 75 yaşındaki kadın hastanın BT anjiyografi bulguları sunuldu.

**Anahtar Kelimeler:** Karotid darlığı; Eagle sendromu

**Türkiye Klinikleri J Cardiovasc Sci 2010;22(1):140-3**

In 1937, Eagle described the two cases in which elongated styloid processes that caused fascial pain.<sup>1</sup> There are two subtypes of Eagle Syndrome (ES); first one is classic ES which occurs because when a cranial nerve is damaged. Other one is a rare form of ES and resulting from impingement of the carotid vessels.<sup>2,3</sup>

In this article, we report the CT angiography of compression of the left internal carotid artery due to elongated styloid process that is rarely diagnosed in radiology literature.

### CASE REPORT

The patient was 75 years old female who had headache and hypertension (170/100 mmHg). Findings of the neurologic examination were normal and there was not any pathologic problem. Murmur was diagnosed at the right main carotid vessel of the patient. For this reason, color Doppler Ultrasonography was used in order to examine carotid artery further. Since find-

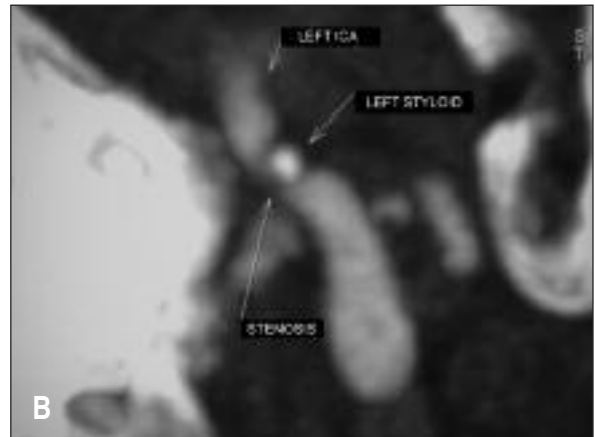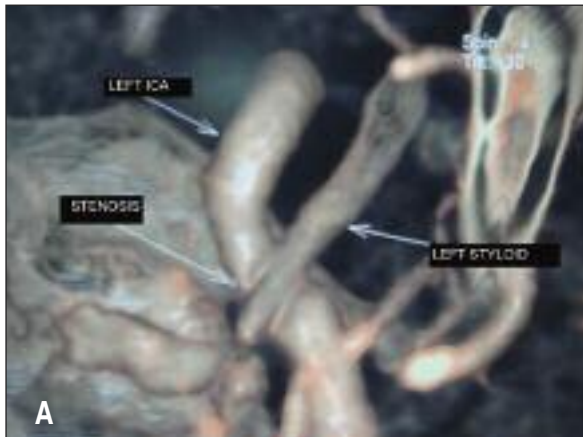ings of sonography of Doppler Ultrasonography were normal, patient was examined by using multislice computed tomography (MSCT). There was not any radiopathological finding at the right main and branches of the carotid artery at MSCT. However, 70% stenosis was determined at the level of the left internal carotid associated with elongated styloid (Figure 1 A, B). Elongated styloid was measured 3.1 cm at right and 3.2 cm at left (Figure 2). Same time, findings showed that there was a medial deviation at the left elongated styloid processes (Figure 3). Right elongated styloid process caused minimal pressure onto internal jugular vein. Pati-

ent did not have headache during antihypertensive therapy and she had been advised to have follow-up clinically for stenosis at the left internal carotid.

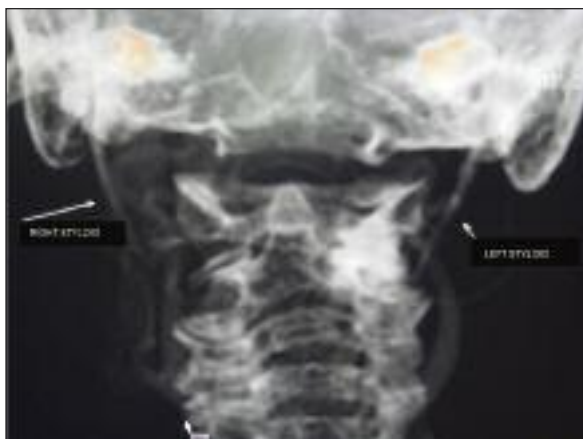## DISCUSSION

Elongated styloid process occurs in 4% of the population and only small part of this ES population (4-10.3%) is considered as symptomatic.<sup>4</sup>

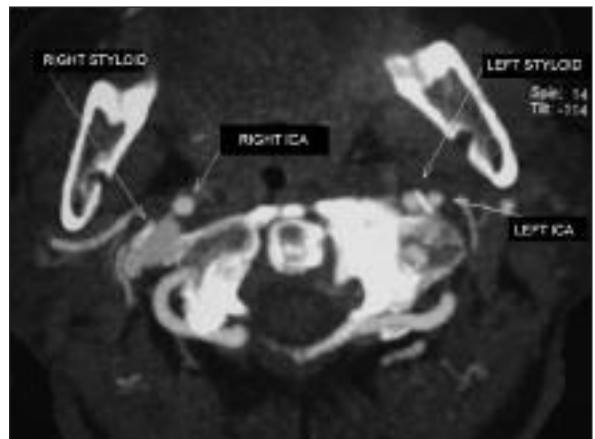
Depends on etiological factors, there are two subtypes in ES syndrome. Typically classic form of ES can be seen after tonsillectomy. Sometimes it can be seen at patients who do not have pharynge-



**FIGURE 1:** Image of the MSCT- left internal carotid artery compressed by left elongated styloid process. (A) thin VRT image at the AP projection; (B) thin MIP image at the transverse oblique projection.



**FIGURE 2:** MIP image at the AP projection of the styloid process in bone protocol. Although length of the both styloid processes were same, because of the deviation of elongated styloid process to medial, left elongated styloid process was close proximity to the left internal carotid artery.



**FIGURE 3:** Axial image of the MSCT; deviation of the left elongated styloid process can be seen compare to the right elongated styloid process. As a result of this deviation, compression of the left internal carotid artery was observed.

al surgery history.<sup>5</sup> In elongated styloid process, there can be some symptoms of previous trauma which can produce proliferation of the granulation tissue,<sup>6</sup> degenerative of stylohyoid ligament, insertion tendonitis because of inflammation changes, irritation of the pharyngeal mucosa, or scar tissue.<sup>7</sup> There could be symptoms that frequently include dysphagia, the sensation of a foreign body in the throat, tinnitus, or otalgia. These symptoms are attributed to impingement of cranial nerves 5, 7, 9, or 10, all of which pass in close proximity to the elongated styloid process.<sup>8,9</sup>

Frequently at ES patients, solid mass at tonsillar fossa at one side or palpation can be found.<sup>2,7,10-12</sup> In our case, pathologically there was no tonsillar fossa and palpation at the patient.

Other form of the ES occurs as a cause of damage of the internal and external carotid artery after deviation of elongated styloid process to medial or lateral. At those cases, accompanying with the internal and/or external artery, irritation of the sympathetic nerves also occur and cause pain across to artery and its branches. At internal carotids artery damage, there may be parietal headaches and pain along the distribution of the ophthalmic artery. The pain may be accompanied with heavy symptoms like aphasia, visual symptoms, tiredness and syncope.<sup>2</sup>

Chuang et al,<sup>2</sup> and Farhat et al.<sup>13</sup> reported at their patients that when patients moved his head to the left and downward, he developed left hemispheric ischemia. These symptoms resolved after he returned the head to the neutral position. Zuber et al, described carotid dissection caused by elongated styloid process.<sup>14</sup> There were not any positional neurologic symptoms. Other than atypical headache, patient did not show any symptoms. Because of headache, patient was examined with CT. Compression to left internal carotid artery was observed related to deviation of elongated styloid pro-

cess to medial.

Several theories have been proposed to explain elongated styloid process. Those are: 1) congenital elongation 2) calcification of the stylohyoid ligament and 3) growth of osseous tissue at the insertion of the stylohyoid ligament.<sup>7</sup> Etiology of the elongated styloid process has not been understood, yet.

If there is a sign of ES, syndrome should be diagnosed by radiologically.<sup>4</sup> Panoramic radiography is frequently used to diagnosis of the elongated styloid process.

Average length of styloid process in adult is approximately 2.5-3 cm in a radiographic measurements.<sup>15</sup> However, Baugh and Stocks, measured the length of the elongated styloid process was about 3-7 cm.<sup>16</sup> Although, the reasons of ES are elongated styloid process or calcification of the styloid ligament, elongated styloid process is not pathognomonic; the most of the patients are asymptomatic.<sup>12</sup> Our patient's styloid process was measured 3.1 cm. at right and 3.2 cm. at left. Although, compression to right internal carotid artery wasn't observed at the patient, 70% stenosis was determined at the level of the left internal carotid associated with elongated styloid. Therefore, compression of the internal carotid artery was occurred related to deviation of elongated styloid process to medial, not the length of the styloid process.

The therapy of the ES may be surgical or medical. At surgical therapy, the longer part of the styloid process is resected. In medical therapy, non-steroid inflammatory drugs and steroid injection are the most commonly used methods.<sup>16,17</sup> At our patient, elongated styloid process was found coincidentally; it did not cause any clinical symptoms. Patient had been prescribed antihypertensive therapy and she had been advised to have follow-up clinically for stenosis at the left internal carotid.

## REFERENCES

1. Eagle WW. Elongated styloid processes: report of two cases. *Arch Otolaryngol* 1937; 25(5):584-7.
2. Chuang WC, Short JH, McKinney AM, Anker L, Knoll B, McKinney ZJ. Reversible left hemispheric ischemia secondary to carotid compression in Eagle syndrome: surgical and CT angiographic correlation. *AJNR Am J Neuroradiol* 2007;28(1):143-5.
3. Eagle WW. Elongated styloid process; further observations and a new syndrome. *Arch Otolaryngol* 1948; 47(5):630-40.
4. Rechtweg JS, Wax MK. Eagle's syndrome: a review. *Am J Otolaryngol* 1998;19(5):316-21.
5. Kim E, Hansen K, Frizzi J. Eagle syndrome: case report and review of the literature. *Ear Nose Throat J* 2008; 87(11):631-3.
6. Balasubramanian S. The ossification of the stylohyoid ligament and its relation to facial pain. *Br Dent J* 1964;116(3):108-11.
7. Balbuena L Jr, Hayes D, Ramirez SG, Johnson R. Eagle's syndrome (elongated styloid process). *South Med J* 1997;90(3):331-4.
8. Gözil R, Yener N, Calgüner E, Araç M, Tunç E, Bahcelioğlu M. Morphological characteristics of styloid process evaluated by computerized axial tomography. *Ann Anat* 2001; 183(6):527-35.
9. Başekim CC, Mutlu H, Güngör A, Silit E, Pekkaşali Z, Kutlay M, et al. Evaluation of styloid process by three-dimensional computed tomography. *Eur Radiol* 2005;15(1):134-9.
10. Eagle WW. Symptomatic elongated styloid process: report of two cases of styloid process-carotid artery syndrome with operation. *Arch Otolaryngol* 1949;49(5): 490-503.
11. Bafaqeeh SA. Eagle syndrome: classic and carotid artery types. *J Otolaryngol* 2000; 29(2):88-94.
12. Murtagh RD, Caracciolo JT, Fernandez G. CT findings associated with Eagle syndrome. *AJNR Am J Neuroradiol* 2001;22(7):1401-2.
13. Farhat HI, Elhammady MS, Ziayee H, Aziz-Sultan MA, Heros RC. Eagle syndrome as a cause of transient ischemic attacks. *J Neurosurg* 2009;110(1):90-3.
14. Zuber M, Meder JF, Mas JL. Carotid artery dissection due to elongated styloid process. *Neurology* 1999;53(8):1886-7.
15. Eagle WW. Elongated styloid process; symptoms and treatment. *AMA Arch Otolaryngol* 1958;67(2):172-6.
16. Baugh RF, Stocks RM. Eagle's syndrome: a reappraisal. *Ear Nose Throat J* 1993; 72(5):341-4.
17. Martin TJ, Friedland DR, Merati AL. Transcervical resection of the styloid process in Eagle syndrome. *Ear Nose Throat J* 2008; 87(7): 399-401.