

Lipemia Retinalis: Case Report

Lipemia Retinalis

Diñçer DİNÇ,^a
Nurhan DİNÇER,^a
Kadir ELTUTAR^a

^aClinic of Ophthalmology,
İstanbul Training and
Research Hospital, İstanbul

Geliş Tarihi/Received: 20.12.2010
Kabul Tarihi/Accepted: 17.04.2011

*This case was presented as a poster at the
42nd Turkish Ophthalmology Congress in
Antalya, Türkiye, 19-23 November 2008.*

Yazışma Adresi/Correspondence:
Diñçer DİNÇ
İstanbul Training and
Research Hospital,
Clinic of Ophthalmology, İstanbul
TÜRKİYE/TURKEY
drdincerdinc@hotmail.com

ABSTRACT A 27-year-old and 34-week-pregnant woman presented with a one-week history of blurred vision in both eyes. The patient's best corrected visual acuity was 0.1 in both eyes for Snellen chart. Fundus examination revealed hemorrhages and exudates on the posterior pole. Laboratory studies disclosed the following values: Triglyceride 1478 mg/dL (normal range, 0-150 mg/dL), total serum cholesterol 1292 mg/dL (normal range, 0-200 mg/dL), and low-density lipoprotein (LDL) 220 mg/dL (normal range, 0-160 mg/dL). Findings of lipoprotein electrophoresis were consistent with familial combined hyperlipidemia. After treatment, triglyceride level decreased to 1160 mg/dL and total serum cholesterol level to 200 mg/dL. Visual acuity of the patient was 10/10 and fundus examination was almost normal. Life threatening diseases such as acute pancreatitis or cardiovascular and cerebrovascular diseases may develop in chylomicronemia. Fundus examination findings are valuable for the diagnosis and treatment of this disease.

Key Words: Hyperlipidemia, familial combined; hyperlipidemias

ÖZET Yirmi yedi yaşında 34 haftalık gebe hasta her iki gözünde son bir haftadır gelişen bulanık görme şikayetiyle başvurdu. En iyi düzeltilmiş görme keskinliği her iki gözünde Snellen eşeline göre 0,1 düzeyindeydi. Hastanın göz dibi muayenesinde arka kutupta kanamalar ve eksüdatyonlar mevcuttu. Laboratuvar tetkiklerinde serum trigliserit düzeyi 1478 mg/dL (normal aralık 0-150 mg/dL), serum total kolesterol düzeyi 1292 mg/dL (normal aralık 0-200 mg/dL) ve serum düşük dansiteli lipoprotein (LDL) düzeyi 220 mg/dL (normal aralık 0-160 mg/dL) olarak bulundu. Lipoprotein elektroforezi ailesel kombine hiperlipidemi ile uyumluydu. Tedaviden sonra trigliserit seviyesi 1160 mg/dL'ye ve total serum kolesterol seviyesi 200 mg/dL'ye geriledi. Hastanın görme keskinliği 10/10 idi ve göz dibi görünümü normale yakındı. Şilomikronemi sonucunda akut pankreatit veya kardiyovasküler ve serebrovasküler hastalık gibi hayati tehlike oluşturan hastalıklar gelişebilmektedir. Fundus muayene bulguları bu hastalığın tanı ve tedavisinde değerlidir.

Anahtar Kelimeler: Hiperlipidemi, ailesel kombine; hiperlipidemiler

Türkiye Klinikleri J Med Sci 2012;32(5):1433-6

The association of hyperlipidemia and pregnancy is well recognized. During pregnancy of healthy women, it is usual for blood lipids to increase significantly. Total cholesterol, high density lipoprotein (HDL)- and low density lipoprotein (LDL)-cholesterol increase 25-50%, while triglycerides increase twice to four times. Clinical problems include treatment dilemmas in women during the preconception period, diagnosis of hyperlipidemia in pregnancy and treatment during pregnancy. Antihyperlipemic drug groups are generally not considered completely harmless

during the preconception and pregnancy period. Those patients who had low to medium increased values of triglycerides prior to pregnancy may develop severe hypertriglyceridemia, especially in the third trimester. They must be educated about dietetic measures and body mass reduction even in the preconception period.¹

Lipemia retinalis is a rare condition first described by Heyl in 1880 and is characterized by elevated levels of serum triglycerides.² Hypertriglyceridemia may be a primary familial disorder or may develop secondary to systemic disorders including uncontrolled diabetes mellitus, hypothyroidism, alcoholism, biliary obstruction, and nephrotic syndrome.³⁻⁵ In lipemia retinalis, the posterior pole and peripheral retina have the color of salmon pink. The colors of retinal vessels vary between salmon pink to creamy-white depending on the serum triglyceride levels.^{6,7} The classification of fundus appearance in lipemia retinalis is as follows: Grade I- white and creamy appearance of the peripheral retina vessels; Grade II- the creamy color of the vessels enlarged towards the optic disc; Grade III- the retina appears as salmon colored and all vessels present a milky appearance.⁸ These retinal findings occur when the serum triglyceride levels increase to 2000-2500 mg/dL and after returning to normal levels (normal range, 0-150 mg/dL) the fundus appearance becomes normal.^{6,9}

CASE REPORT

A 27-year-old and 34-week-pregnant woman presented with a one-week history of blurred vision in both eyes. Ophthalmologic examination revealed that the pupils were isochoric, best corrected visual acuity (BCVA) was 0.1 in both eyes for Snellen chart, corneas were transparent, and intraocular pressures were normal. Fundus examination revealed hemorrhages and exudates on the posterior pole and all vessels presented a milky appearance (Figure 1). Physical examination revealed no eruptive xanthomas and no abdominal findings. The first laboratory studies disclosed the following results: Triglyceride 1478 mg/dL (normal range, 0-150 mg/dL), total serum cholesterol 1292 mg/dL (normal range, 0-200 mg/dL), and LDL 220 mg/dL (normal range, 0-160 mg/dL). Findings of lipoprotein electrophoresis were consistent with familial combined hyperlipidemia. The patient had a hyperlipidemia history before pregnancy. The patient had no family history of hyperlipidemia. This condition was associated to pregnancy-induced hyperlipidemia. After delivery, the BVCA of the patient improved to 0.7 for both eyes and fundus changes were better than the first examination. In the third month of the treatment with a low-fat diet, physical exercise, intravenous fluids and drugs [inhibitors of 3-hydroxy-3-methyl-glutaryl-coenzyme A (HMG-CoA) reductase] triglyceride

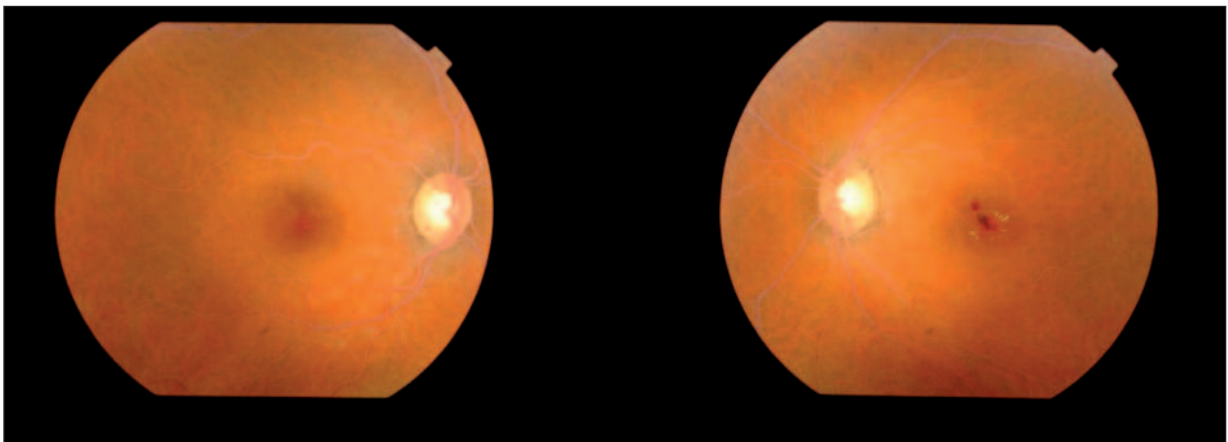


FIGURE 1: Initial fundus appearance.

(See for colored form <http://tipbilimleri.turkiyeklinikleri.com/>)

level decreased to 1160 mg/dL and total serum cholesterol level to 200 mg/dL (Table 1). The visual acuity increased to 10/10 and fundus appearance was almost normal. In the first year of treatment, BCVA was 10/10 and the fundus examination was almost normal (Figure 2).

DISCUSSION

Lipemia retinalis is a rare condition occurring with high levels of serum triglycerides. It may develop in all age groups with primary or secondary hyperlipidemia.¹⁰ The white milky appearance of the retinal vessels occurs when the plasma triglyceride levels increase ≥ 2000 mg/dL.⁸ This milky appearance is related to light reflection due to the chylomicrons.⁶

Our patient was receiving treatment for hyperlipidemia in the first ophthalmologic examination therefore although serum triglyceride level was 1478 mg/dL, fundus examination revealed hemorrhages and exudates on the posterior pole

and all vessels presented a milky appearance, which was consistent with lipemia retinalis.

Sassa et al. reported a patient with lipemia retinalis.⁹ His serum triglyceride level was 12.936 mg/dL and BCVA was 20/16 in both eyes. Recently, Park et al. reported a case with lipemia retinalis and with triglyceride level of 11.929 mg/dL.¹¹ This 26-year-old man had no problems with his vision. However, serum triglyceride level was 1478 mg/dL in our patient and her BVCA was 0.1 in the first ophthalmologic examination, which may be associated with hemorrhages and exudates in the posterior pole. After hyperlipidemia treatment, BVCA increased to 10/10.¹²

Fundus findings in lipemia retinalis improve after serum triglyceride and chylomicron levels decrease.² Although it is well-established that pregnancy is associated with an increase in plasma triglyceride levels, how this increase occurs is not clear.¹³ In addition, certain persons express profound elevations in triglyceride values during preg-

TABLE 1: Pre- and post-treatment findings of the patient.

Findings	Baseline	After three months of treatment
Visual acuity	1/10	10/10
Triglyceride levels	1478 mg/dL	1160 mg/dL
Total cholesterol levels	1292 mg/dL	220 mg/dL

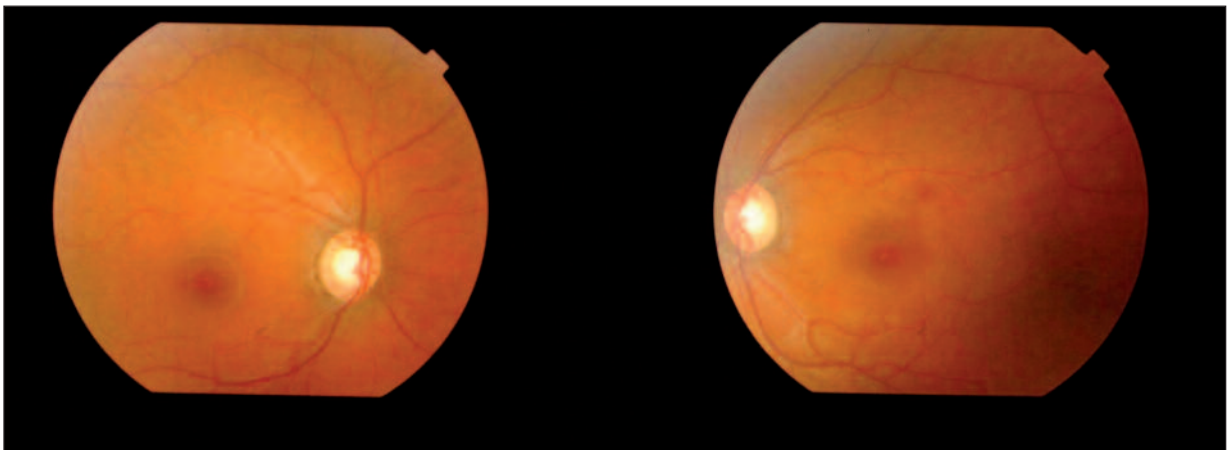


FIGURE 2: After one year of treatment fundus appearance was almost normal. (See for colored form <http://tipbilimleri.turkiyeklinikleri.com/>)

nancy.^{14,15} There is no physiologic explanation for this unique population of pregnant patients with hypertriglyceridemia.

In our case, after three months of treatment with a low-fat diet, physical exercise, intravenous fluids and drugs (inhibitors of 3-hydroxy-3-methyl-glutaryl-coenzyme A (HMG-CoA) reductase), the triglyceride level decreased to 1160 mg/dL and total serum cholesterol to 200 mg/dL. BCVA increased to 10/10 and fundus examination was almost normal. The safety and efficacy of fibric acid derivatives and of inhibitors of 3-hydroxy-

3-methyl-glutaryl-coenzyme A (HMG-CoA) reductase in pregnancy are not established. Plasma exchange and total parenteral nutrition are various treatment options.^{16,17}

In conclusion, life-threatening diseases including acute pancreatitis, cardiovascular or cerebrovascular diseases may develop in chylomicronemia. Lipemia retinalis should be considered a significant clue especially for pregnancy-induced hyperlipidemia. Hyperlipidemia and fundus examination findings are valuable for the diagnosis and treatment of this disease.

REFERENCES

- Dukić A, Zivancević-Simonović S, Varjacić M, Dukić S. [Hyperlipidemia and pregnancy]. *Med Pregl* 2009;62(Suppl 3):80-4.
- Cypel M, Manzano R, Dos Reis FA, Ishida N, Ayhara T. Lipemia retinalis in a 35-day-old infant with hyperlipoproteinemia: case report. *Arq Bras Oftalmol* 2008;71(2):254-6.
- Uwaydat SH, Mansour AM. Infantile lipemia retinalis and conjunctivalis. *J Pediatr Ophthalmol Strabismus* 2000;37(1):47-9.
- Gürsoy G. [Secondary hyperlipidemias]. *Türkiye Klinikleri J Int Med Sci* 2005;1(20):17-20.
- Özgil D, Yumuk V. [Classification, diagnosis and clinical manifestations of primary hyperlipidemias]. *Türkiye Klinikleri J Int Med Sci* 2005;1(20):12-6.
- Vinger PF, Sachs BA. Ocular manifestations of hyperlipoproteinemia. *Am J Ophthalmol* 1970;70(4):563-73.
- Dinc UA, Tattipinar S, Ciftci F. [Fundus autofluorescence in central retinal artery occlusion]. *Yeditepe Medical Journal* 2010;4(1):258-61.
- Rayner S, Lee N, Leslie D, Thompson G. Lipaemia retinalis: a question of chylomicrons? *Eye (Lond)* 1996;10(Pt 5):603-8.
- Sassa Y, Matsui K, Yoshikawa N, Kajiwara I, Hata Y. Lipemia retinalis: low-density lipoprotein apheresis improved the appearance of retinal vessels in a patient with type 5 hyperlipoproteinemia. *Retina* 2005;25(6):803-4.
- Eng KT, Liu ES, Silverman MS, Berger AR. Lipemia retinalis in acquired immunodeficiency syndrome treated with protease inhibitors. *Arch Ophthalmol* 2000;118(3):425-6.
- Park YH, Lee YC. Images in clinical medicine. Lipemia retinalis associated with secondary hyperlipidemia. *N Engl J Med* 2007;357(10):e11.
- Ozkan Y, Colak R, Koca SS, Dag S, Kan EK, Sirma N. [Diabetes mellitus and hyperlipidemia: how successful we are in the treatment?]. *Fırat University Medical Journal of Health Sciences* 2008;22(2):97-100.
- Gillett MP, Silva TB, Besterman EM. Plasma lipids and HDL cholesterol during pregnancy. *Atherosclerosis* 1979;33(4):495-7.
- Nies BM, Dreiss RJ. Hyperlipidemic pancreatitis in pregnancy: a case report and review of the literature. *Am J Perinatol* 1990;7(2):166-9.
- Watts GF, Morton K, Jackson P, Lewis B. Management of patients with severe hypertriglyceridaemia during pregnancy: report of two cases with familial lipoprotein lipase deficiency. *Br J Obstet Gynaecol* 1992;99(2):163-6.
- Yamauchi H, Sunamura M, Takeda K, Suzuki T, Itoh K, Miyagawa K. Hyperlipidemia and pregnancy associated pancreatitis with reference to plasma exchange as a therapeutic intervention. *Tohoku J Exp Med* 1986;148(2):197-205.
- Weinberg RB, Sitrin MD, Adkins GM, Lin CC. Treatment of hyperlipidemic pancreatitis in pregnancy with total parenteral nutrition. *Gastroenterology* 1982;83(6):1300-5.