

Self Regeneration of a Comprehensive Bony Defect and Mandibular Nerve Following Mandibular Resection

Mandibular Rezeksiyon Sonrası Geniş Kemik Defektinin ve Mandibular Sinirin Rejenerasyonu

^{id} Mehmet Zahit BAŞ^a, ^{id} Rümeyza BALCI^a, ^{id} Aslı BAŞKAN ÖNAL^a

^aDepartment of Oral and Maxillofacial Surgery, University of Health Sciences Faculty of Hamidiye Dentistry, İstanbul, Türkiye

ABSTRACT Few cases of spontaneous bone regeneration after extensive resection of the jaw bone have been reported, but there are not too many reports that show spontaneous nerve regeneration. In this case, we report spontaneous bone and nerve healing in a 67-year-old female patient. She was diagnosed with medication-related osteonecrosis of the jaw due to previous bisphosphonate use. After segmental resection, stabilization was achieved using a reconstruction plate. Three years later, panoramic radiography was taken, and bone formation was seen horizontally and vertically, not around the plate but on the upside. More than that, the patient didn't feel her low lip since the operation as expected. But after 6 months, in routine check-ups, she discerns the feeling of the lower lip again from the patient. There is approximately 60% sensation compared to the right side.

Keywords: Bisphosphonate-associated osteonecrosis of the jaw; bone regeneration; nerve regeneration

ÖZET Çene kemiğinin geniş rezeksiyonu sonrası birkaç spontan kemik rejenerasyonu vakası bildirilmiştir ancak spontan sinir rejenerasyonunu gösteren birkaç tane rapor vardır. Bu olguda, 67 yaşında kadın hastada spontan kemik ve sinir iyileşmesi rapor edilmiştir. Daha önce bifosfonat kullanımına bağlı olarak çenede ilaca bağlı osteonekroz teşhisi konulan hastanın mandibular molar bölgesine segmental rezeksiyon uygulandıktan sonra rekonstrüksiyon plağı kullanılarak stabilizasyonu sağlanmıştır. Üç yıl sonra yapılan radyolojik kontrolde plaktan uzak bir bölgede kemik oluşumu gözlenmiştir. Bununla birlikte operasyon sonrasında alt dudak hissetmeyen hastanın 6 ay sonra rutin kontrollerde alt dudak hissini tekrar ayırt etmeye başladığı anlaşılmıştır. Hastanın sol alt dudaklarını sağ tarafa göre yaklaşık %60 hissettiği tespit edilmiştir.

Anahtar Kelimeler: Çenenin bifosfonatla ilişkili nekrozu; kemik yenilenmesi; sinir yenilenmesi

Bisphosphonates (BPs) are non-metabolized drugs that can settle in bone and inhibit osteoclastic function. BPs are antiresorptive drugs used in the treatment of certain diseases. These diseases include some types of cancer (breast cancer, multiple myeloma, etc.) and some bone diseases (Paget's disease, osteoporosis). BPs can be administered to patients orally or intravenously.¹ Segmental mandibular resection is sometimes used to eliminate disease states within the mandible and this has concomitant negative consequences on the patient's quality of life. These composite defects have been repaired with autologous bone grafts, homologous grafts, or heterogeneous materials, with additional morbidity and

complications for the patient.² Spontaneous bone regeneration (SBR) or spontaneous mandibular regeneration is defined as the fast, often unforeseen, formation of new cortical bone in a previous mandibular defect and has been rarely described nevertheless, some cases have been reported in the literature.²⁻⁴ The exact factors controlling SBR are not well defined. But, it is thought that the patient's age, presence of infection, periosteal protection, immobilization and genetic factors are affected.⁵ In this case, we report spontaneous bone and nerve healing in a 67-year-old female patient with Medication-Related Osteonecrosis of the Jaws (MRONJ) diagnoses.

Correspondence: Mehmet Zahit BAŞ

Department of Oral and Maxillofacial Surgery, University of Health Sciences Faculty of Hamidiye Dentistry, İstanbul, Türkiye

E-mail: mehmet_bass@windowslive.com



Peer review under responsibility of Türkiye Klinikleri Journal of Dental Sciences.

Received: 29 Jun 2022

Received in revised form: 15 Feb 2023

Accepted: 16 Feb 2023

Available online: 20 Feb 2023

2146-8966 / Copyright © 2023 by Türkiye Klinikleri. This is an open access article under the CC BY-NC-ND license (<http://creativecommons.org/licenses/by-nc-nd/4.0/>).

CASE REPORT

A 65-year-old female patient applied to the Department of Maxillofacial Surgery, Hamidiye Faculty of Dentistry, University of Health Sciences in 2018 due to pain in her tooth. After taking a detailed anamnesis, it was revealed that the patient used BPs after chemotherapy as a result of cervical cancer in 2013. After the patient used BPs once every month for 5 years, the patient's medication was discontinued for tooth extraction for 3 months and tooth extraction was performed by another doctor at the end.

After tooth extraction, the patient started taking the medication (BP) again. At the end of 6 months, the patient was admitted to our clinic again with the complaint of persistent and non-reducing jaw pain in his jaw. After a while, discharge and abscess were added to her complaints. The case was diagnosed as MRONJ Stage III based on the guidelines of the American Association of Oral and Maxillofacial Surgeons as a result of the patient's intraoral and radiographic examination.⁶

As a result, the patient's BP intake was stopped again and waited for 1 year, and she was taken into surgery. An informed consent form was taken from the patient before surgery. During this waiting period, the patient was followed up with conservative treatment. But the necrotic area enlarged (Figure 1).

During the operation, the patient's left lower mandible molar region was completely resected and supported with a reconstruction plate for stabilization. The resection was performed without protecting the nerve because of the defect (Figure 2). After the operation, the patient had a feeling of numbness in

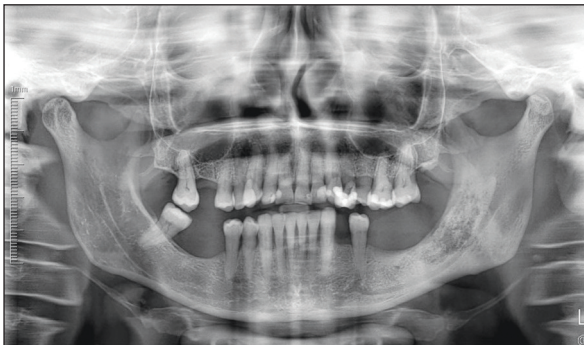

FIGURE 1: Pre-operative radiography.

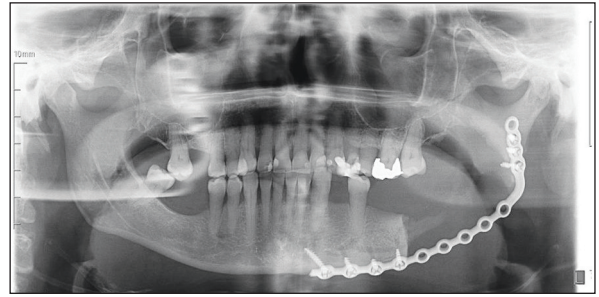


FIGURE 2: Post-operative radiography.

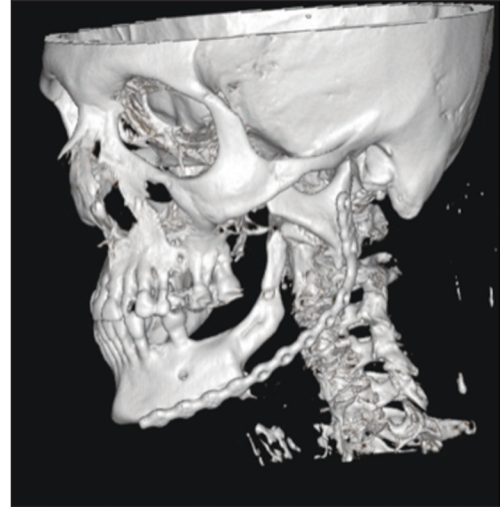


FIGURE 3: Bone regeneration in the operated area can be seen in the computed tomography image taken 3 years after the operation.

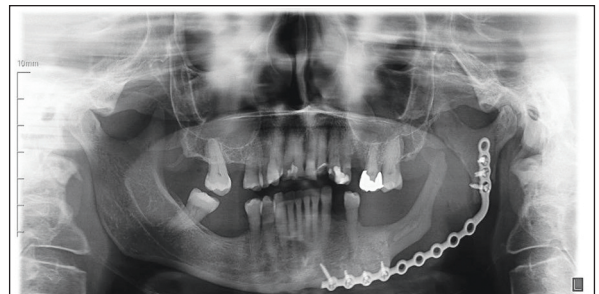


FIGURE 4: Bone regeneration in the operated area can be seen in the panoramic radiograph taken 3 years after the operation.

her lower lip, but after a while, she started to feel his lip again. In the following 3 and 6 months, it was observed that the patient's feeling was very good on the left side with partial paresthesia compared to the right side. The patient came back for control after 2 years and SBR was observed in the tomography (Figure 3 and Figure 4). "Two-point discrimination test" and "Medical Research Council (MRC) grading system"

were evaluated when the patient came to the follow-up after two years. According to the patient's sensation, the MRC grading system was found to be Grade 3. In the two-point discrimination test, on the left side of the patient, there is two-point separation at 3 cm.

DISCUSSION

SBR is a rare and unexpected form of bone repair in which bone tissues become critically sized bone defects.⁷ The first study that takes part in literature, to mention spontaneous mandibular bone regeneration was by Kazanjian published in 1946. According to this case, mandibular resection was performed on a 15-year-old patient with the diagnosis of ossifying fibroma. The periosteum was preserved in the operation and the first bone formation was observed 3 months after the surgery.³ In another study, Anyanechi et al. found that with a total of 636 mandibular resection cases, SBR was seen in only 13 patients which means 2%.⁷

Osteoinduction, osteoconduction, and osteogenesis are building stones of new bone formation. Stable and non-attached undifferentiated mesenchymal cells in the periosteum and endosteum contribute to fracture healing. In addition, mesenchymal cells in the connective tissue can be stimulated by the remaining bone fragments to form new bone and marrow.⁸

As previously mentioned, in Anyanechi et al. study, 13 patients with SBR were aged between 16 and 51 years. In their study, 7 of the patients with SBR were male, and 6 were female. In their study, it was observed that bone regeneration started earlier in younger patients.⁷ Our patient was 64 years old when she applied to our clinic and at age of 65, she was operated on. Our female patient, who used BP group drugs and underwent segmental resection of the mandible because of the MRONJ, had previously been treated for cervical cancer. Although she was having a disadvantage in terms of systemic health, bone regeneration was observed in our patient.

Various studies have reported that immobilization and preservation of the periosteum may affect spontaneous bone healing. In our case, a reconstruction plate was used to provide fixation. In our case,

we think that the immobilization of the reconstruction plate, which was bent according to the shape of the mandible, was achieved with a sufficient number of screw fixation. It is known that osteoprogenitor cells originate from the periosteum. It is believed that preservation of the periosteum during the operation is vital for spontaneous regeneration. The presence of an intact periosteum, or at least part of it, triggers SBR.⁹ The periosteum was preserved while our patient was operated and atraumatic surgery was performed.

Another substantial issue, in this case, is the recovery of sensation. As in Pogrel's study, the patient's "two-point discrimination test" and "MRC grading system" were evaluated.¹⁰ According to the MRC grading system-Grade S0 no recovery; Grade S1 recovery of deep cutaneous pain and tactile sensibility; Grade S2 recovery of some degree of superficial cutaneous pain and tactile sensibility; Grade S3 return of superficial cutaneous pain and tactile sensibility without over response; Grade S4 full recovery. This grading system is subjective to the patient which in this case she is Grade S3. In the two-point discrimination test, 2 points are separated at 3 cm. As a result of various tests applied to the patient; also can sense thermal stimuli and pressure. In Pogrel's study, the inferior alveolar nerve was completely resected in all patients and no correlation was found between the degree of return of sensation and the length of the resection.¹⁰ In this case, it was thought that the return of sensation is probably from ingrowth of surrounding nerves, including the mylohyoid nerve, the contralateral mental nerve, and possibly the cutaneous nerves of the neck, but was not due to regeneration of the inferior alveolar nerve.¹⁰

This report describes a case of bone regeneration in a 67-year-old female who had mandibular resection for an extensive case of MRONJ.

In conclusion, if the periosteum is preserved and stabilized after resection in benign lesions, the bone can regenerate spontaneously. Therefore, monitoring of spontaneous bone healing during follow-up is important in cases where autogenous bone is not applied concurrently with resection. For small resection areas, SBR can reduce the need for complicated surg-

eries. This can improve patient comfort and reduce surgical cost.

More research and evidence is needed to grasp the physiological causes of nerve regeneration that allows the patient to feel her left lip again.

Source of Finance

During this study, no financial or spiritual support was received neither from any pharmaceutical company that has a direct connection with the research subject, nor from a company that provides or produces medical instruments and materials which may negatively affect the evaluation process of this study.

Conflict of Interest

No conflicts of interest between the authors and / or family mem-

bers of the scientific and medical committee members or members of the potential conflicts of interest, counseling, expertise, working conditions, share holding and similar situations in any firm.

Authorship Contributions

Idea/Concept: Mehmet Zahit Baş; **Design:** Mehmet Zahit Baş; **Control/Supervision:** Mehmet Zahit Baş; **Data Collection and/or Processing:** Mehmet Zahit Baş, Rümeysa Balcı, Aslı Başkan Önal; **Analysis and/or Interpretation:** Mehmet Zahit Baş, Rümeysa Balcı, Aslı Başkan Önal; **Literature Review:** Mehmet Zahit Baş, Rümeysa Balcı, Aslı Başkan Önal; **Writing the Article:** Mehmet Zahit Baş, Rümeysa Balcı, Aslı Başkan Önal; **Critical Review:** Mehmet Zahit Baş, Rümeysa Balcı, Aslı Başkan Önal; **References and Fundings:** Mehmet Zahit Baş, Rümeysa Balcı, Aslı Başkan Önal; **Materials:** Mehmet Zahit Baş, Rümeysa Balcı, Aslı Başkan Önal.

REFERENCES

- Ruggiero SL, Mehrotra B, Rosenberg TJ, Engroff SL. Osteonecrosis of the jaws associated with the use of bisphosphonates: a review of 63 cases. *J Oral Maxillofac Surg.* 2004;62(5):527-34. [[Crossref](#)] [[PubMed](#)]
- Malik NA. Benign tumours of the Jaw Bones. *Textbook of Oral and Maxillofacial Surgery.* 2nd ed. New Delhi: Jaypee; 2008. p.469-512.
- Kazanjian VH. Spontaneous regeneration of bone following excision of section of the mandible. *Am J Orthod Oral Surg.* 1946;32:242-8. [[Crossref](#)] [[PubMed](#)]
- Martins WD, de Castro Avila LF. Partial spontaneous bone regeneration subsequent to mandibulectomy. *J Contemp Dent Pract.* 2004;5(3):108-20. [[Crossref](#)] [[PubMed](#)]
- Ahmad O, Omami G. Self-regeneration of the mandible following hemimandibulectomy for ameloblastoma: a case report and review of literature. *J Maxillofac Oral Surg.* 2015;14(Suppl 1):245-50. [[Crossref](#)] [[PubMed](#)] [[PMC](#)]
- Ruggiero SL, Dodson TB, Fantasia J, Goodday R, Aghaloo T, Mehrotra B, et al; American Association of Oral and Maxillofacial Surgeons. American Association of Oral and Maxillofacial Surgeons position paper on medication-related osteonecrosis of the jaw--2014 update. *J Oral Maxillofac Surg.* 2014;72(10):1938-56. Erratum in: *J Oral Maxillofac Surg.* 2015;73(7):1440. Erratum in: *J Oral Maxillofac Surg.* 2015;73(9):1879. [[Crossref](#)] [[PubMed](#)]
- Anyanechi CE, Saheeb BD, Bassey GO. Spontaneous bone regeneration after segmental mandibular resection: a retrospective study of 13 cases. *Int J Oral Maxillofac Surg.* 2016;45(10):1268-72. [[Crossref](#)] [[PubMed](#)]
- de Villa GH, Chen CT, Chen YR. Spontaneous bone regeneration of the mandible in an elderly patient: a case report and review of the literature. *Chang Gung Med J.* 2003;26(5):363-9. [[PubMed](#)]
- Rai S, Rattan V, Jolly SS, Sharma VK, Mubashir MM. Spontaneous regeneration of bone in segmental mandibular defect. *J Maxillofac Oral Surg.* 2019;18(2):224-8. [[Crossref](#)] [[PubMed](#)] [[PMC](#)]
- Pogrel MA. Recovery of sensation over the distribution of the inferior alveolar nerve following mandibular resection without nerve reconstruction. *J Oral Maxillofac Surg.* 2021;79(10):2143-6. [[Crossref](#)] [[PubMed](#)]