

Massive Subepicardial Hematoma Formation Dissecting Whole Epicardium Following Percutaneous Coronary Intervention: Case Report

Perkütan Koroner Girişim Sonrası Tüm Epikardı Diseke Eden Masif Subepikardiyal Hematom

Erdem ÇETİN,^a
Arda ÖZYÜKSEL,^b
Sinan Sabit KOCABEYOĞLU,^c
Ahmet ÇALIŞKAN^d

^aClinic of Cardiovascular Surgery, Memorial Hospital, Diyarbakır,

^bDepartment of Cardiovascular Surgery, İstanbul Medipol University Faculty of Medicine, İstanbul,

^cClinic of Cardiovascular Surgery,

Türkiye Yüksek İhtisas Hospital Ankara,

^dDepartment of Cardiovascular Surgery, Dicle University Faculty of Medicine, Diyarbakır

Geliş Tarihi/Received: 15.03.2013

Kabul Tarihi/Accepted: 27.07.2013

This study was presented as a poster at 7th Cardiology and Cardiovascular Surgery Innovations Congress, 24-27 March 2011, Antalya

Yazışma Adresi/Correspondence:

Arda ÖZYÜKSEL

İstanbul Medipol University

Faculty of Medicine,

Department of Cardiovascular Surgery,

İstanbul,

TÜRKİYE/TURKEY

ozyukselarda@yahoo.com

ABSTRACT Percutaneous coronary interventions are widely utilized in the era of cardiovascular diseases. Life threatening complications may be encountered such as coronary artery dissection and perforation. In this paper, we present a patient with coronary artery perforation and its operative findings after intervention for the total occlusive lesion of the circumflex artery. Acute hemodynamic instability without pericardial tamponade was encountered in the case. Urgent surgical intervention was performed, subepicardial hematoma formation which was dissecting the whole epicardium was encountered. Exact area of perforation could not be located. Hemodynamic stability was achieved by means of draining the subepicardial hematoma. Mechanical complications should be kept in mind in cases with sudden hemodynamic instability without pericardial tamponade, seen after percutaneous interventions especially performed for total occlusive coronary artery lesions.

Key Words: Angioplasty, balloon, coronary; hematoma; complications

ÖZET Perkütan koroner girişimler kardiyovasküler hastalıklarda gün geçtikçe daha çok kullanılmakta olan tedavi yöntemidir. Nadiren de olsa koroner arter diseksiyonu ve perforasyonu komplikasyon olarak görülebilmekte ve hayatı tehdit edebilmektedir. Bu makalede, sirkümfleks damardaki tam tıkalı lezyona perkütan girişim sonrası gelişen koroner perforasyon ve vakanın operatif bulgusu sunulmaktadır. Olguda perikard tamponadı olmaksızın ani gelişen hemodinamik instabilite söz konusu olmuştur. Erken cerrahi girişim yapılarak tüm epikardı diseke eden masif subepikardiyal hematom oluşumu ile karşılaşmış olup koroner perforasyon bölgesi lokalize edilememiştir. Subepikardiyal hematom drene edilerek hastada hemodinamik stabilite sağlanmıştır. Özellikle tam tıkalı koroner lezyonlara yapılan perkütan girişimlerde perikardiyal tamponad olmaksızın ani gelişen hemodinamik instabilitede mekanik komplikasyonlar akılda tutulmalı ve hastaya acil cerrahi tedavi planlanmalıdır.

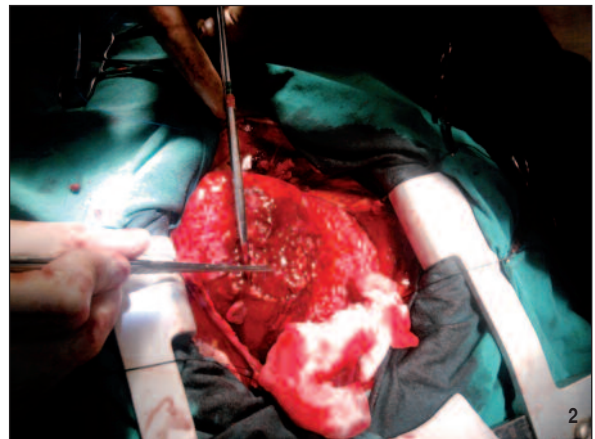
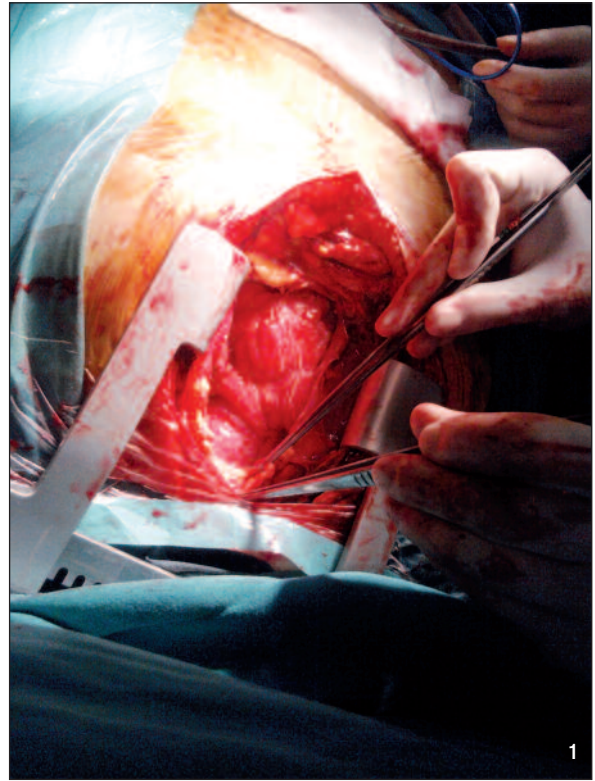
Anahtar Kelimeler: Anjiyoplasti, balon, koroner; hematom; komplikasyonlar

Türkiye Klinikleri J Case Rep 2014;22(1):55-7

Percutaneous coronary intervention (PCI) is widely utilized in the era of cardiovascular diseases. Although rare, life threatening complications may be encountered such as coronary artery dissection and perforation.¹ Subepicardial hematomas are mainly reported in patients with prior coronary artery bypass grafting (CABG) and it's very rare in non-CABG patients.² In this case we present a case with massive subepicardial hematoma formation without pericardial tamponade following PCI for circumflex artery lesion.

CASE REPORT

PCI was performed in a 60 years old male patient with total occlusion of circumflex coronary artery accompanied with 40% stenosis of right coronary artery before the crux. His medical history revealed diabetes mellitus (type II) and chronic obstructive pulmonary disease (COPD). Any critical lesion was not encountered in LAD. After the procedure of balloon inflation for the totally occluded circumflex artery lesion, extravasation was observed on cineangiography. Bedside echocardiography did not reveal any significant finding of pericardial tamponade. With worsening hemodynamic instability in the catheterization lab, we proceeded with urgent surgery. Following midline sternotomy and pericardiotomy, 400 cc hemorrhagic fluid was drained. Massive subepicardial hematoma formation was encountered, even extending over the great vessels (Figures 1, 2). Anteriorly, epicardial dissection was performed and limited drainage of the subepicardial hematoma was obtained. Arterial blood pressure increased gradually. The site of active bleeding could not be located, but there were multiple foci of epicardial extravasation. The integrity of cardiac layers was heavily destroyed; therefore neither identification of the target vessels nor their surgical revascularization (by means of cardiopulmonary bypass or beating heart technique) could not be achieved. The multiple foci of epicardial bleeding were controlled with biological glue administration. Any hemodynamic complication was not encountered in the postoperative course. Serial control echocardiographic evaluations in the postoperative period revealed mild-moderate tricuspid valve regurgitation with a pulmonary artery pressure of 50mmHg. Ejection fraction of 50% that was not different from preoperative studies. Residual pericardial effusion was not detected in any of these echocardiographic evaluations. Electrocardiography did not reveal any acute ischemic event. Following two days of weaning from the mechanical ventilation, the patient was extubated but he was supported with continuous positive airway pressure support (CPAP) in order to achieve adequate par-



FIGURES 1, 2: Massive subepicardial hematoma dissecting the layers of the heart.

(See color figure at

<http://www.turkiyeklinikleri.com/journal/journal-of-medical-research-case-reports/1300-0284/>)

tial oxygen and carbon dioxide pressures at arterial blood gas analysis. At the sixth postoperative day, the patient aspirated food and he was re-intubated. Although antibiotic treatment was urgently managed, infiltration at the chest x-ray gradually increased and the patient died at the fifteenth day of surgery due to aspiration pneumonia, acute respiratory distress syndrome and sepsis.

DISCUSSION

Cardiac perforation and cardiac tamponade are rare complications of PCI. The incidence of this complication is reported to be less than 0.1% in a large patient population of Shen X et al.³ Subepicardial hematoma formation is an extremely rare complication of PCI. Although this complication is reported in patients with prior coronary artery bypass grafting (CABG), as in our case, it can be encountered in non-CABG patients. Rahman et al. reported only two such cases of subepicardial hematoma in non-CABG patients in literature up to 2008.²

In our patient, although bedside echocardiography did not reveal pericardial tamponade, we

proceeded with urgent surgery in order to provide hemodynamic stability. Subepicardial hematoma was drained immediately in order to prevent further dissection of cardiac layers. Considering the non-critical atherosclerotic lesions, only the control of bleeding was achieved without surgical revascularization of the target vessels.

Typical echocardiographic findings such as massive pericardial effusion or tamponade may not be encountered in all mechanical complications after PCI. Importance of autotransfusion is especially mentioned in some cases with coronary perforation.⁴ In order to reduce the risk of such a complication, careful patient selection for coronary interventions and crossing of the totally occluded coronary lesions with guide wires is critical.⁵

REFERENCES

1. Rogers JH, Lasala JM. Coronary artery dissection and perforation complicating percutaneous coronary intervention. *J Invasive Cardiol* 2004;16(9):493-9.
2. Rahman N, Sharif H, Jafari FH. Intramyocardial hematoma after coronary perforation during percutaneous coronary intervention--anticipated and treated. *J Invasive Cardiol* 2008;20(7):E224-8.
3. Shen X, Fang Z, Hu X, Liu Q, Zhou T, Tang J, et al. [Cardiac perforation and tamponade in percutaneous cardiac intervention]. *Zhong Nan Da Xue Xue Bao Yi Xue Ban* 2011;36(1):74-9.
4. Alıcı G, Ozkan B, Esen AM. A case of double coronary perforations and tamponade during left main percutaneous coronary intervention and treatment with stenting and autotransfusion. *Turk Kardiyol Dern Ars* 2013;41(1):68-71.
5. Furushima H, Matsubara T, Tamura Y, Yamazoe M, Konno T, Ida T, et al. Coronary artery perforation with subepicardial hematoma. *Cathet Cardiovasc Diagn* 1997;41(1):59-61.