

Renal Angiomyolipoma with Vein Invasion: Case Report

Ven İnvazyonu Birlikteliği Olan Renal Anjiyomiyolipoma

Engin KAYA,^a
Nuri YİĞİT,^b
Sercan YILMAZ,^a
Bilal Fırat ALP,^a
Yıldırım KARSLIOĞLU,^b
İbrahim YILDIRIM^a

Departments of
^aUrology,
^bPathology,
Gülhane Military Medical Academy,
Ankara

Geliş Tarihi/Received: 21.02.2014
Kabul Tarihi/Accepted: 30.04.2014

Yazışma Adresi/Correspondence:
Sercan YILMAZ
Gülhane Military Medical Academy,
Department of Urology, Ankara,
TÜRKİYE/TURKEY
drsercanyilmaz@gmail.com

ABSTRACT Angiomyolipoma (AML) accounts for 0.3-3% of all renal tumors. It can be solitary or multiple, unilateral or bilateral. Its benign and malignant forms were described. Benign (classic) AML is frequently a sporadic lesion and known as the most common benign mesenchymal neoplasm of the kidney. It is usually seen as a solitary mass in middle-aged people, and four times more common in females than males. Surgical intervention is curative. Patient's age, comorbidities, and other related factors should be taken into account for the type of surgery. Here, we summarize a 50-year-old woman who is treated by laparoscopic radical nephrectomy and histopathological findings were consistent with a typical AML. However, venous invasion, a rare but possible behavior of AMLs was detected.

Key Words: Angiomyolipoma; renal veins

ÖZET Anjiyomiyolipoma (AML) bütün böbrek tümörlerinin %0,3-3'ünü oluşturur. Soliter veya mutipl, unilateral veya bilateral olabilmektedir. AML'nin benign ve malign formları tanımlanmıştır. Benign (klasik) AML, nadir görülen ve sporadik olan formudur ve genellikle böbreğin benign mezenchimal hücreli tümörü olarak bilinir. Genelde orta yaş insanlarda soliter olarak gözlenir ve bu kadın erkek oranı 4:1'dir. Benign AML'nin cerrahisi küratiftir ancak hasta yaşı, komorbiditeler ve diğer ilişkili faktörler cerrahinin tipini belirlemede önem arz eder. Biz, bu yazımızda laparoskopik radikal nefrektomi ile tedavi edilen, histopatolojik değerlendirme sonucu ven invazyonunun eşlik ettiği nadir ancak muhtemel bir patoloji olan klasik AML olarak raporlanan 50 yaşında kadın olguyu sunuyoruz.

Anahtar Kelimeler: Anjiyomiyolipom; renal venler

Türkiye Klinikleri J Urology 2014;5(1):25-8

Angiomyolipoma (AML) accounts for 0.3-3% of all renal tumors.¹ It can affect both kidneys at the same time, and can be solitary or multiple. Although most AMLs have an obviously benign clinical course, its malignant forms were also reported. Benign (classic) AML is frequently a sporadic lesion and regarded as the most common benign mesenchymal neoplasm of the kidney. It is usually seen as a solitary mass in the middle-aged people, affecting females four times more common than males. Conversely, malignant (epithelioid) AML generally presents as multiple lesions in all age groups with no gender predilection.^{2,3}

Kidney is the most common site of AML but it may occur in other sites, such as liver and retroperitoneum. AML is considered as a member of the PEComa family because of its hypothesized origin of the “perivascular epithelioid cells”.⁴ These tumors are composed of the variable amounts of blood vessels as well as mature adipose and smooth muscle tissues. It is possible to observe cells having epithelioid morphology, too.⁵ The tumor is generally well demarcated from the surrounding tissues and structures, and may have hemorrhagic or cystic changes.

Although classic AML is considered entirely benign with practically no potential of metastatic spread, rarely, a few of them surprisingly were reported to be able to invade perirenal adipose tissue, regional lymph nodes, renal vein, and even inferior vena cava.⁶⁻¹⁰ On the other hand, malignant form of AML is a highly aggressive neoplasm which is often seen in the patients with tuberous sclerosis (TS).⁸

Ultrasonography (US), computed tomography (CT) and magnetic resonance imaging (MRI) are the best techniques to detect the AML because of its characteristic fat-rich appearance. In non-enhanced thin-cut CT series, the intrarenal fatty lesion valued of -20 or less Hounsfield Units (HU) is considered the diagnostic hallmark.¹¹

CASE REPORT

A 50-year-old woman presented with a 4-year history of right flank pain has referred to our outpatient clinic. Her systemic physical examination was unremarkable. She had no other significant medical history. Routine blood, urine, and biochemistry tests were in normal range. A urinary US revealed a hyperechoic, lobulated, solid lesion within the upper half of the right kidney measuring 77x59 mm in dimension. Abdominal CT scan showed that the well-demarcated lesion was extending up to the right-liver lobe, preserving the normal anatomy of the renal veins (Figure 1). Because of the radiological report was not exclusively suggestive of a benign tumor, the patient underwent a laparoscopic radical nephrectomy to prevent the possible tumor spillover and reduce the post-op complication rate.

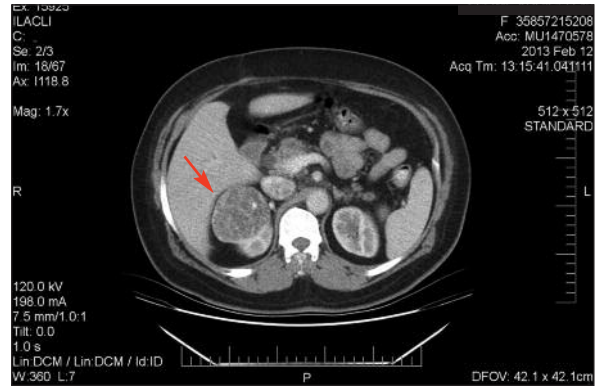


FIGURE 1: A 65x43 mm hypodense mass in the upper pole of the right kidney is seen.

Grossly, the kidney was measured as 15x7x6 cm in the right radical nephrectomy specimen. A midsection from the upper pole through the hilum, revealed a gray-yellow colored, well demarcated solid tumor measuring 7x5.5x5 cm in dimension. On close inspection, it was noted that there were some tiny extensions to the perirenal adipous tissue, renal sinus and hilar soft tissues sparing the adrenal gland. Additionally, a 0.5 cm nodule, which was distinctly separated from the main tumor, in the peripelvic hilar soft tissue was also detected and sampled.

Microscopically, all the sections showed admixture of the variable sized blood vessels surrounded with smooth muscle cells as well as mature adipose tissue component. The amount of adipose tissue was somewhat less than usually expected, which might, we think, be preventing to recognize the lesion radiologically prior to the surgery (Figure 2A, B). Smooth muscle cells had brightly eosinophilic ample cytoplasm and round vesicular nuclei with small distinct nucleoli. There was no observed atypia, increased mitotic activity or necrosis, which are considered suggestive to the malignancy. The second lesion in the hilar part, which was described in macroscopic inspection, had same morphology as well. Yet, it was surprisingly observed that the nodule itself was consisted a mass of tumor permeating the vascular lumina of the branch of renal vein and covered by clearly visible endothelial lining (Figure 3A, B). Perirenal, renal vascular and ureteral surgical margins were all negative.

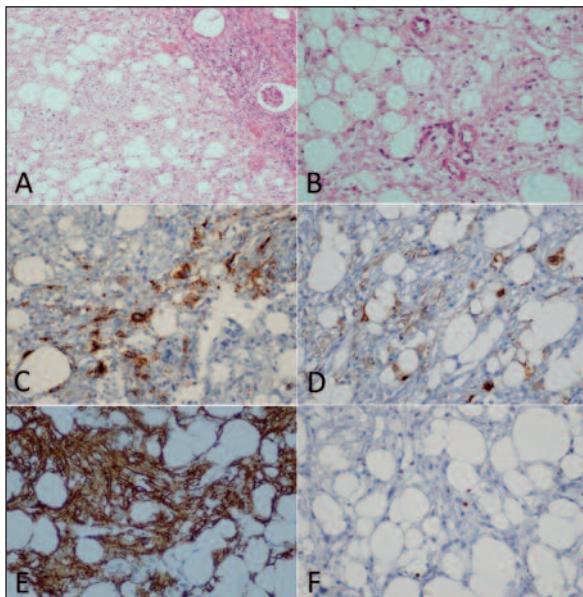


FIGURE 2: **A)** Well-demarcated tumor and the neighboring renal parenchyma (HE, x100), **B)** Admixture of the blood vessels surrounded by smooth muscle cells and the adipous tissue (HE, x200). Immunohistochemical profile of the tumor: **C)** HMB45 positivity (x200), **D)** Melan-A (x200), and **E)** SMA (x200) immunoreactivity, **F)** Ki-67 proliferation index: 3-4% (x200).

(See color figure at

<http://www.turkiyeklinikleri.com/journal/journal-of-medical-research-case-reports/1300-0284/>)

Immunohistochemically, non-fatty areas of both the main tumor and the satellite nodule were focally positive for HMB45 and Melan-A, and distinctly positive for SMA (Figure 2C-E). Interestingly, the tumor showed aberrant expression of the RCC antibody. The Ki-67 proliferation index was low (3-4%) (Figure 3F). In the satellite hilar nodule, which was actually a tumor thrombus, the venous invasion was confirmed by using anti-CD34 and anti-CD31, both of which revealed the surrounding endothelial lining of this intravascular tumor extension (Figure 3C, D).

A diagnosis of classic AML with venous invasion was rendered based on the morphological and immunohistochemical findings. Then, the patient was scanned with colored Doppler US and thoracic CT for possible gross vein invasions and pulmonary metastases. There was no evidence of thrombi in vena cava or heart chambers, and thoracic CT did not reveal any lesion consistent with metastasis. The patient has been following-up for 5 month with no evidence of disease, and the long term follow-up plan was scheduled.

DISCUSSION

Although AML is relatively infrequent, it is still the most common mesenchymal tumour of the kidney. In surgical series, 50% of them are sporadic and the remaining ones are known to be associated with TS.¹² The sporadic forms tend to be unilateral and larger, as in our case. Generally speaking, AMLs are easy to be recognized in CT scans because of their fat component giving them a typical appearance. Detecting fat densities (-70 to -30 HU) in a solitary and well-demarcated renal mass is highly suggestive for a diagnosis of classical AML. In 5% of the cases, fat component can be minimal or absent which causes confusion for discriminating from the other neoplasms including renal cell carcinomas.

AML infrequently may cause pulmonary embolus as well as invasion of intrarenal venous system, the renal vein, and the vena cava.¹³ Also, epithelioid AML and renal cell carcinoma (RCC) can invade to the venous system and rare RCCs include macroscopic fat components, additionally. Therefore, with the radiological workups, the feature of venous involvement of AML at any vascular level can not be distinguished from those of the epithelioid AML and RCC and eventually can be misinterpreted as evidence of malignancy. For such

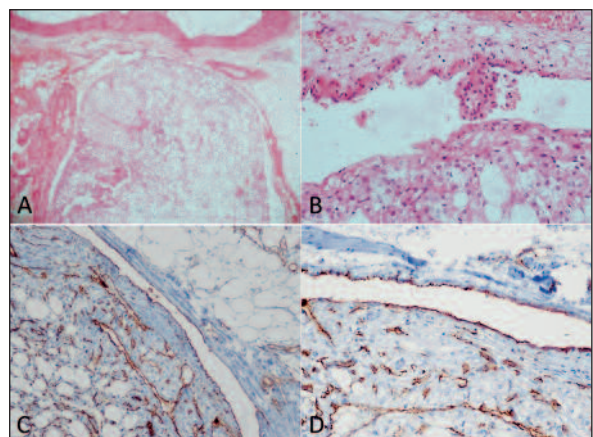


FIGURE 3: **A)** Sections from the satellite nodule in the hilar region (HE, x40), **B)** Permeation of the tumor into the vessel lumen (HE, x400), **C, D)** The CD31 positivity on the surrounding endothelial cells in the lumen of the branch of the renal vein (x200-x400).

(See color figure at

<http://www.turkiyeklinikleri.com/journal/journal-of-medical-research-case-reports/1300-0284/>)

conditions, the definite diagnosis is made by histopathologic examination.¹²

The treatment of AML, especially for the tumors greater than 4 cm, is surgical removal. Nephron-sparing surgery has always to be considered when AML is suspected preoperatively. Surgical treatment options depend on the factors related to the patient's medical condition and/or the anatomical features such as being unilateral vs. bilateral, being unifocal vs. multifocal. Surgery options include open or laparoscopic/robotic partial/radical nephrectomy.^{2,14,15} In our case we performed laparoscopic radical nephrectomy. After the surgery, the patient had an uneventful course.

Histopathologically, classic AML is an easily recognizable tumor due to the typical morphology. In some cases, there may be some degree of cytological atypia. Additionally, the smooth muscle cell component may show different morphology, from spindle to epithelioid. Rarely, invasion to the renal

capsule, perirenal adipose tissue, renal veins, and even inferior vena cava can be encountered which are in quietly similar fashion with the epithelioid ones and RCC. However, none of them does not necessarily to reflect a malignant behaviour. Yet, these features might cause confusion and when observed, it should be discriminated from leiomyosarcomas, dedifferentiated liposarcomas or renal cell carcinomas with the help of cytologic specifications. Epstein et al. noted that the diagnosis of malignant AML could only be established if at least three of four suggested criteria are satisfied: i) High percentage of atypical epithelioid cells, ii) increased mitotic activity, iii) atypical mitotic figures, and iv) necrosis.¹⁶

Although rare, venous invasion of the AML is reported in the literature, as in our case. However, it is obvious that we need ongoing research to learn the true significance of this finding, because it does not always mean a malignant clinical course.

REFERENCES

- Steiner MS, Goldman SM, Fishman EK, Marshall FF. The natural history of renal angiomyolipoma. *J Urol* 1993;150(6):1782-6.
- Nelson CP, Sanda MG. Contemporary diagnosis and management of renal angiomyolipoma. *J Urol* 2002;168(4 Pt 1):1315-25.
- Park HK, Zhang S, Wong MK, Kim HL. Clinical presentation of epithelioid angiomyolipoma. *Int J Urol* 2007;14(1):21-5.
- Martignoni G, Pea M, Reghellin D, Zamboni G, Bonetti F. PComas: the past, the present and the future. *Virchows Arch* 2008;452(2):119-32.
- Eble JN. Angiomyolipoma of kidney. *Semin Diagn Pathol* 1998;15(1):21-40.
- Baert J, Vandamme B, Scirot R, Oyen R, van Poppel H, Baert L. Benign angiomyolipoma involving the renal vein and vena cava as a tumor thrombus: case report. *J Urol* 1995;153(4):1205-7.
- Dodds LJ, Mishriki SF, Miller S. Peripheral renal angiomyolipoma with extension into the renal vein. *Aust N Z J Surg* 2000;70(1):78-9.
- Wilson SS, Clark PE, Stein JP. Angiomyolipoma with vena caval extension. *Urology* 2002;60(4):695-6.
- Islam AH, Ehara T, Kato H, Hayama M, Kashiwabara T, Nishizawa O. Angiomyolipoma of kidney involving the inferior vena cava. *Int J Urol* 2004;11(10):897-902.
- Blick C, Ravindranath N, Muneer A, Jones A. Bilateral renal angiomyolipomas with invasion of the renal vein: a case report. *Scientific World Journal* 2008;8:145-8. doi: 10.1100/tsw.2008.29.
- Simpfendorfer C, Herts BR, Motta-Ramirez GA, Lockwood DS, Zhou M, Leiber M, et al. Angiomyolipoma with minimal fat on MDCT: can counts of negative-attenuation pixels aid diagnosis? *AJR Am J Roentgenol* 2009;192(2):438-43.
- Price EB Jr, Mostofi FK. Symptomatic angiomyolipoma of the kidney. *Cancer* 1965;18:761-74.
- Shinohara N, Kotegawa M, Kiyohara Y, Kato I, Iwamoto H, Jinnouchi J, et al. [An autopsy case of pulmonary embolism due to renal angiomyolipoma in an elderly woman]. *Nihon Ronen Igakkai Zasshi* 1999;36(6):420-4.
- Christiano AP, Yang X, Gerber GS. Malignant transformation of renal angiomyolipoma. *J Urol* 1999;161(6):1900-1.
- Lienert AR, Nicol D. Renal angiomyolipoma. *BJU Int* 2012;110(Suppl 4):25-7.
- Brimo F, Robinson B, Guo C, Zhou M, Latour M, Epstein JI. Renal epithelioid angiomyolipoma with atypia: a series of 40 cases with emphasis on clinicopathologic prognostic indicators of malignancy. *Am J Surg Pathol* 2010;34(5):715-22.