

CASE REPORT

DOI: 10.5336/caserep.2021-83873

Unexpected Electroneurography Findings in the Forearms Accompanying Carpal Tunnel Syndrome: Bilateral Martin-Gruber Anastomosis

 Ayfer ERTEKİN^a^aClinic of Neurology, Private Siirt Hayat Hospital, Siirt, TURKEY

ABSTRACT Carpal tunnel syndrome is a clinical syndrome of numbness, tingling, burning, and/or pain on hands associated with localized compression of the median nerve at the wrist. The common connection between the median and ulnar nerves, called Martin-Gruber anastomosis (MGA), may cause changes in electroneurography findings in the forearms. MGA is asymptomatic and usually diagnosed incidentally during the neurophysiological assessment of the median and ulnar nerves. The presence of MGA is not a rare condition and thus we have to keep this fact in mind in routine clinical and neurophysiological examinations to avoid some diagnostic and therapeutic mistakes.

Keywords: Martin-Gruber anastomosis; carpal tunnel syndrome; electroneurography

Martin-Gruber anastomosis (MGA) is an asymptomatic anatomic variation in which the hand muscles are innervated together with the connection of the median nerve to the ulnar nerve in the forearm and its prevalence ranges from 3.3% to 40%.^{1,2} The crossing usually occurs in the forearm. MGA is diagnosed incidentally by detecting significant differences in motor amplitude recorded from hand muscles during electrophysiological nerve conduction studies of median and ulnar nerves.³ MGA is bilateral in approximately 10-40% of cases.⁴ Although there are many studies in the literature investigating the prevalence of Martin-Gruber anomaly, there are only a few studies on the prevalence of this anomaly in patients with carpal tunnel syndrome (CTS). The study conducted by Iyer, Fenichel and Simonetti can be given as an example of such studies.^{5,6} It was reported that the prevalence of Martin-Gruber anomaly in patients with CTS is 54% to 26%.⁷ The partial comorbidity of CTS and Martin-Gruber anomaly may change the evaluation of electrodiagnostic tests and the treatment plan of CTS.⁸

Thorough comprehensive information of the anatomical variations of the median-ulnar nerve in the forearm and its locations is very important for the correct diagnosis of neuropathy. Hand, orthopedic and brain surgeons should avoid unnecessary surgical procedures with awareness of these anatomical variations to explain the paradoxical motor and sensory losses in cases. In this way, surgeons can offer a more appropriate treatment option with a more accurate approach in hand and forearm nerve compression and/or neuropathies. The purpose of the present case report is to draw attention to this phenomenon.

CASE REPORT

A 39-year-old right-handed housewife applied to our clinic with complaints of tingling in both hands radiating to the palm and numbness in fingers of both hands. There was pain accompanying paresthesia on the first three fingers and the radial side of the ring finger of both hands especially at night, weakness of left thumb abduction and opposition and reduced hand sensation in fingers with median nerve innerva-

Correspondence: Ayfer ERTEKİN

Clinic of Neurology, Private Siirt Hayat Hospital, Siirt, TURKEY

E-mail: ayfertekin1976@gmail.com



Peer review under responsibility of Türkiye Klinikleri Journal of Case Reports.

Received: 15.Apr.2021

Received in revised form: 06.Jul .2021

Accepted: 29.Jul.2021

Available online: 11 Aug 2021

2147-9291 / Copyright © 2021 by Türkiye Klinikleri. This is an open access article under the CC BY-NC-ND license (<http://creativecommons.org/licenses/by-nc-nd/4.0/>).

tion. In the history and physical examination, there were no findings suggestive of cervical radiculopathy (such as the absence of neck pain, normal C6-C7 innervation muscle activations and normal reflexes). The physical examination revealed atrophy of the left thenar muscle, thumb abduction, and weakening in opposition. The bilateral Phalen and Tinel tests were positive. Bilateral radial artery pulses were normal when the arm was positioned in abduction and external rotation. Upper extremity reflexes were normal. Loss of sensation was prominent in the index and ring fingers and the radial side of the thumb of both hands.

In the present case, anamnesis and physical examination could have been suggestive of bilateral CTS, even before nerve conduction and electromyography (EMG) studies were performed in the upper extremity.

Electrodiagnostic findings recorded with the Nihon Kohden-Neuropack-MEB 9102k (Nihon kohden, Japonya), 2015 device were as follows (forearm nerve conduction studies were recorded in supramaximal):

1. The motor amplitude of the left median nerve recorded from the antecubital fossa was higher than compound muscle action potential (CMAP) at the wrist.

2. Initial (downward) positive deviation of the left median CMAP in the antecubital fossa.

3. Unexpectedly high left median nerve conduction velocity (100.0 m/s) between the antecubital fossa and the wrist.

4. In motor nerve conduction studies, prolonged distal latency of the left median nerve recorded from abductor pollicis brevis (APB) muscle (L, 8.24 ms;) and low CMAP amplitude (L, 1.09 mV) (reference value 4 mV), and fibrillation potentials and positive sharp waves in spontaneous activity recorded from the left APB muscle (Figure 1).

5. Prolonged distal latency of the right median nerve recorded from the APB muscle (R, 4.44 ms), low CMAP amplitude (R, 3.880 mV) and normal velocity (53.6 m/s).

6. The right median motor amplitude recorded at the wrist level was lower than the amplitude recorded from the antecubital fossa (Figure 2).

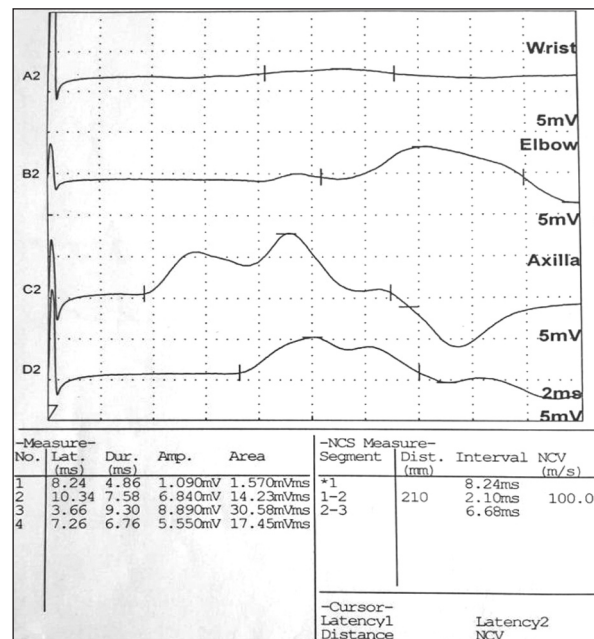


FIGURE 1: Martin-Gruber anastomosis and left carpal tunnel syndrome. The recording from abductor pollicis brevis of the left median motor nerve study stimulated from the antecubital fossa (B2) and the wrist (A2). Prolonged distal latency at the wrist stimulation site. In the antecubital fossa region, a positive dip (scope) and an unexpectedly high conduction velocity due to some median fibers stimulated from the antecubital fossa bypassing the carpal tunnel via the anastomosis. Slightly higher amplitude at the proximal stimulation site. The anastomosis recorded from the thenar muscle (abductor pollicis brevis) by stimulating the left ulnar nerve at the wrist (C2) and below-elbow site (D2).

7. When the ulnar nerve is stimulated from the bilateral APB muscle, the ulnar motor amplitude at the wrist was higher than at the lower elbow region [(Ulnar R; wrist: 12.51 mV, below elbow site: 8.04 mV, Ulnar L; wrist: 8.89 mV, below elbow site: 5.55 mV)].

8. In sensory nerve conduction studies, the sensory nerve action potential (SNAP) could not be obtained when recorded from the left median 2nd finger. Low SNAP, slow conduction velocity, and prolonged distal latency were detected in the right median 2nd finger.

9. In motor nerve conduction studies recorded from bilateral abductor digiti mini muscles, [ulnar L; wrist: 15.49 mV, below elbow site: 11.42 mV; median L; wrist: 0.51 mV, antecubital fossa: 2.59 mV; ulnar R; wrist: 17.17 mV, below elbow site: 16.69; median R; wrist: amplitude not measured, antecubital fossa: 1.40 mV] (Figure 3, Figure 4).

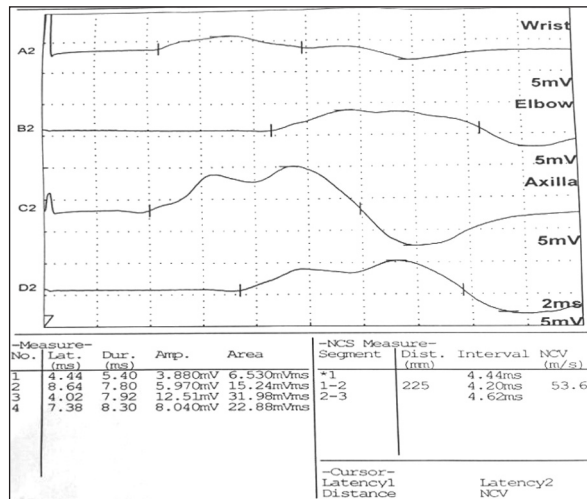


FIGURE 2: Martin-Gruber anastomosis and right carpal tunnel syndrome. The recording from abductor pollicis brevis of the right median motor nerve study stimulated from the antecubital fossa (B2) and the wrist (A2). Higher amplitude recorded in the antecubital fossa (B2) compared to the wrist site (A2). Prolonged right median DL (4.44 ms) and low compound muscle action potential (CMAP) amplitude (3.88 mV) (reference value 4 mV) with normal conduction velocity (53.6 m/sec) of the right median motor nerve. The anastomosis recorded at the wrist (C2) and below-elbow site (D2) by stimulating the left ulnar nerve. Higher CMAP amplitude recording at the wrist (C2) than at the below-elbow site (D2).

10. The ulnar and radial motor and sensory nerve transmissions were normal.

All electroneurography results showed bilateral MGA recorded from the thenar and hypothenar muscles in both forearms accompanying right moderate and left severe CTS with an unexpectedly high median motor velocity (Table 1). The patient was treated with local depomedrol to relieve her symptoms.

A written consent was obtained from the patient for the presentation of this case.

DISCUSSION

The coexistence of MGA and CTS is not uncommon, and should be detected in forearm nerve conduction studies.⁹ Therefore, electrophysiological findings in MGA accompanied by CTS should be well known. This condition can be detected as follows:

1) Detection of downward (positive deflection) deviation of the median nerve recorded from the thenar muscle when it is stimulated from the antecubital region, and often 2) Unexpected increase in median motor nerve conduction velocity accompanying

the condition. If the median nerve is trapped at the wrist level, the median motor conduction velocity slows down and the distal latency is prolonged. If there is MGA accompanying CTS, by stimulation of

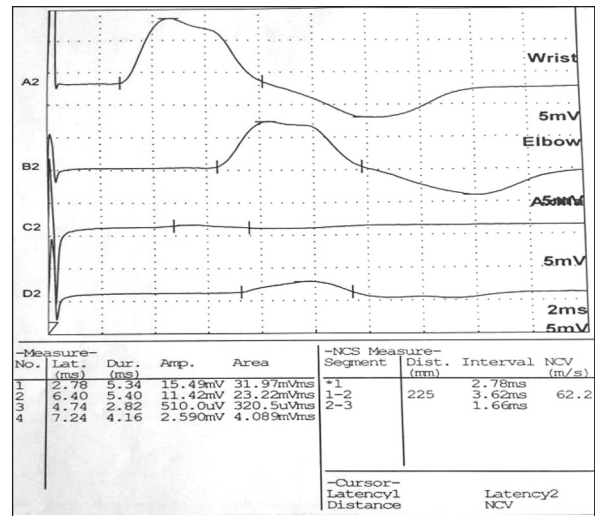


FIGURE 3: Martin-Gruber anastomosis and pseudo-conduction block of the left ulnar nerve in the forearm. Higher compound muscle action potential (CMAP) amplitude recording of the left ulnar nerve (obtained from the abductor digiti mini muscle) at the wrist (A2) compared to the below-elbow site (B2). Demonstrating anastomosis with a lower CMAP amplitude recording of the left median nerve at the wrist (C2) compared to the antecubital fossa (D2).

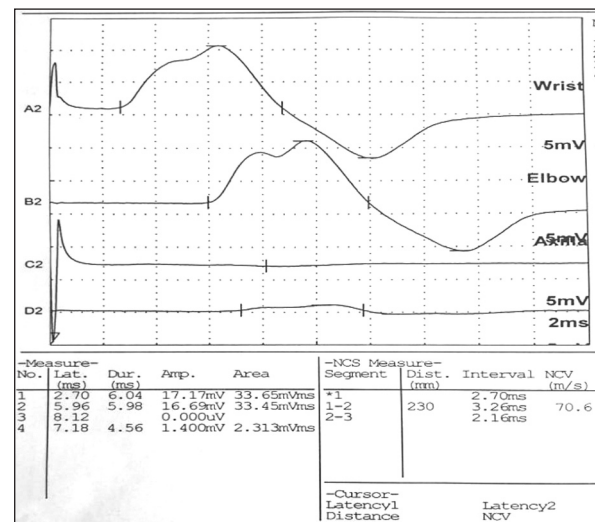


FIGURE 4: Martin-Gruber anastomosis recorded from abductor digiti mini muscle (abd) during the right ulnar motor study. Higher compound muscle action potential amplitude recording of the right ulnar nerve (obtained from the abd) at the wrist (A2) compared to the below-elbow site (B2). There is no potential at the wrist level (C2) recorded from the hypothenar muscle (abd) of the right median nerve. The amplitude obtained from the antecubital fossa (D2) region is approximately equal to the wrist and below-elbow amplitude difference of the ulnar nerve.

TABLE 1: Motor nerve conduction study.

Site	Latency (ms)	Amplitude (Mv)	Area Mvms	Distance (mm)	NCV (m/s)
Median, L					
Wrist (A2)	8.24	1.09	1.570		
Antecubital fossa (B2)	10.5	6.84	14.23	210	100.0
Wrist (C2)	3.66	8.89	30.58		
Below-elbow site (D2).	7.26	5.55	17.45		
Median, R					
Wrist (A2)	4.44	3.88	6.530		
Antecubital fossa (B2)	8.64	5.97	15.24	225	53.6
Wrist (C2)	4.02	12.51	31.98		
Below-elbow site (D2).	7.38	8.04	22.88		
Ulnar, R					
Wrist (A2)	2.70	17.17	33.65		
Below-elbow site (B2)	5.96	16.69		230	70.6
Wrist (C2)	8.12	0.00			
Antecubital fossa (D2)	7.18	1.40			
Ulnar, L					
Wrist (A2)	2.78	15.49	31.97		
Below-elbow site (B2)	6.40	11.42	23.22	225	62.2
Wrist (C2)	4.74	510uv	320uv		
Antecubital fossa (D2)	7.24	2.59	4.08		
Sensory nerve conduction study					
Site	Latency (ms)	Amplitude	Area	Distance (ms)	NCV (m/s)
Median, L 2nd finger					
Wrist	-	-	-		-
Median, R 2nd finger					
Wrist	3.04	7.70uv	0.91	110	36.2

Bilateral Martin-Gruber anastomosis recorded from the thenar and hypothenar muscles in both forearms accompanying right moderate and left severe carpal tunnel syndrome with an unexpectedly high median motor velocity (motor and sensory nerve conduction studies in both forearms).
NCV: Nerve conduction velocity.

the median nerve from the antecubital fossa, some of the median fibers join the ulnar nerve in the forearm, bypass the carpal tunnel and innervate the hand thenar muscles. In addition, the anastomotic fibers of the median nerve stimulated from the proximal bypassing the tunnel reaches the thenar muscles unexpectedly fast, which significantly shortens the proximal-distal latency difference of the median nerve, even in the presence of very heavy CTS, proximal latency may exceed distal latency. Except for MGA, motor conduction velocity of the median nerve in the forearm is not expected to exceed 70 to 75 m/s. Any speed faster than this suggests the possibility of an MGA with CTS, particularly with a positive deviation in proximal stimulation. In addition, during routine median motor nerve conduction

studies examining the thenar muscles, a characteristic pattern is observed: higher median CMAP amplitude in the antecubital fossa than at the wrist. This situation should exclude technical errors such as sub-maximal stimulation at the wrist level, overstimulation of the median nerve in the antecubital fossa, and co-stimulation of the ulnar nerve, and then should suggest an MGA with cross fibers innervating the thenar muscles. If an MGA is present, the ulnar nerve CMAP amplitude will be significantly lower at the below elbow site than at the wrist. The amplitude differences between these potentials approximate to the contribution of cross fibers. If the MGA is not recognized, a false transmission block perception may occur along the elbow. An MGA can rarely cause a misdiagnosis of ulnar neuropathy. These are known

as abnormal nerve innervation of the forearm. Several of these abnormal innervations of the peripheral nerve are usually seen in the EMG laboratory. It is very important for any electroneuromyography device to be able to identify them during routine nerve conduction studies. If these anatomical variations in the forearm are not well recognized, they can be confused with serious technical abnormalities or with actual nerve damage, and this can lead to irreversible and redundant surgical procedures.¹⁰

In conclusion, knowing the presence, presentation types and topography of anastomoses between the median and ulnar nerves in the forearm is extremely important for the correct diagnosis of neuropathies, as in our case.

Source of Finance

During this study, no financial or spiritual support was received neither from any pharmaceutical company that has a direct connection with the research subject, nor from a company that provides or produces medical instruments and materials which may negatively affect the evaluation process of this study.

Conflict of Interest

No conflicts of interest between the authors and / or family members of the scientific and medical committee members or members of the potential conflicts of interest, counseling, expertise, working conditions, share holding and similar situations in any firm.

Authorship Contributions

This study is entirely author's own work and no other author contribution.

REFERENCES

1. Leibovic SJ, Hastings H 2nd. Martin-Gruber revisited. *J Hand Surg Am.* 1992;17(1):47-53. [[Crossref](#)] [[PubMed](#)]
2. Rodríguez-Niedenführ M, Vazquez T, Parkin I, Logan B, Sa-udo JR. Martin-Gruber anastomosis revisited. *Clin Anat.* 2002;15(2):129-34. [[Crossref](#)] [[PubMed](#)]
3. Saba EKA. Electrophysiological study of Martin-Gruber anastomosis in a sample of Egyptians. *Egyptian Rheumatology & Rehabilitation.* 2017;44:153-8. [[Crossref](#)]
4. Ayramlou H, Najmi S, Yazdchi M, Naeimi M, Pourabolghasem S. Study of prevalence of Martin-Gruber anomaly in patients with carpal tunnel syndrome. *Int J Chronic Dis Ther.* 2015;1(2):5-8. [[Crossref](#)]
5. Iyer V, Fenichel GM. Normal median nerve proximal latency in carpal tunnel syndrome: a clue to coexisting Martin-Gruber anastomosis. *J Neurol Neurosurg Psychiatry.* 1976;39(5): 449-52. [[Crossref](#)] [[PubMed](#)] [[PMC](#)]
6. Simonetti S. Electrophysiological study of forearm sensory fiber crossover in Martin-Gruber anastomosis. *Muscle Nerve.* 2001;24(3):380-6. [[Crossref](#)] [[PubMed](#)]
7. Oh SJ. *Electrophysiology.* 3rd ed. USA: Lippincott Williams & Wilkins; 2003.
8. Erdem HR, Ergun S, Erturk C, Ozel S. Electrophysiological evaluation of the incidence of martin-gruber anastomosis in healthy subjects. *Yonsei Med J.* 2002;43(3):291-5. [[Crossref](#)] [[PubMed](#)]
9. Preston DC, Shapiro BE. Chapter 17: Median neuropathy at the wrist. *Electromyography and Neuromuscular Disorders.* 3rd ed. British Library Cataloguing in Publication Data; 2013. p.267-88. [[Crossref](#)]
10. Preston DC, Shapiro BE. Chapter 7: Anomalies innervations. *Electromyography and Neuromuscular Disorders.* 3rd ed. British Library Cataloguing in Publication Data; 2013. p.62-70. [[Crossref](#)]