

# A Comparison of Pancreatic Pseudocysts with True Pancreatic Cysts According to Endosonographic Criteria (A Six-Year Retrospective Analysis)

## Endosonografik Kriterlere Göre Pankreatik Psödokistlerin Gerçek Pankreatik Kistlerle Karşılaştırılması (Altı Yıllık Retrospektif Veri Analizi)

Memduh ŞAHİN,<sup>a</sup>  
Tarkan KARAKAN,<sup>b</sup>  
Mehmet CİNDORUK<sup>b</sup>

<sup>a</sup>Clinic of Gastroenterology  
Mersin State Hospital, Mersin  
<sup>b</sup>Department of Gastroenterology,  
Gazi University Faculty of Medicine,  
Ankara

Geliş Tarihi/Received: 01.08.2015  
Kabul Tarihi/Accepted: 25.03.2016

Yazışma Adresi/Correspondence:  
Memduh ŞAHİN  
Mersin State Hospital,  
Clinic of Gastroenterology, Mersin,  
TÜRKİYE/TURKEY  
memsahinsahin@hotmail.com

**ABSTRACT Objective:** During the past years, endoscopic ultrasound (EUS)-guided fine-needle aspiration (FNA) has become an important tool in cyst therapy and tissue sampling. In this retrospective analysis, the primary objective was to determine the efficacy of EUS guided FNA for diagnosis of pancreatic pseudocysts (PP) and true cysts. The secondary aim was to evaluate the size and location of the cysts. **Material and Methods:** Eighty-three patients with pancreatic cysts and pseudocysts were retrospectively identified from the database of Gazi University Department of Gastroenterology. Size of the cysts and available data on fine needle aspiration and surgical aspiration were also recorded. **Results:** According to EUS criteria, 48 patients (57.8%), 24 female and 24 male subjects with PP and 35 (42.2%) patients (24 female and 11 male) with cystic lesions (totally 83 patients, 48 female and 35 male) were enrolled in the study. The size of the cysts in the pseudocyst group was significantly greater than that of the simple cysts. There was no difference between the two groups in terms of patients age. There was also no difference between the two study groups in terms of location ( $p=0.404$ ). The most common location for both cysts was the head of the pancreas. Normal cytology was the most common finding among cytological results of fine needle aspiration in the both groups. Bacterial growth was detected in one sample and fungal culture was positive in another in the PP group. One of the samples showed atypical cells and another demonstrated mucinous cells in the same subgroup. There were 4 (11.4%) cases with mucinous cystic neoplasm and one case with cystadenocarcinoma in the true cyst group. **Conclusion:** Cysts of the pancreas have some characteristic properties that can be differentiated with EUS guidance.

**Key Words:** Biopsy, fine-needle; endosonography; pancreas; cysts

**ÖZET Amaç:** Son yıllarda, Endoskopik Ultrason (EUS) eşliğinde yapılan ince iğne aspirasyon işlemi (FNA) kist tedavisi ve kistin içeriğinden örnek alınmasında önemli yer tutmaya başlamıştır. Yaptığımız bu retrospektif analizde EUS yolu ile ince iğne biyopsisinin pankreatik kist ve psödokistlerdeki tanılabilirliği incelenmiştir. İkincil amaç olarak psödokistlerin ve gerçek kistlerin boyut ve lokalizasyon açısından farklılığı analiz edilmiştir. **Gereç ve Yöntemler:** Retrospektif olarak elde edilen ve psödokist ile gerçek pankreatik kist tanısı alan 83 hastanın bilgileri Gazi Üniversitesi Gastroenteroloji Bölümü veritabanından elde edilmiştir. Bu veriler ile kist boyutları ve sonradan elde edilen ince iğne aspirasyon ve cerrahi patolojik sonuçlar değerlendirilip analiz edilmiştir. **Bulgular:** Değerlendirilen toplam vaka sayısı 83 (48 kadın ve 35 erkek) olup yapılan karşılaştırmada 24 kadın ve 24 erkek hastadan oluşan 48 (%57,8) hasta pankreatik psödokist olarak ele alınmıştır. 35 (%42,2) (25 kadın ve 11 erkek) hastadan oluşan diğer grup ise gerçek kist tanımlaması ile endosonografik olarak değerlendirilmiştir. İstatistiksel olarak psödokistlerin endosonografik olarak boyutlarının daha geniş olduğu tespit edilmiştir. Yaş ve lokalizasyon ( $p=0,404$ ) açısından iki grup arasında istatistiksel fark bulunamamıştır. Kistler her iki grupta da sıklıkla pankreasın baş kesiminde görülmüştür. Tüm kist türleri patolojik sonuçlarına göre analiz edilmiş olup her iki gruptaki dominant sonuçlar normal sitolojik veriler ile uyumlu bulunmuştur. Pankreatik psödokist grubunda 1 vakada bakteriyel, başka bir vakada fungal kültür pozitif olarak tespit edilmiştir. Pankreatik psödokist grubunda 1 vakada atipik hücreler ve 1 vakada müsinöz hücreler saptanmıştır. Gerçek kist grubunda 4 (%11,4) vakada müsinöz sitoloji bulunmuş olup 1 vaka daha sonra cerrahi olarak kistadenokarsinom tanısı almıştır. **Sonuç:** Pankreatik kistler EUS ile ayırım yapılabilecek birtakım karakteristik özellikler taşımaktadır.

**Anahtar Kelimeler:** Biyopsi, ince-iğne; endosonografi; pankreas; kistler

doi: 10.5336/gastro.2015-47170

Copyright © 2015 by Türkiye Klinikleri

Türkiye Klinikleri J Gastroenterohepatol 2015;22(2):27-31

Pancreatic pseudocysts (PP) develop as a complication of pancreatitis in around 10% to 26% of acute and 20% to 40% of chronic cases.<sup>1</sup> They account for around 75% of all pancreatic cysts.<sup>2-5</sup> These cysts consist of pancreatic enzymes, which are dominated by amylase. Endoscopic Ultrasound (EUS) is a widely accepted and used procedure for transmural drainage of pancreatic pseudocysts, and EUS guided fine-needle aspiration (FNA) has become an important tool for cyst therapy and tissue sampling in the recent years.<sup>5</sup> The success rate of this drainage procedure for pseudocysts has been reported to be more than 90 percent with a complication rate of less than 5%.<sup>6,7</sup>

In this retrospective analysis, the primary objective was to determine the efficacy of EUS guided FNA for the diagnosis of cystic pancreatic material. The secondary aim was to evaluate the size of the all pancreatic cysts. Additionally, this study targeted to compare the size, localization and age of PP with true cysts. The two study groups were classified according to EUS based diagnostic criteria.

## MATERIAL AND METHODS

Eighty-three patients with true pancreatic cysts and pseudocysts treated between 2005 March and 2011 February were retrospectively identified from the database of Gazi University Gastroenterology Department. The distinction between pseudocysts and other pancreatic cysts was performed based on accompanying parenchymal changes with the absence of multicystic and nodular mural view. The presence of a history of pancreatitis and abdominal tomography findings were also additive diagnostic tools of PP. The intent for FNA was therapeutic in the most pseudocyst group in view of size and patient symptoms (eg infected necrosis), while the intent for FNA was diagnostic in the most true cyst group. The size of the cysts and available data on fine needle aspiration and surgical aspiration were also recorded during retrospective review. The approach for PP drainage using a 3.8 mm working channel linear array echoendoscope (Pentax, Montvale, NJ, USA) and a 22G needle (Wilson Cook). The optimal puncture site was determined using linear scanning function. Doppler ultrasound

function is used to discriminate major vessels and collateral veins.

Statistical analysis was performed using SPSS version 13.0 (SPSS, Inc., Chicago, Ill). Independent sample T test was the preferred statistical test to predict the difference between size of PP and true cysts, and patient's age. Comparison between the groups was performed using the chi-square test for categorical parameters.

## RESULTS

According to EUS criteria, 48 patients (57.8%), 24 female and 24 male subjects with PP and 35 (42.2%) patients (24 female and 11 male) with cystic lesions (totally 83 patients, 48 female and 35 male) were enrolled in the study. The total number of EUS procedures was 86. Three EUS sessions were performed for one male patient and two sessions for one female patient in the PP group.

The median age of the PP group was 53 years (the oldest patient being 77 years of age and the youngest patient being 28 years old). The mean maximal diameter of PP was 6.2 cm (max: 20; min: 0.3 cm). Totally 29 EUS FNA procedures were performed. The average diameter of the aspirated pseudocysts was 6.57 cm. Localization of some of the cysts could be identified by EUS. Of the 21 cases, in which exact location of PP could be demonstrated, the predominant site of PP was the pancreatic head with 9 (42.9%) cases. The remaining PPs were located in the body of the pancreas with 7 (33.3%) cases and in the tail region in 5 cases (23.8%). Demographic information of patients size and location of the cysts are shown in Table 1.

The second group consisted of patients with true pancreatic cysts. The mean age of the patients in this group was 54.5 years. The average maximal diameter of the cyst was 2.74 cm (max: 6 cm; min: 0.1 cm). The exact site of the cyst could be identified in 22 (64.7%) cases; 13 of them were located in the head of the pancreas, 4 of them in the body, and 5 of them in the tail region of pancreas.

The cytological results were also analyzed from the database (Figure 1). Additionally, it was

**TABLE 1:** Demographic information of the patients and location and size of the cysts

	Total: n *83 (35M: 48F)	PP: n 48 (24M: 24F)	True cysts: n 35 (11M: 24F)
Age, years (mean)	53,6	53	54,5
Location of the cyst	43	21	22
Head	22	9	13
Body	12	7	5
Tail	9	5	4
Size of the cyst, cm (mean)	4,62	6,2	2,74

PP: pancreatic pseudocyst. M: male, F: female, n: number

\*: 40 patients localisation can not be exactly classified.

observed that four of the cases were operated with a diagnosis of PP, and two of them came out to be necrotizing pancreatitis.

EUS guided aspiration was performed for 16 suitable PP cases. The mean diameter of the drained PP was 9.87 cm (min: 5 cm; max: 20 cm). Drainage was not preferred for PP under 5 cm.

For the PP group, the cytological results of 16 EUS guided FNA procedures were analyzed. Normal cytology was the most common finding (12 cases). Bacterial growth was detected in one sample and fungal culture was positive in another. One of the samples showed atypical cells and another demonstrated mucinous cells.

True pancreatic cysts were also evaluated. FNA was performed in 13 (37%) of 35 patients with true cysts. The most common cytological finding was normal cytology. There were four cases (11.4%) with mucinous cystic neoplasm. The exact diagnosis was confirmed by surgical intervention.

One of the cases was diagnosed to have cystadenocarcinoma by surgery. FNA had not been performed for this subject (Figure 1). Totally 9 (5 in the true cystic group and 4 in the PP group) patients surgical operation in the both study groups was performed.

PP and true cysts were compared according to their size and subject's age. The diameter of PP was significantly greater than that of true cysts ( $p < 0.001$ ) (Figure 2). The ages of the subjects in the two groups were similar ( $p = 0.667$ ).

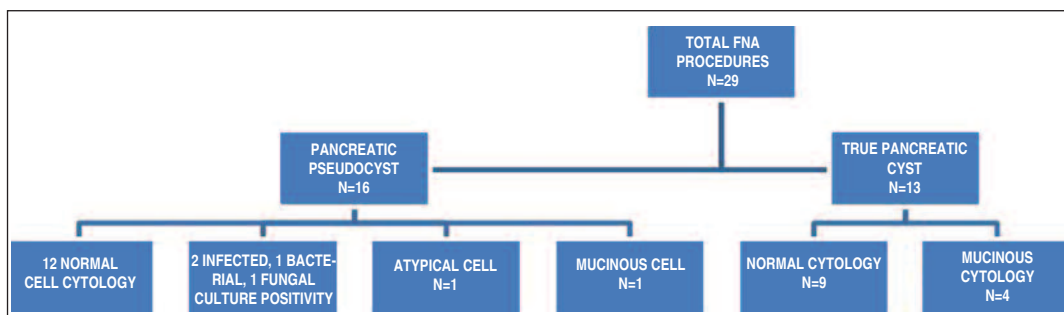
PP and true pancreatic cysts were also compared in terms of location. There was no difference between the two study groups in terms of location ( $p = 0.404$ ).

When all the patients were analyzed together (patients with PPs and true cysts), no difference was found between males and females in terms of cyst dimensions ( $p = 0.503$ ) and patient age ( $p = 0.647$ ).

Because of the insufficient retrospective data collection the cystic fluid amylase and tumor marker analysis couldn't be recorded.

## DISCUSSION

In this retrospective study, we explored the effectiveness of EUS for the diagnosis and treatment of pancreatic cystic lesions, true cysts and pseudocysts of the pancreas. We also reported the diagnostic results of EUS guided FNA data of our center. Location in the pancreas was similar for both cyst types. Both cysts were commonly located in the pancreatic head. The diameter of the PP measured by EUS



**FIGURE 1:** Cytological results of endoscopic ultrasound (EUS) guided fine-needle aspiration (FNA) procedures.

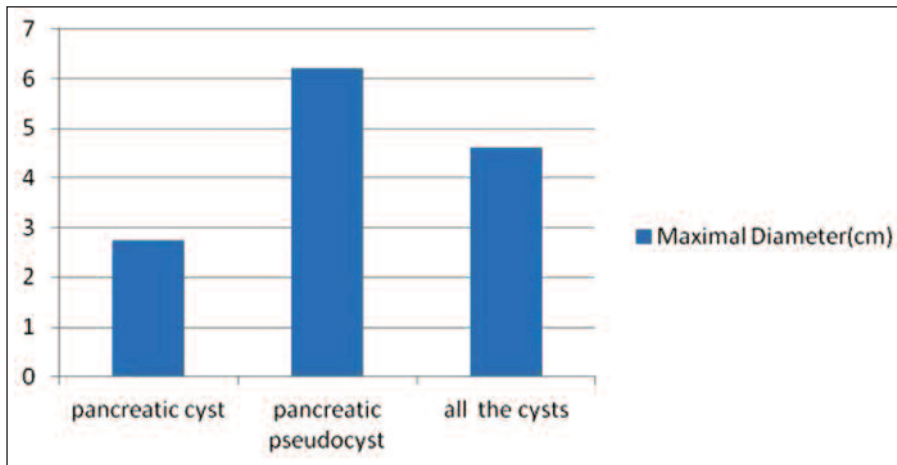


FIGURE 2: The mean maximal diameter of true pancreatic cysts and PP according to EUS measurements.

was significantly larger than the visual measurements of true pancreatic cysts. The majority of drained PP showed normal cytology. A few of the samples showed culture positivity. The fact that there was no evidence of atypical cells in the drained PP show that EUS is a highly accurate and reliable diagnostic method.

There are some studies investigating the characteristics of PP. Kim et al. identified some differences between PP developed after acute and acute on chronic pancreatitis.<sup>8</sup> The main diagnostic tool used in that study was computerized tomography. They found no difference in the location of PP between patients in both groups. In both groups, the prevalent location was the tail region of the pancreas (58.8% for acute and 52.2% for acute on chronic cases). In contrast to that study, EUS was used as the diagnostic tool in our study, and we found that the main location of PP was the head of the pancreas. Kim et al., found that the mean size of PP was 3.8 cm in the acute pancreatitis group and 3.3 cm in the acute-on-chronic pancreatitis group ( $P=0.37$ ).<sup>8</sup> The PP size found in the present study by EUS guided measurements was (mean, 6.2 cm) greater.

A multicenter study that investigated the diagnostic yield of EUS and its aspiration results, included 298 patients who underwent EUS for pancreatic cysts. FNA was also used in 44.3% of that patient group, and the diagnostic yield of FNA

was 47%. The authors stated that diagnostic efficiency increased with the proportion of solid component and repeat FNA. The most common diagnosis was PP followed by intraductal papillary mucinous neoplasm.<sup>9</sup> That study included 97 subjects with PP diagnosed according to EUS criteria. The mean cyst size was 4.5 cm in all 298 patients. Similar to our study, the most common site of PP was the head of the pancreas. Our study analyzed and compared some characteristic of PP and true cysts determined by EUS. We can say that the diagnostic assumptions made by EUS are consistent with biopsy results, thus, EUS results had a high reliability in the diagnosis of cysts.

There are also some other studies evaluating the value of EUS guided FNA in the diagnosis of pancreatic cysts. De Jong et al. found that EUS guided sampling is feasible in most cases with pancreatic cysts (87%), but it was possible to get an exact cytopathological diagnosis and a chemical analysis in only one third and one half of cases, respectively.<sup>10</sup> The majority of our cases showed normal cell count with no atypia. However, it should not to be forgotten that most of our FNA sampling was performed in the light of data obtained by EUS for PP cases, and these cases have a low probability of atypia.

Baresi et al. performed a prospective analysis on EUS guided FNA aspiration results.<sup>11</sup> They enrolled 58 patients with pancreatic cysts. CEA, amy-

lase and K-ras level in the aspirated pancreatic cyst fluid were determined in this study. 33.3% of the aspirates was mucinous cytology whereas most of our cytologic FNA results were in normal cytology. The second most common result in our aspirations was mucinous cytology. CEA K-ras level was not analysed in our study. Such cyst fluid studies could be a supporting value to differentiate the cyst type and identify the pseudocystic behaviors.<sup>11</sup>

Negm et al. studied the impact of EUS guided FNA on acute and chronic pancreatitis.<sup>12</sup> Microbial growth was found in twenty-six of the aspirates cultures (59% of the aspirated cultures). Polymicrobial growth were more common than monomicrobial growth. Additionally Gram positive cultures were more common isolated than Gram negative bacteria. In our study culture positivity was detected in only two aspirates collected from

PP group. The reason of these culture results could be the different microbial collection methodology. Additionally most of the patients in our study were in the PP group with non- infected pancreatitis.

## CONCLUSION

Pancreatic pseudocysts and true solitary cysts have characteristic properties that can be differentiated by EUS, one of them being the diameter of the cyst. The most common location of PP and other cysts is the pancreatic head. EUS guided FNA is also a valuable procedure for determining the cytological composition of the cysts.

## Acknowledgement

*Thanks to Dr Aylin Yetim for the help of the scientific evaluation of our article.*

## REFERENCES

- O'Malley VP, Cannon JP, Postier RG. Pancreatic pseudocysts: cause, therapy, and results. *Am J Surg* 1985;150(6):680-2.
- Bradley EL, Clements JL Jr, Gonzalez AC. The natural history of pancreatic pseudocysts: a unified concept of management. *Am J Surg* 1979;137(1):135-41.
- Grace PA, Williamson RC. Modern management of pancreatic pseudocysts. *Br J Surg* 1993;80(5):573-81.
- Pitchumoni CS, Agarwal N. Pancreatic pseudocysts. When and how should drainage be performed? *Gastroenterol Clin North Am* 1999;28(3):615-39.
- DeWitt J, Emerson RE, Sherman S, Al-Haddad M, McHenry L, Cote GA, et al. Endoscopic ultrasound-guided Trucut biopsy of gastrointestinal mesenchymal tumor. *Surg Endosc* 2011;25(7):2192-202.
- Varadarajulu S, Wilcox CM, Tamhane A, Eloubeidi MA, Blakely J, Canon CL. Role of EUS in drainage of peripancreatic fluid collections not amenable for endoscopic transmural drainage. *Gastrointest Endosc* 2007;66(6):1107-19.
- Antillon MR, Shah RJ, Stiegmann G, Chen YK. Single-step EUS-guided transmural drainage of simple and complicated pancreatic pseudocysts. *Gastrointest Endosc* 2006;63(6):797-803.
- Kim KO, Kim TN. Acute pancreatic pseudocyst: incidence, risk factors, and clinical outcomes. *Pancreas* 2012;41(4):577-81.
- Lim LG, Lakhtakia S, Ang TL, Vu CK, Dy F, Chong VH, et al; Asian EUS Consortium. Factors determining diagnostic yield of endoscopic ultrasound guided fine-needle aspiration for pancreatic cystic lesions: a multicentre Asian study. *Dig Dis Sci* 2013; 58(6):1751-7.
- de Jong K, Poley JW, van Hooft JE, Visser M, Bruno MJ, Fockens P. Endoscopic ultrasound-guided fine-needle aspiration of pancreatic cystic lesions provides inadequate material for cytology and laboratory analysis: initial results from a prospective study. *Endoscopy* 2011; 43(7):585-90.
- Barresi L, Tarantino I, Traina M, Granata A, Curcio G, Azzopardi N, et al. Endoscopic ultrasound-guided fine needle aspiration and biopsy using a 22-gauge needle with side fenestration in pancreatic cystic lesions. *Dig Liver Dis* 2014;46(1):45-50.
- Negm AA, Poos H, Kruck E, Vonberg RP, Domagk D, Madisch A, et al. Microbiologic analysis of peri-pancreatic fluid collected during EUS in patients with pancreatitis: impact on antibiotic therapy. *Gastrointest Endosc* 2013;78(2):303-11.