

Pericardial Effusion Induced by Umbilical Venous Catheterization: Case Report

Umbilikal Venöz Katetere Bağlı Perikardiyal Effüzyon

Özben CEYLAN,^a
 Utku Arman ÖRÜN,^a
 Selmin KARADEMİR,^a
 Osman YILMAZ,^a
 Vehbi DOĞAN,^a
 Senem ÖZGÜR,^a
 Mahmut KESKİN,^a
 Filiz ŞENOCAK,^a
 Burhan ÖCAL^a

^aClinic of Pediatric Cardiology,
 Dr. Sami Ulus Obstetrics, Child Health and
 Diseases Training and Research Hospital,
 Ankara

Geliş Tarihi/Received: 20.02.2012
 Kabul Tarihi/Accepted: 24.04.2012

Yazışma Adresi/Correspondence:

Özben CEYLAN
 Dr. Sami Ulus Obstetrics, Child Health and
 Diseases Training and Research Hospital,
 Clinic of Pediatric Cardiology, Ankara,
 TÜRKİYE/TURKEY
 ceylanozben@yahoo.com

ABSTRACT Pericardial effusion is a rare but life-threatening complication of umbilical venous catheterization in the newborn. Pericardial effusion is rarely seen as a complication of central venous catheterization. Use of central venous catheterization in neonatal intensive care units more commonly has caused increased incidence of pericardial effusion related to total parenteral nutrition. A 7-day-old male infant born prematurely was admitted to our clinic with the diagnosis of pericardial effusion. By guiding echocardiography, 40 ml milk-coloured total parenteral nutrition fluid was evacuated through subxiphoidal pericardiosynthesis. Following pericardiosynthesis, cardiorespiratory status improved significantly. Biochemical analysis aided in the diagnosis of catheter related etiology with possibility of parenteral nutrition fluid diffusion into the pericardial space. In a neonate with umbilical venous catheterization whose general status worsens and in whom cardiorespiratory signs develop pericardial effusion should be considered.

Key Words: Pericardial effusion; infant, newborn

ÖZET Perikardiyal efüzyon yenidoğanda umbilikal venöz kateterizasyona bağlı nadir fakat hayatı tehdit eden bir komplikasyondur. Santral venöz kateterlerin bir komplikasyonu olarak gelişen perikardiyal efüzyon oldukça seyrek görülür. Yenidoğan yoğun bakım ünitelerinde santral venöz kateterlerin kullanımının giderek artması, total parenteral nutrisyon ile ilişkili perikardiyal efüzyon insidansında artışa neden olmuştur. Prematüre olarak doğan 7 günlük erkek hasta perikardiyal efüzyon tanısıyla kliniğimize yönlendirildi. Ekokardiyografi eşliğinde subksifoid perikardiyosentez uygulanarak 40 ml süt renginde total parental nutrisyon sıvısı boşaltıldı. Perikardiyosentez sonrası hastanın kardiyorespiratuvar durumu önemli miktarda düzeldi. Perikardiyal aralıkta toplanan sıvının biyokimyasal analizi de kateterle ilişkili parenteral sıvının difüzyonu ile uyumluydu. Umbilikal venöz kateterizasyonu olan yenidoğanlarda genel durumun kötüleşmesi ve kardiyorespiratuvar değişikliklerin gelişmesi durumunda perikardiyal efüzyon düşünülmelidir.

Anahtar Kelimeler: Perikardiyal efüzyon; bebek, yenidoğan

Türkiye Klinikleri J Cardiovasc Sci 2013;25(1):59-62

Umbilical venous catheterization (UVC) is commonly used in neonatal care for administration of fluids, parenteral nutrition and drugs, taking sample for blood gas analysis, central blood pressure monitoring, and also for exchange transfusion.¹ However, UVC may cause some complications like arrhythmia, thrombosis, myocardial perforation, endocarditis, pericardial and pleural effusion, and sepsis. Pericardial and pleural effusion compose 0.7% of the complications of central venous catheterization which may be fatal.²⁻⁵ We want to present a case who de-

veloped pericardial effusion as a complication of UVC performed for administration of parenteral nutrition.

CASE REPORT

The 7-day-old male infant born prematurely was admitted to our clinic with the diagnosis of pericardial effusion. In his history, he was born with 29 gestational weeks weighing 1440 g to a gravida 1, parity 1 woman by cesarean section due to fetal distress. 1st minute and 5th minute APGAR scores were 6 and 8, respectively. Following birth, the infant was hospitalized in neonatal intensive care unit, nasal continuous positive airway pressure (CPAP) was applied, UVC was inserted, and the infant was started to be fed with total parenteral nutrition (TPN). He received amikacin and penicilin G as antibiotherapy. At the 7th day of hospitalization, the patient became to get worse with tachycardia, tachypnea, and in his chest x ray, cardiomegaly was seen (Figure 1). Echocardiography revealed pericardial effusion (Figure 2). With these findings, the patient was referred to our clinic. In the physical examination, the general status of the infant was bad. Further examination revealed the body temperature to be 36.0 °C, breath rate 78/min, heart rate 188 bpm, blood pressure 78/38(46) mmHg, O₂ saturation 85%, and the weight 1370 g. On chest x ray, in addition to cardiomegaly, the catheter was seen to end within the cardiac silhouette.

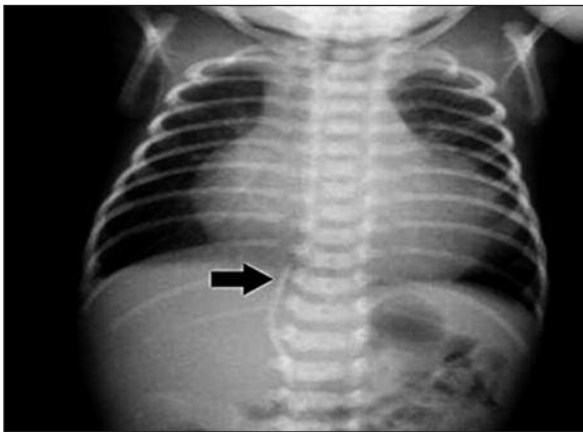


FIGURE 1: The tip of the catheter is seen within the cardiac silhouette (black arrow points to the tip of the catheter).

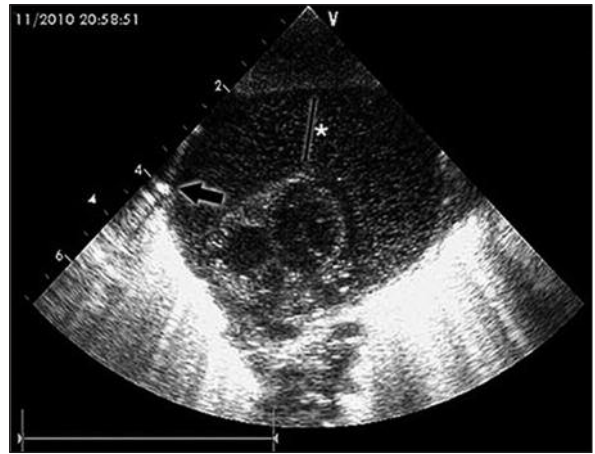


FIGURE 2: Massive effusion in pericardial space and section of the catheter as it passes the pericardial space (black arrow: catheter section, *: pericardial effusion).

In Doppler echocardiography, the tip of the umbilical venous catheter was seen to enter the pericardial space from the site where inferior vena cava opens into the right atrium, and massive pericardial effusion was noted. By guiding echocardiography, 40 ml milk-coloured TPN fluid was evacuated through subxiphoidal pericardiosynthesis. Following pericardiosynthesis, the pulse was 146 bpm, breath rate 40/min, blood pressure 78/41 (55) mmHg, O₂ saturation 98-100%. The patient was weaned successfully from nasal CPAP. In pericardial fluid biochemical analysis, glucose level was 502 mg/dL, triglyceride 449 mg/dl, albumin 20.8 mg/dl, total protein <1.0 mg/dl, and cholesterol was less than lower limit of the measurable range. In cell count, WBC was 15/mm³ (54% neutrophilic), RBC was 72/mm³. In the culture of the pericardial fluid, no growth occurred. Following pericardiosynthesis, pericardial fluid decreased and totally disappeared at the 3th day in echocardiography.

DISCUSSION

Pericardial effusion is rarely seen as a complication of central venous catheterization. Use of central venous catheterization in neonatal intensive care units more commonly has caused increased incidence of pericardial effusion related to TPN.⁶ The reason of pericardial effusion development is not clear, however, various mechanisms have been

suggested according to clinical and autopsy findings.^{5,7} These are passage of the TPN fluid into the pericardial space due to direct perforation of the myocardium by catheter tip during the advance of the catheter, and more often, diffusion of the TPN fluid into the pericardial space a few days after catheterization owing to local thrombosis and myosclerosis developig as a result of endothelial damage caused the recurring hit of the catheter tip. Another mechanism may be the development of pericardial effusion through intramural diffusion as a result of osmotic damage resulting from the hyperosmolar TPN solution. The known risk factors for pericardial effusion are catheter malposition and migration, and hyperosmolar infusion.^{5,8} We think that the reason of pericardial effusion development in our case was the perforation of the atrial wall because the catheter tip was seen to be in the pericardial space.

Replacement of the catheter at the right position and site is important to avoid complications. The optimal catheter localization is the junction of right atrium and vena cava inferior (VCI), or thoracic vena cava inferior.⁹ The most common tool in the determination of UVC site is anteroposterior chest X-ray; the catheter tip should be just above the diaphragma, or its localization is determined according to the vertebral bodies. Greenberg et al stated that the localization of UVC tip at T8-T9 vertebrae level at X-ray corresponds to right atrium-VCI junction in echocardiography.¹⁰ On the other hand, Ades et al revealed the tip of the UVC to correspond to T6-T11 vertebral space at chest X-ray when it is seen at right atrium-VCI junction in echocardiography.⁷ Besides, it has been stated in many articles that direct X-ray graphy is not reliable in determining the place of the catheter tip accurately. In our patient, the catheter tip was beyond the right atrium and VCI junction in echocardiography although it was at T9 vertebra level in X-ray.

In their series of 61 cases consisting of 14 cases with pericardial effusion from six different neonatology clinics within two years and 47 cases gathered from the literature between 1970 and 1999, Nowlen et al found that UVC had been performed in 21 patients whereas 40 patients had peripheral

central catheter, and in 92% of the cases, the tip of the catheter was within the cardiac silhouette.⁵ In that study, the median duration between catheterization and development of pericardial effusion signs and/or diagnosis was found out 3 days, and the appearance of the fluid was in accordance with TPN in 53 (98%) cases among 54 cases in whom pericardiosynthesis had been performed. In 37 cases, the fluid was analyzed biochemistrically, and it was shown to be TPN fluid in 36 (97%) patients. In addition, the mortality rate was 34% in that study.⁵ In their 5-year-long study, Beardsall et al. showed that among 46 000 neonates in whom central venous catheter (CVC) had been performed, 82 developed pericardial effusion or tamponade, the frequency of pericardial effusion or cardiac tamponade being 1.8 for 1000 catheters and the mortality 0.7 for 1000 catheters.⁸

The appearance of the pericardial fluid aspirated from our patient was milk-like (Figure 3). High glucose and triglyceride levels in biochemistry analysis supported that the fluid was TPN. The diagnosis was made at the 7th day although the symptoms had developed 3 days after the insertion of the catheter.

Weak heart beats, tachycardia or bradycardia, poor peripheral pulse, paleness, cyanosis, circulation disorder, increased inotropic support require-

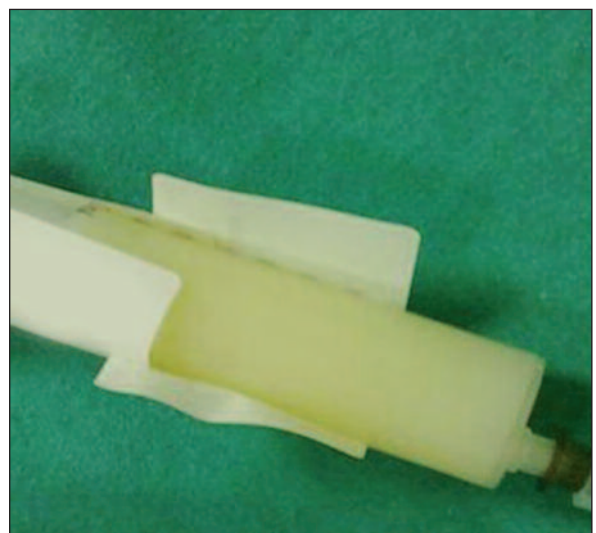


FIGURE 3: Aspirated pericardial fluid.

(See color figure at <http://cardiovascular.turkiyeklinikleri.com/>)

ment and unexplained cardiopulmonary deterioration are nonspecific signs of pericardial effusion.^{5,8,11,12} In our patient, echocardiography was performed as the development of cardiopulmonary signs like tachycardia and tachypnea let us think that the causative pathology might be related to CVC, and abundant amount of pericardial fluid was seen. In our patient signs of tamponade were detected and pericardiocentesis was performed. However, in cases without evidence of tamponade it

must be known that only withdrawal of the catheter lead to decline of effusion without pericardiocentesis.

In conclusion, we want to emphasize that in a neonate with UVC whose general status worsens and in whom cardiorespiratory signs develop pericardial effusion should be kept in mind, and that pericardial effusion might develop in spite of the appearance of the catheter at appropriate localization in direct graphy.

REFERENCES

- Butler-O'Hara M, Buzzard CJ, Reubens L, McDermott MP, DiGrazio W, D'Angio CT. A randomized trial comparing long-term and short-term use of umbilical venous catheters in premature infants with birth weights of less than 1251 grams. *Pediatrics* 2006;118(1):e25-35.
- Egan EA 2nd, Eitzman DV. Umbilical vessel catheterization. *Am J Dis Child* 1971;121(3):213-8.
- Mehta S, Connors AF Jr, Danish EH, Grisoni E. Incidence of thrombosis during central venous catheterization of newborns: a prospective study. *J Pediatr Surg* 1992;27(1):18-22.
- Gilon D, Schechter D, Rein AJ, Gimmon Z, Or R, Rozenman Y, et al. Right atrial thrombi are related to indwelling central venous catheter position: insights into time course and possible mechanism of formation. *Am Heart J* 1998;135(3):457-62.
- Nowlen TT, Rosenthal GL, Johnson GL, Tom DJ, Vargo TA. Pericardial effusion and tamponade in infants with central catheters. *Pediatrics* 2002;110(1 Pt 1):137-42.
- Wirrell EC, Pelausa EO, Allen AC, Stinson DA, Hanna BD. Massive pericardial effusion as a cause for sudden deterioration of a very low birthweight infant. *Am J Perinatol* 1993;10(6):419-23.
- Arya SO, Hiremath GM, Okonkwo KC, Petersen MD. Central venous catheter-associated pericardial tamponade in a 6-day old: a case report. *Int J Pediatr*. 2009;2009:910208. doi: 10.1155/2009/910208. Epub 2010 Feb 9.
- Beardsall K, White DK, Pinto EM, Kelsall AW. Pericardial effusion and cardiac tamponade as complications of neonatal long lines: are they really a problem? *Arch Dis Child Fetal Neonatal Ed* 2003;88(4):F292-5.
- Paster S, Middleton P. Roentgenographic evaluation of umbilical artery and vein catheters. *JAMA* 1975;231(7):742-6.
- Greenberg M, Movahed H, Peterson B, Bejar R. Placement of umbilical venous catheters with use of bedside real-time ultrasonography. *J Pediatr* 1995;126(4):633-5.
- Weil BR, Ladd AP, Yoder K. Pericardial effusion and cardiac tamponade associated with central venous catheters in children: an uncommon but serious and treatable condition. *J Pediatr Surg* 2010;45(8):1687-92.
- Thomson TL, Levine M, Muraskas JK, El-Zein C. Pericardial effusion in a preterm infant resulting from umbilical venous catheter placement. *Pediatr Cardiol* 2010;31(2):287-90.