

## CASE REPORT

DOI: 10.5336/caserep.2019-71483

## Urethro-Rectal Perforation as a Complication of Foley Catheterization

<sup>id</sup> Ali ÇİFT<sup>a</sup>, <sup>id</sup> Murat GEZER<sup>b</sup>, <sup>id</sup> Can BENLİOĞLU<sup>a</sup>, <sup>id</sup> Mehmet Özgür YÜCEL<sup>a</sup>, <sup>id</sup> Bedreddin KALYENÇİ<sup>a</sup>

<sup>a</sup>Adıyaman University Faculty of Medicine, Department of Urology, Adıyaman, TURKEY

<sup>b</sup>Adıyaman Training and Research Hospital, Clinic of Urology, Adıyaman, TURKEY

**ABSTRACT** Urethral catheterization is rarely associated with intestinal perforation. Urethro-rectal perforation as a complication of urethral instrumentation is rarely seen. Only one case of bladder and small bowel perforation as a complication of Foley catheterization has been reported. In patients with intestinal perforation, treatment usually consists of laparotomy and repair of perforation. In this report, we aimed to present a case of acute urethro-rectal perforation and management of it as a complication of urethral Foley catheterization. To our knowledge, this is the first documented acute urethro-rectal perforation during Foley catheterization. We think that endoscopic treatment is sufficient in early diagnosed cases without performing laparotomy. In addition, in patients who had previously undergone prostate or urethra operation, we think that the Foley catheter should not be forced and should be treated more carefully while placing the Foley.

**Keywords:** Foley catheter; rectum perforation, urethral perforation

Urethro-rectal perforation is rarely seen as a complication of urethral instrumentation. In this report, we aimed to present a case of acute urethro-rectal perforation and management of treatment as a complication of urethral Foley catheterization.

### CASE REPORT

A 82-year-old male patient presented to the urology clinic with the complaints of inability to urinate. It was determined that 12 hours before his presentation, the patient had been admitted to the emergency department with the complaint of severe difficulty in urination and a urethral Foley catheter was attempted to be placed, but the procedure was unsuccessful. The patient had a history of open prostatectomy five years earlier and was referred to the urology clinic. The physical examination revealed the presence of a vesical globe. A 16 F Foley catheter was inserted into the urethra and confirmed to be properly placed in the

bladder, but no urine was seen. Purulent fluid was observed after the irrigation of the Foley catheter. The catheter was palpated on digital rectal examination.

Considering that it was not actually positioned in the bladder, the urethral Foley catheter was withdrawn from the urethra. Retrograde urethrography revealed no transition of the contrast agent into the bladder and rectal transition from the level of the membranous urethra (urethro-rectal perforation) (Figure 1).

Contrast agent was passed down to the urethra retrogradely, and the passage of the contrast agent to the rectum from the membranous urethra was seen on the computed tomography (CT) scan (Figure 2). Cystourethroscopy and a required intervention were planned for the patient.

Routine laboratory tests revealed normal findings, except the white blood cell count and C-reactive protein (nephelometric), which were 15,810 and

**Correspondence:** Mehmet Özgür YÜCEL

Adıyaman University Faculty of Medicine, Department of Urology, Adıyaman, TURKEY

**E-mail:** mozyucel@yahoo.com



Peer review under responsibility of Türkiye Klinikleri Journal of Case Reports.

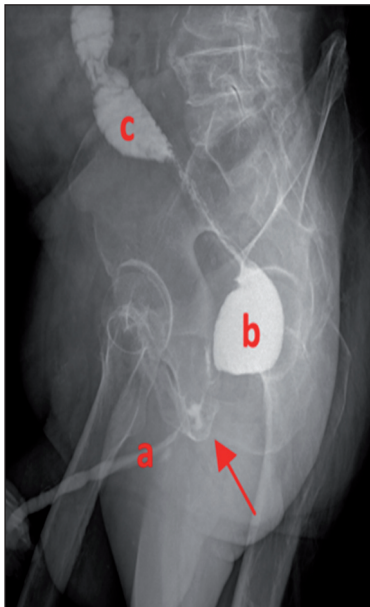
**Received:** 17 Sep 2019

**Received in revised form:** 04 Nov 2019

**Accepted:** 05 Nov 2019

**Available online:** 22 Nov 2019

2147-9291 / Copyright © 2020 by Türkiye Klinikleri. This is an open access article under the CC BY-NC-ND license (<http://creativecommons.org/licenses/by-nc-nd/4.0/>).



**FIGURE 1:** Retrograde urethrography: a) urethra, b) rectum, c) sigmoid colon.

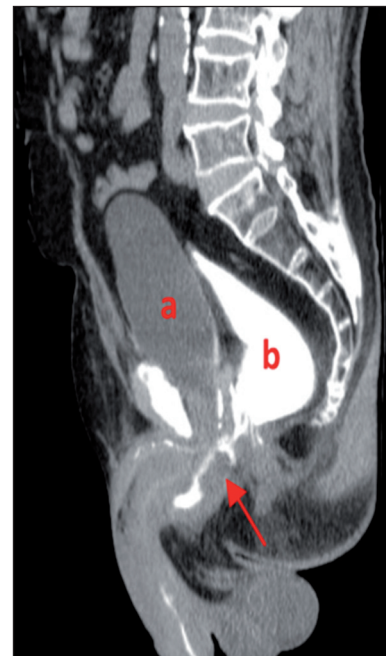was 9.2 mg/dl, respectively. The patient was treated with intravenous ceftriaxone 1g 2x1 and intravenous metronidazole 500 mg 3x1 empirically. Urethroscopy showed a posterior perforation area at the level of the membranous urethra. Severe stenosis was seen proximal to this level on urethroscopy. A guide wire was inserted from the stenotic segment to perform internal urethrotomy, and a 20 F Foley catheter was placed into the bladder.

The examination of the anorectal canal revealed a 1 cm perforation on the anterior wall of the rectum and was repaired with primary sutures by the transrectal route. No perioperative complication was observed.

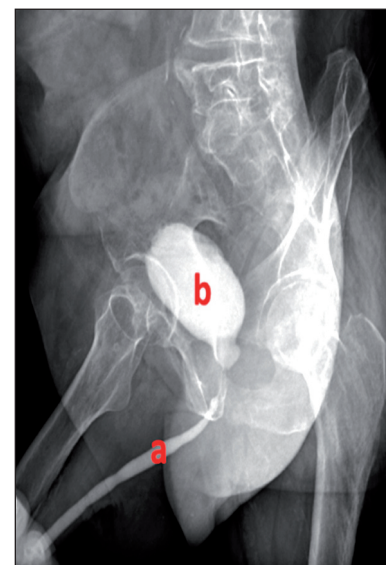
The patient's oral nutrition was stopped for three days. During the follow-up, there was no problem with bowel functions. Oral intake was started. *Escherichia coli* was detected in the urine culture. In accordance with the results of the antibiogram, ceftriaxone was discontinued and meropenem 1 g 3x1 was started, which was continued for 14 days. The control urine culture was sterile. On the postoperative 15<sup>th</sup> day, the urethral catheter was withdrawn. The control retrograde urethrography showed that the contrast medium was easily passed through the bladder and there was no fistula (Figure 3). The patient

was discharged and no long-term complications occurred. To the best of our knowledge, this is the first case of urethro-rectal perforation that occurred during Foley catheterization.

Written informed consent has been obtained from the patient for publishing this case.



**FIGURE 2:** Computed tomography: a) bladder, b) rectum.



**FIGURE 3:** Postoperative 15<sup>th</sup> day retrograde urethrography: a) urethra, b) bladder.

## DISCUSSION

Urethral catheterization is rarely associated with intestinal perforation.<sup>1-5</sup> Perforation may cause a fistula if not timely detected. The risk factors for the majority of cases of urethra-rectal perforation or fistulas include advanced age and a history of prostate or bowel operations or radiotherapy.<sup>6</sup> This condition has very characteristic symptoms and signs, such as fecaluria, pneumaturia, and leakage of urine into the rectum.

The most appropriate approach in the treatment of urethra-rectal perforation or fistulas remains controversial. Although small perforation or fistula tracts may be spontaneously closed after urinary or intestinal diversion, surgical repair is required in the majority of cases. To date, many different surgical approaches have been described. Although transanal, transsphincteric, perineal (posterior) and transabdominal (anterior) approaches have been detailed in the literature, there is still no consensus on the optimal treatment method.<sup>7</sup>

A detailed preoperative anatomical, functional, oncological and metabolic examination is essential for an appropriate treatment plan. The absence of a randomized and/or prospective study to assist surgeons in the treatment planning phase and the scarcity of evidence in this regard have mostly led surgeon experience in personal clinical practice to guide related decisions. In the treatment of complex fistulas, especially in cases that develop after radiotherapy, the general approach of surgeons with experience in the field appears to be the posterior transperineal approach and flap interposition.<sup>8</sup>

McDowell et al. reported two cases of urethro-rectal perforation as a complication of urethral instrumentation. These patients were treated with loop colostomy and suprapubic cystostomy diversion, and no fistula formation was detected at the 24-month follow-up.<sup>9</sup>

In the current case, we consider that the risk factors for urethro-rectal perforation were urethral stenosis associated with open prostatectomy performed

five years earlier due to benign prostatic hyperplasia and the force applied during the attempt to insert a Foley catheter through the urethral route. Since our patient was diagnosed and treated at an early stage, we did not observe any of the typical symptoms of the condition, such as fecaluria, pneumaturia, and leakage of urine into the rectum. In the treatment of our case, endoscopic internal urethrotomy was performed, and a Foley catheter was inserted into the bladder through the urethra and the primary repair of intestinal perforation was performed using the transanal approach. No fistula formation was observed at the 12<sup>th</sup>-month follow-up.

In conclusion, utmost care must be taken not to apply any force during Foley catheterization through the urethra in patients that have previously undergone prostatic or urethral surgery. In addition, we consider that in similar cases of urethro-rectal perforation, endoscopic treatment is sufficient and laparotomy is not required.

### Source of Finance

*During this study, no financial or spiritual support was received neither from any pharmaceutical company that has a direct connection with the research subject, nor from a company that provides or produces medical instruments and materials which may negatively affect the evaluation process of this study.*

### Conflict of Interest

*No conflicts of interest between the authors and / or family members of the scientific and medical committee members or members of the potential conflicts of interest, counseling, expertise, working conditions, share holding and similar situations in any firm.*

### Authorship Contributions

**Idea/Concept:** Ali Çift; **Design:** Ali Çift, Murat Gezer, Can Benlioğlu, Mehmet Özgür Yücel, Bedreddin Kalyenci; **Control/Supervision:** Ali Çift, Murat Gezer, Can Benlioğlu, Mehmet Özgür Yücel, Bedreddin Kalyenci; **Data Collection and/or Processing:** Ali Çift; **Analysis and/or Interpretation:** Ali Çift, Murat Gezer, Can Benlioğlu, Mehmet Özgür Yücel, Bedreddin Kalyenci; **Literature Review:** Ali Çift; **Writing the Article:** Ali Çift, Murat Gezer; **Critical Review:** Ali Çift, Murat Gezer, Can Benlioğlu; Mehmet Özgür Yücel Bedreddin Kalyenci; **References and Fundings:** Ali Çift.

## REFERENCES

1. Cano-Valderrama O, Domínguez-Serrano I, Esteban Collazo F, Torres García AJ, Cerdán Miguel J. [Enterovesical fistula caused by an indwelling bladder catheter.] *Cir Esp.* 2012;90(8):535-7. [[Crossref](#)] [[PubMed](#)]
2. Baba K, Yajima M, Takahashi H, Nakano M, Kuroko K, Iwamoto T, et al. [Ileovesical fistula caused by long-term indwelling of urethral catheter: a case report]. *Hinyokika Kyo.* 1995;41(3):235-7. [[PubMed](#)]
3. Hawary A, Clarke L, Taylor A, Duffy P. Enterovesical fistula: a rare complication of urethral catheterization. *Adv Urol.* 2009;59:1204. [[Crossref](#)] [[PubMed](#)] [[PMC](#)]
4. Amend G, Morganstern BA, Salami SS, Moreira DM, Yaskiv O, Elsamra S. Acute bladder and small bowel perforation as a complication of Foley catheterization. *Urology.* 2014;83(3): e5-6. [[Crossref](#)] [[PubMed](#)]
5. Zachariou A, Kolynou A, Filiponi M. Rectal perforation: a rare complication of indwelling urethral catheterization. *Hippokratia.* 2017;21(1):58. [[PubMed](#)]
6. McBeath RB, Schiff M Jr, Allen V, Bottaccini MR, Miller JI, Ehreth JT. A 12-year experience with enterovesical fistulas. *Urology.* 1994;44(5):661-5. [[Crossref](#)]
7. Choi JH, Jeon BG, Choi SG, Han EC, Ha HK, Oh HK et al. Park KJ. Rectourethral fistula: systemic review of and experiences with various surgical treatment methods. *Ann Coloproctol.* 2014;30(1):35-41. [[Crossref](#)] [[PubMed](#)] [[PMC](#)]
8. Altay B, Erkurt B, Boz MY, Albayrak S. Rektouretral fistül tedavisinde arka üretraya perineal yaklaşım. *Yeni Üroloji Dergisi.* 2018;13(1):67-71.
9. Mcdowell GC 2nd, Wise HA 2nd. Rectal perforation as a complication of urethral instrumentation: 2 case reports. *J Urol.* 1988;140(3):605-6. [[Crossref](#)] [[PubMed](#)]