

Spinal Pathologies in Patients with Notalgia Paresthetica and Positive Effect of Strengthening Exercises on Itch Relief: Case Series

Notaljia Parestetikali Hastalardaki Omurga Patolojileri ve Güçlendirme Egzersizlerinin Kaşıntıyı Gidermede Olumlu Etkisi: Olgu Serisi

 Semih GÜDER^a,  Hüsna GÜDER^b

^aDepartment of Dermatology, Bezmialem Vakıf University Faculty of Health Sciences, İstanbul, TURKEY

^bDepartment of Dermatology, Maltepe University Faculty of Health Sciences, İstanbul, TURKEY

ABSTRACT Objectives: Notalgia paresthetica is a subgroup of localized neuropathic chronic itch and is due to a nerve entrapment limited to the corresponding dermatome. Neuropathic itching often includes signs of sensitive skin syndrome (numbness, burning, stinging, tingling, etc.). It does not respond to antipruritic treatments used in other itchy dermatoses. The relationship between neuropathic itching and spinal pathology has been reported in many studies. Degenerative disc hernias may play a role in chronic itching localized to the back, hand, and brachioradial areas. We aimed to remind these patients we encountered in our clinical practice. **Material and Methods:** The files of 12 patients with notalgia paresthetica who applied to our dermatology outpatient clinic between 2016-2018 were reviewed. Diagnostic criteria are: No primary skin lesions in the affected skin area, the absence of any other itchy skin disease, detection of spinal pathology compatible with the itching area in magnetic resonance imaging, no other history of systemic disease or medication to explain itching. **Results:** Spinal canal stenosis, herniated nucleus pulposus, dural sac compression, and non-compressive bulging and protrusions were seen as spinal pathology. Itching completely disappeared in one of the four patients who conformed to the program, and the itch severity decreased in the other three patients. **Conclusion:** It should be kept in mind that itching may be of neuropathic origin in patients with localized chronic itching. Spine strengthening and stretching exercises may be a good option as primary or adjuvant therapy in neuropathic itching due to spinal pathology. Advanced clinical studies are needed.

ÖZET Amaç: Notaljia parestetika, lokalize nöropatik kronik kaşıntının bir alt grubudur ve ilgili dermatom ile sınırlı bir sinir lifi kompresyonuna bağlı olarak gelişir. Nöropatik kaşıntı genellikle hassas deri sendromu belirtilerini de içerir (uyuşma, yanma, batma, karıncalanma vb.) ve diğer kaşıntılı dermatozlarda kullanılan antipruritik tedavilere cevap vermez. Nöropatik kaşıntı ile omurga patolojisi arasındaki ilişki birçok çalışmada bildirilmiştir. Dejeneratif disk hernileri sırt bölgesi, el bölgesi ve brakioradial bölgelere lokalize olan kronik kaşıntı gelişiminde rol oynayabilir. Biz bu vaka serisi ile klinik pratiğimizde karşılaştığımız bu hastaları tekrardan hatırlatmayı amaçladık. **Gereç ve Yöntemler:** Dermatoloji polikliniğimize 2016-2018 yılları arasında başvuran notalgia parestetikali 12 hastanın dosyaları retrospektif olarak gözden geçirildi. Tanı kriteri olarak; etkilenen cilt bölgesinde primer bir deri lezyonu olmaması, başka herhangi bir kaşıntılı deri hastalığının olmaması, manyetik rezonans görüntüleme kaşıntı alanı ile uyumlu spinal patolojinin saptanması, kaşıntıyı açıklayacak başka sistemik hastalık veya ilaç öyküsü olmaması temel alındı. **Bulgular:** Spinal patoloji olarak spinal kanal stenozu, herniye nukleus pulposus, dural kese basısı, kompresif olmayan bulging ve protrüzyonlar görüldü. Egzersiz programına uyan 4 hastadan birinde kaşıntı tamamen kaybolurken, diğer 3 hastada kaşıntı şiddeti azaldı. **Sonuç:** Lokalize kronik kaşıntılı hastalarda, kaşıntının nöropatik orijinli olabileceği unutulmamalıdır. Omurga güçlendirme ve germe egzersizleri, omurga patolojisine bağlı nöropatik kaşıntının primer veya adjuvan tedavisinde iyi bir seçenek olabilir. İleri klinik çalışmalara ihtiyaç vardır.

Keywords: Notalgia paresthetica; neuropathic itch; strengthening exercises; spinal pathology

Anahtar Kelimeler: Notaljia parestetika; nöropatik kaşıntı; güçlendirme egzersizleri; spinal patoloji

Itching is an uncomfortable feeling and evokes a desire to draw. Chronic itching is defined as itching that can last almost every day for more than six weeks.¹ It is estimated that 8% of cases with chronic

itching are of neuropathic origin.² Neuropathic itching is caused by an underlying neuroanatomic pathology and is a symptom of central and peripheral nervous system disorders that cause neuropathic pain.

Correspondence: Semih GÜDER

Department of Dermatology, Bezmialem Vakıf University Faculty of Health Sciences, İstanbul, TURKEY/TÜRKİYE

E-mail: semihguder@gmail.com



Peer review under responsibility of Türkiye Klinikleri Journal of Dermatology.

Received: 08 Dec 2020

Received in revised form: 15 Mar 2021

Accepted: 13 Apr 2021

Available online: 19 Apr 2021

2146-9016 / Copyright © 2021 by Türkiye Klinikleri. This is an open access article under the CC BY-NC-ND license (<http://creativecommons.org/licenses/by-nc-nd/4.0/>).

It is caused by localized or generalized degeneration of small nerve fibers. If nerve fiber compression is present, pruritus often appears in the corresponding dermatome, whereas in nerve fiber degeneration, localized or generalized pruritus occurs.^{3,4} Notalgia paresthetica and brachioradial pruritus is a subgroup of localized neuropathic chronic itch and is due to a nerve entrapment limited to the corresponding dermatome.^{3,4}

The primary itching pathway is the group of C fibers (nociceptors) of the sensory nerves. It was suggested that the itching sensation was caused by low activation of these fibers. C fibers are also thought to transmit burning sensation, which is a subgroup of pain.⁵ C fibers are sensitive to stimuli such as histamine and heat, and their transmission speed is plodding. In some studies, A-delta group thin myelinated fibers have also been shown to play a role in itching.⁶

Neuropathic itching often includes signs of sensitive skin syndrome (numbness, burning, stinging, tingling, etc.). It does not respond to antipruritic treatments used in other itchy dermatoses.^{3,7}

The causes of neuropathic itching are heterogeneous, so its diagnosis is based on recognizing disease-specific clinical symptoms and eliminating other diagnoses that will explain existing itching. Skin biopsy and magnetic resonance imaging (MRI) also help in the diagnosis of the disease. The increase in cutaneous nerve density in the affected skin area on skin biopsy supports the diagnosis. In MRI, intervertebral foramen stenosis, dural sac compression, and spinal canal stenosis matching the pruritus's dermatome localization can be observed.⁴

The relationship between neuropathic itching and spinal pathology has been reported in many studies.⁸ Degenerative disc hernias may play a role in chronic itching localized to the back, hand, and brachioradial areas.^{3,8}

There are few reports that the exercises are therapeutic in patients with notalgia paresthetica, subgroups of neuropathic itching.^{9,10} Exercise models have generally been studied in neuropathic pain treatments rather than neuropathic itching. Physical activities seem to be an effective treatment method for neuropathic pain treatment.¹¹ For example, muscle

strengthening programs in patients with lumbar disc hernias have helped reduce patients' pain symptoms.⁵

Based on this information, it can be thought that physical exercise methods may be helpful in the treatment of neuropathic itching secondary to an underlying spinal pathology. Patients can be enrolled in muscle strengthening and stretching exercise programs that support the spine before drug treatment.

MATERIAL AND METHODS

Twelve patients who applied to our dermatology outpatient clinic between 2016 and 2018 were examined.

Diagnostic criteria are:

- No primary skin lesions in the affected skin area
- The absence of any other itchy skin disease
- On MRI, detection of spinal pathology compatible with the itching area
- No other history of systemic disease or medication to explain itching

Itching severity was measured before and 12 weeks after exercise program with using the visual analogue scale (0=no pruritus, >0-<4 points=mild pruritus, ≥4-<7 points=moderate pruritus, ≥7-<9 points=severe pruritus, and ≥9 points=very severe pruritus).¹²

Exercise model (all patients were taught) which they can easily apply at home using resistance bands for strengthening the paraspinal muscles around the spine by our physiotherapist (three days a week including one set of warming, a total of 4 sets of 10 reps) and also dynamic strengthening exercise model for the neck region, back row, and squat exercises for the back and waist region were given to the patients (Figure 1). The patients had been told to continue the program without any sudden and explosive movement by minimally increasing the resistance they applied every week. Consent was obtained from our patients.

RESULTS

All of the cases had an itch that came in one or more attacks during the day and lasted for a few minutes,

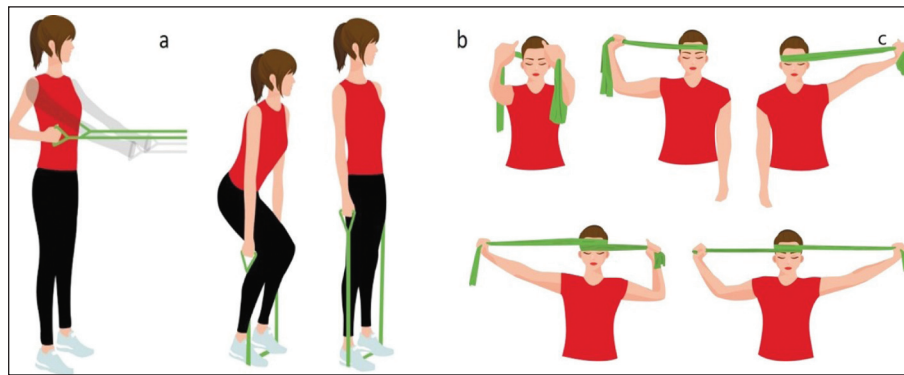


FIGURE 1: Back row (a), and Squat (b) exercise model with theraband. Dynamic strengthening exercise model with theraband for the neck region (c).

did not show seasonal changes, and none had a family history.

Hyperalgesia was accompanied in the affected skin area in cases 10 and 11, hyperpigmentation in cases 9 and 10, paresthesia in cases 2, 10, 11, and 12. Neurological deficits were not detected in any of the patients.

Dermatomal distribution of the skin areas in which 12 cases described itching was compatible with the innervation area caused by the detected pathology on MRI. Spinal canal stenosis, herniated nucleus pulposus, dural sac compression, and non-compressive bulging and protrusions were seen as spinal pathology.

Case 1, 8, 9 and 12 continued the exercises. At the end of 12 weeks, the itching scores decreased from 8 to 4 (50%) in case 1 and 12, from 8 to 2 (75%) in case 8, and 6 to 0 (100%) in case 9 (Figure 2).

DISCUSSION

Although the cause is unknown, neuropathies cause pain symptoms in some people, while in others, itch sensation.² In patients with notalgia paresthetica and brachioradial pruritus, spinal pathologies including herniated nucleus pulposus and degenerative vertebral changes were found in most patients.¹³ Similarly, our patients had herniated nucleus pulposus, narrowing the neural foramen, dural sac compression, and non-compressive protruded vertebral discs.

The benefits of stretching exercises have been demonstrated in notalgia paresthetica. Here, stretch-

ing the spine is thought to be effective by correcting the spinal cord level's nerve angles.⁹ Therefore, if stretching and strengthening exercises are performed together, it may be thought that the success of the treatment may increase.

The anti-inflammatory properties of the exercise over enzymes regulating neuroinflammation have been studied in animal models. Also, the positive effects of non-explosive, low-volume, and low-frequency long-term loading exercises on disc regeneration processes have been reported.^{11,14,15}

It has been shown that microglial activation and neuroinflammation in the dorsal root of the spinal cord play a role in the onset and continuation of neuropathic pain. These inflammatory cytokines trigger neuropathic pain through effects such as microglial activation, phagocyte infiltration, Schwann cell damage, and increased nociceptor sensitivity.

Glial glycogen synthase kinase-3 (GSK-3) is an enzyme that regulates glycogen synthesis and many transcription factors, neuroinflammation that plays an essential role in the activation of glial cells and pro-anti-inflammatory balance. GSK-3 stimulates interleukin-1 (IL-1) B, IL-6, and tumor necrosis factor release in active microglia and astrocytes while inhibiting IL-10 release. Evidence is inconsistent in humans, but many studies on rodents have shown that a single exercise temporarily neutralizes GSK-3. Also, cytokines secreted from contracted muscle cells were found to have more anti-inflammatory properties.⁵

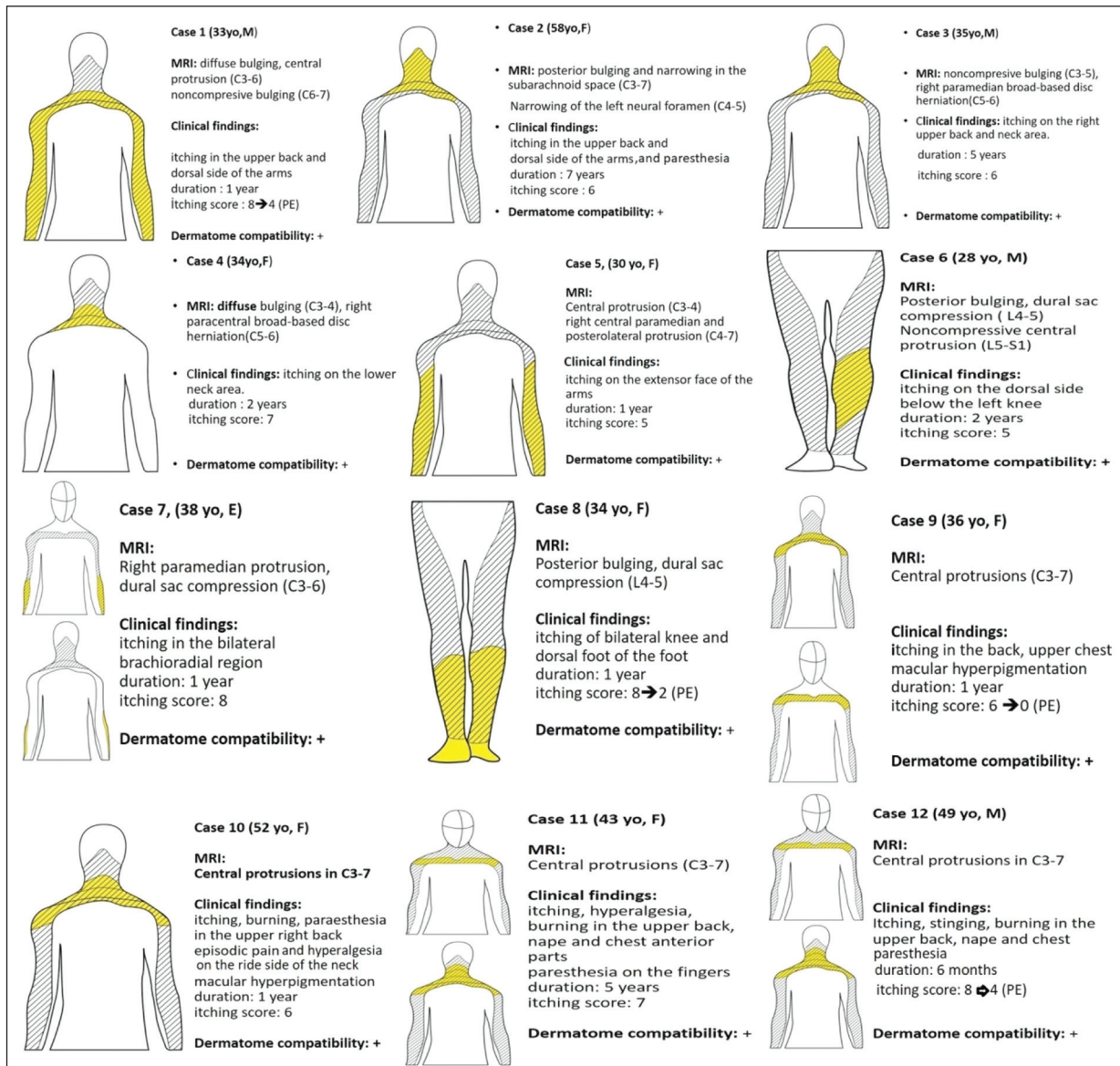


FIGURE 2: Summary of cases.

MRI: Magnetic resonance imaging; SAS: Subaracnoid space; PE: Post-exercise. The area marked yellow indicates the site where the itch is localized. The hatched regions express the dermatomal distribution of spinal pathology detected in MRI.

These findings suggest that exercises may have positive aspects of neuropathic pain and neuropathic itching.

CONCLUSION

We believe that it can be understood whether this method is beneficial by preparing standardized and easily applicable exercise models and making multicentric controlled studies that can provide a sufficient number of cases. If evidenced by advanced clinical

studies, muscle strengthening and stretching exercises can be chosen in the primary treatment of localized neuropathic itching or adjunct to other medical therapies.

Source of Finance

During this study, no financial or spiritual support was received neither from any pharmaceutical company that has a direct connection with the research subject, nor from a company that provides or produces medical instruments and materials which may negatively affect the evaluation process of this study.

Conflict of Interest

No conflicts of interest between the authors and / or family members of the scientific and medical committee members or members of the potential conflicts of interest, counseling, expertise, working conditions, share holding and similar situations in any firm.

Authorship Contributions

Idea/Concept: Semih Güder; **Design:** Semih Güder; **Control/Supervision:** Hüsnü Güder; **Data Collection and/or Processing:** Semih Güder; **Analysis and/or Interpretation:** Hüsnü Güder; **Literature Review:** Semih Güder; **Writing the Article:** Semih Güder; Hüsnü Güder; **Critical Review:** Hüsnü Güder.

REFERENCES

1. Rajagopalan M, Saraswat A, Godse K, Shankar DS, Kandhari S, Shenoi SD, Tahiliani S, Zavar VV. Diagnosis and Management of Chronic Pruritus: An Expert Consensus Review. *Indian J Dermatol.* 2017;62(1):7-17. [[Crossref](#)] [[PubMed](#)] [[PMC](#)]
2. Misery L, Brenaut E, Le Garrec R, Abasq C, Genestet S, Marcorelles P, et al. Neuropathic pruritus. *Nat Rev Neurol.* 2014;10(7):408-16. [[Crossref](#)] [[PubMed](#)]
3. Şavk E. Neurologic itch management. *Curr Probl Dermatol.* 2016;50:116-23. [[Crossref](#)] [[PubMed](#)]
4. Stumpf A, Ständer S. Neuropathic itch: diagnosis and management. *Dermatol Ther.* 2013;26(2):104-9. [[Crossref](#)] [[PubMed](#)]
5. Jeon K, Kim T, Lee SH. Effects of muscle extension strength exercise on trunk muscle strength and stability of patients with lumbar herniated nucleus pulposus. *J Phys Ther Sci.* 2016;28(5):1418-21. [[Crossref](#)] [[PubMed](#)] [[PMC](#)]
6. Oaklander AL. Common neuropathic itch syndromes. *Acta Derm Venereol.* 2012;92(2):118-25. [[Crossref](#)] [[PubMed](#)]
7. Ikoma A, Cevikbas F, Kempkes C, Steinhoff M. Anatomy and neurophysiology of pruritus. *Semin Cutan Med Surg.* 2011;30(2):64-70. [[Crossref](#)] [[PubMed](#)] [[PMC](#)]
8. Savk O, Savk E. Investigation of spinal pathology in notalgia paresthetica. *J Am Acad Dermatol.* 2005;52(6):1085-7. [[Crossref](#)] [[PubMed](#)]
9. Fleischer AB, Meade TJ, Fleischer AB. Notalgia paresthetica: successful treatment with exercises. *Acta Derm Venereol.* 2011;91(3):356-7. [[Crossref](#)] [[PubMed](#)]
10. Low R, Swanson LA, Swanson DL. Notalgia Paresthetica Relieved by Cervical Traction. *J Am Board Fam Med.* 2017;30(6):835-7. [[Crossref](#)] [[PubMed](#)]
11. Dobson JL, McMillan J, Li L. Benefits of exercise intervention in reducing neuropathic pain. *Front Cell Neurosci.* 2014;8:102. [[Crossref](#)] [[PubMed](#)] [[PMC](#)]
12. Reich A, Heisig M, Phan NQ, Taneda K, Takamori K, Takeuchi S, et al. Visual analogue scale: evaluation of the instrument for the assessment of pruritus. *Acta Derm Venereol.* 2012;92(5):497-501. [[Crossref](#)] [[PubMed](#)]
13. Goodkin R, Wingard E, Bernhard JD. Brachioradial pruritus: cervical spine disease and neurogenic/neuropathic [corrected] pruritus. *J Am Acad Dermatol.* 2003;48(4):521-4. [[Crossref](#)] [[PubMed](#)]
14. Steele J, Bruce-Low S, Smith D, Osborne N, Thorkeldsen A. Can specific loading through exercise impart healing or regeneration of the intervertebral disc? *Spine J.* 2015;15(10):2117-21. [[Crossref](#)] [[PubMed](#)]
15. Belavý DL, Albracht K, Bruggemann GP, Vergoesen PP, van Dieën JH. Can exercise positively influence the intervertebral disc? *Sports Med.* 2016;46(4):473-85. [[Crossref](#)] [[PubMed](#)]