

# Perioperative Assessment of Cerebral Oxygenation Using Near Infrared Spectroscopy in a Two Months-Old Infant with Hemitruncus Arteriosus: Case Report

## İki Aylık Hemitruncus Arteriozuslu Bebek Olguda Serebral Oksijenasyonun *Near Infrared Spektroskopi* Kullanılarak Perioperatif Değerlendirilmesi

Pelin KARAASLAN,<sup>a</sup>  
Banu VURAL GÖKAY,<sup>a</sup>  
Tijen ALKAN BOZKAYA,<sup>b</sup>  
Halil TÜRKÖĞLÜ<sup>b</sup>

Departments of  
<sup>a</sup>Anaesthesiology and Reanimation,  
<sup>b</sup>Cardiovascular Surgery,  
İstanbul Medipol University  
Faculty of Medicine, İstanbul

Geliş Tarihi/Received: 01.01.2013  
Kabul Tarihi/Accepted: 20.06.2013

Yazışma Adresi/Correspondence:  
Pelin KARAASLAN  
İstanbul Medipol University  
Faculty of Medicine,  
Department of Anaesthesiology and  
Reanimation, İstanbul,  
TÜRKİYE/TURKEY  
pkaraaslan@dr.com

**ABSTRACT** Hemitruncus arteriosus is a very rare congenital heart disease in which a branch of pulmonary artery originates from ascending aorta. Neurological outcome of a patient with hemitruncus arteriosus after the surgical procedure is a major point of interest for both the surgeon and the anaesthesiologist. Near infrared spectroscopy (NIRS) is one of the effective and noninvasive ways of demonstrating cerebral saturation. In this case report, a two months-old male infant with a right pulmonary artery originating from the ascending aorta who underwent surgery was presented. Beside routine invasive monitorization, NIRS was used for the assessment of cerebral oxygenation from induction of anaesthesia till the postoperative 2<sup>nd</sup> day. Obtained data from the monitoring of cerebral saturation was helpful during the surgical treatment of the disease.

**Key Words:** Monitoring, intraoperative; spectroscopy, near-infrared; truncus arteriosus

**ÖZET** Hemitruncus arteriozus; pulmoner arterin bir dalının asendan aortadan orijin aldığı, nadir görülen bir konjenital kalp hastalığıdır. Bu tip hastaların cerrahi işlem sonrası nörolojik durumu, hem cerrah hem de anesteziyoloğun önemli bir ilgi alanıdır. Near infrared spektroskopi (NIRS) (yakın-kızılötesi spektroskopi) serebral satürasyonu saptayan, etkin ve noninvaziv yöntemlerden birisidir. Bu olgu sunumunda; sağ pulmoner arteri asendan aortadan köken alan ve cerrahi uygulanan erkek cinsiyette iki aylık bir bebek sunuldu. Rutin invaziv monitorizasyon yanında, anestezi indüksiyonundan postoperatif 2. güne kadar, serebral oksijenasyonun değerlendirilmesi için NIRS kullanıldı. Hastalığın cerrahi tedavisi sırasında, serebral satürasyonunun monitorizasyonundan sağlanan veriler yararlı oldu.

**Anahtar Kelimeler:** İzlem, intraoperatif; spektroskopi, yakın-kızılötesi; trunkus arteriozus

**Turkiye Klinikleri J Case Rep 2014;22(1):15-8**

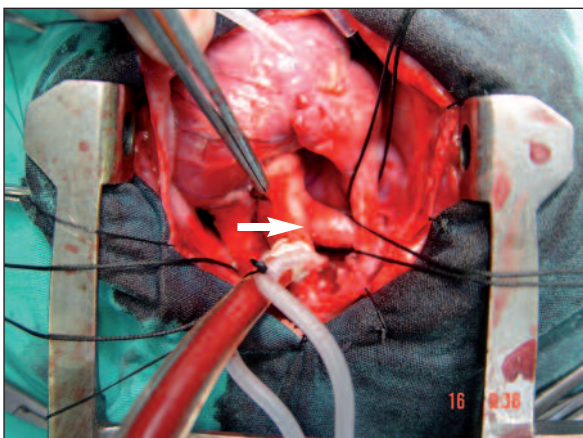
**H**emitruncus arteriosus is one of the rarest causes of pulmonary hypertension. One pulmonary artery branch, usually the right one, originates from the ascending aorta abnormally.<sup>1</sup> Repairing cases with hemitruncus arteriosus, as early as possible, concludes with excellent hemodynamic and anatomic results. Survival rates of infants who are operated for hemitruncus arteriosus are high and the reoperation risk is minimal.<sup>2</sup>

Perioperative monitoring of regional cerebral tissue oxygen saturation (rScO<sub>2</sub>) in patients with complex congenital cardiac abnormalities can be provided by using near infrared spectroscopy (NIRS).<sup>3</sup> The working principle of this noninvasive method depends on a nonpulsatile oxymeter to assess hemoglobin oxygen saturation.

In this case report, we presented a two months-old male infant who underwent surgery because of a right pulmonary artery originating from the ascending aorta. Beside routine invasive monitorization, we used NIRS for the assessment of cerebral oxygenation from induction of anaesthesia till the postoperative 2<sup>nd</sup> day. Data which was obtained from the monitoring of regional cerebral tissue saturation was presented and additionally we discussed the case with the literature.

## CASE REPORT

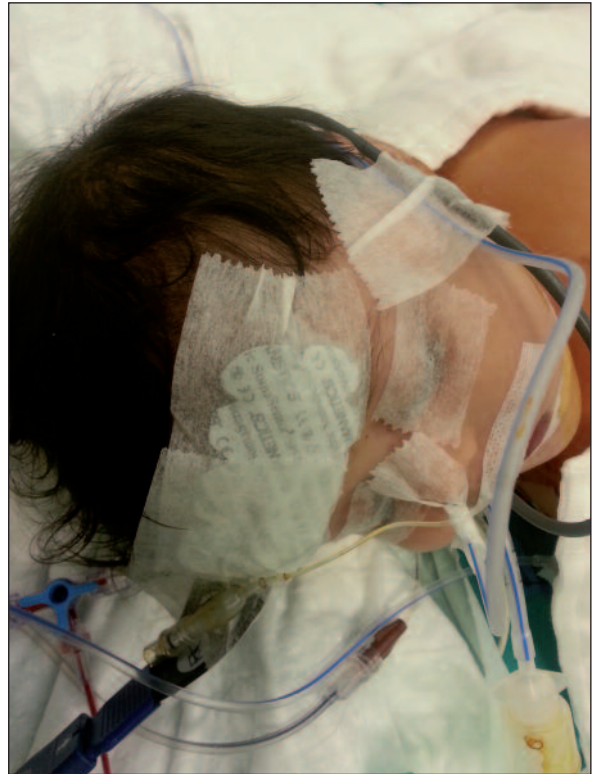A two months-old male infant, weighing 5000 g, was scheduled for surgery because of a congenital hemitruncus arteriosus. The planned surgery was total correction of the abnormality. His right pulmonary artery originated from arcus aorta (Figure 1). His preoperative laboratory values and preoperative neurological status were normal. After arrival into the operating room, routine monitoring including 5-lead electrocardiography (ECG), non invasive blood pressure and pulse oximetry was obtained before induction. Additionally, NIRS sensor (Invos Oximeter Somanetics) was placed on his forehead in order to monitorize cerebral oxygen saturation continuously (Figure 2). Anaesthesia induction was performed with sevoflurane in 100% oxygen (O<sub>2</sub>). After losing consciousness, peripheral venous access (22 G) was established. Fentanyl (5 µg/kg) and rocuronium (0.6 mg/kg) were adminis-



**FIGURE 1:** Right pulmonary artery originating from arcus aorta.

(See color figure at

<http://www.turkiyeklinikleri.com/journal/journal-of-medical-research-case-reports/1300-0284/>)



**FIGURE 2:** NIRS probe on the forehead of the patient.

(See color figure at

<http://www.turkiyeklinikleri.com/journal/journal-of-medical-research-case-reports/1300-0284/>)

tered intravenously. Intubation was performed with an endotracheal tube having an internal diameter of 3.5 mm. Maintenance of anaesthesia was provided with sevoflurane in a mixture of O<sub>2</sub> (50%) and air (50%). Pressure control mode was used for mechanical ventilation. Invasive arterial cannulation was established with a 24 G peripheral venous catheter via a radial artery. Obtained data from the first arterial blood gas analysis (FiO<sub>2</sub>: 0.5) was as follows; pH: 7.57, pO<sub>2</sub>: 100 mm, pCO<sub>2</sub>: 27 mmHg and Lactate: 1.3 mmol/L. End tidal CO<sub>2</sub> levels were between 26-30 mmHg. Right internal jugular vein was cannulated with a 4F central venous catheter for continuous monitoring of central venous pressure (CVP). CVP value was observed as 9 mmHg during that time.

Through median sternotomy, aortobicaval cannulation was applied for extracorporeal circulation. Antegrade blood cardioplegia was used for cardiac arrest. Then, right pulmonary artery and ascending aorta were divided. Aortotomy was clo-

sed with an autologous pericardial patch. Right pulmonary artery was anastomosed (end-to side) to the main pulmonary artery. During the post cardiopulmonary bypass (CPB) period, the patient was hemodynamically stable and had a normal sinus rhythm. Total cross clamp time was 30 minutes and total CPB time was 100 minutes. His last CVP was 12 mmHg and the results of last blood gas analyses were as follows; pH: 7.41, pO<sub>2</sub>: 97 mmHg, pCO<sub>2</sub>: 36 mmHg and Lactate: 2.2 mmol/L.

Throughout the surgery, continuous noninvasive cerebral oxygen saturation was monitored. All data was documented with extraordinary and significant results. NIRS values were 51% before induction, 33% just after induction, 36% at the time of sternotomy, 37% at the time of cannulation, 44% during cardiopulmonary bypass (CPB), 50% when cross clamp on and 50% when cross clamp off. During these measurements, neither hypotension nor global desaturation was observed. We thought that during the prebypass period cerebral desaturation was the result of the underlying pathology. So surgeons hurried up to start extracorporeal circulation. Cerebral oxygen saturation increased up to a value of 62% when CPB was ended, which meant that nearly 100% improvement was accomplished compared to the post-induction value. Cerebral oxygen saturation increased significantly after the end of CPB.

The trachea was extubated during the 6<sup>th</sup> postoperative hour. He stayed in the intensive care unit (ICU) for 2 days and NIRS values measured during ICU stay were >60%. He was discharged from the hospital at the 7<sup>th</sup> postoperative day without having any problem and neurological sequel.

## DISCUSSION

Hemitruncus arteriosus is a very rare congenital cardiac pathology in which a branch of pulmonary artery originates from ascending aorta. Co-existing malformations of the disease are patent foramen ovale, patent ductus arteriosus and ventricular septal defect.<sup>2</sup> In our case, none of these pathologies were found.

Nathan and his friends indicated in their study that early repairing of hemitruncus arteriosus results in successful hemodynamic and anatomic conditions. Reoperation and reintervention risks of these patients are minimal.<sup>2</sup> These successful cardiac results should not be disturbed by unintended neurological sequels. That is why the neurological outcomes of such cardiac surgery patients are the major point of interest for both the surgeons and the anaesthesiologists. It seems very important to know the values of cerebral oxygen saturation perioperatively to determine and prevent the desaturation periods and in case manage them as early as possible. Perfusion quality throughout the surgery, especially during CPB, is one of the determinants of the neurological outcome. Clinical studies support that continuous monitoring of regional cerebral oxygen saturation may improve neurological outcome and may prevent postoperative morbidities.<sup>4</sup>

Near infrared spectroscopy is one of the effective and noninvasive ways of demonstrating efficacy of cerebral perfusion. It may help clinicians to evaluate rScO<sub>2</sub>. It was clearly shown by the previous studies that cardiac output and central venous oxygen saturation had correlations with rScO<sub>2</sub>.<sup>3,5</sup> NIRS accuracy for cerebral saturation monitoring was supported by comparing internal jugular vein hemoglobin saturations, standard for assessing global cerebral saturation, in previous studies.<sup>4,6-8</sup> Continuous and real-time usage of NIRS may detect critical and inadequate brain tissue oxygenation.<sup>9</sup> Phelps et al., demonstrated that low rScO<sub>2</sub> measured by NIRS unfortunately had an association with poor prognosis.<sup>5</sup> An association between perioperative cerebral desaturation and postoperative neurological dysfunction was indicated. Also length of hospital stay was shown to be prolonged in desaturated patients.<sup>10,11</sup> Although our patient had low rScO<sub>2</sub> levels for approximately 30 minutes, his postoperative mental and motor functions were compatible to his month of age.

Dworschak Singer and Edmunds indicated the definition of critical cerebral desaturation as levels below 50% or a more than 20% decline from the

baseline levels.<sup>12,13</sup> Baseline values should be recorded when the patient is awake and while breathing room air. Setting baseline values is strongly needed in order to detect and manage declines. Our induction level was already less than 50% depending on the pathology itself which caused steal from aorta.

Major variations in general hemodynamic parameters strongly affect NIRS results. Drops in arterial blood pressure may result as cerebral desaturation.<sup>12</sup> Also low end tidal CO<sub>2</sub> levels may decrease cerebral perfusion. Clinicians usually prefer high frequency ventilations in infants and neonates. This may sometimes result with a low end tidal CO<sub>2</sub> level. We predict that in our case low end tidal CO<sub>2</sub> levels and pulmonary steal from aorta presented themselves as low cerebral saturation levels before total correction.

Major limitation of NIRS monitoring seems to be the fact that its expensiveness. NIRS needs a single-use sensor for each patient and sensor prices are extremely high. Cost/benefit analysis may result with incomparable costs because of any existing neurologic complication acquired long term rehabilitation programs.

Management of a intraoperative decrease of cerebral oxygen saturation and correcting underlying cause as early as possible may result with a decrease of major morbidity. Clinicians should never neglect the cerebral desaturations and should correct them quickly. The major point in mind should be that such desaturations may end as a neurological complication. In our case postoperative mental and motor functions were normal however neurological follow up should be continued. Cost effectiveness also should be in consideration. Preventing a major neurological complication may save both time and money. A successful cardiac surgery means not only a good cardiac outcome but also a complete recovery of the patient without any neurological sequel.<sup>14</sup>

In conclusion, real-time monitoring of regional cerebral tissue oxygen saturation using NIRS may help clinicians to detect, prevent and manage cerebral hypoperfusion. NIRS should take its place as one of the routine monitoring techniques especially for the cardiac surgical patients. In our case, data obtained from the monitoring of regional cerebral tissue saturation was helpful during the surgical treatment of the disease.

## REFERENCES

- Peng EW, Shanmugam G, Macarthur KJ, Pollock JC. Ascending aortic origin of a branch pulmonary artery--surgical management and long-term outcome. *Eur J Cardiothorac Surg* 2004;26(4):762-6.
- Nathan M, Rimmer D, Piercey G, del Nido PJ, Mayer JE, Bacha EA, et al. Early repair of hemitruncus: excellent early and late outcomes. *J Thorac Cardiovasc Surg* 2007; 133(5):1329-35.
- Ricci Z, Garisto C, Favia I, Schloderer U, Giorni C, Fragasso T, et al. Cerebral NIRS as a marker of superior vena cava oxygen saturation in neonates with congenital heart disease. *Paediatr Anaesth* 2010;20(11):1040-5.
- Booth EA, Dukatz C, Ausman J, Wider M. Cerebral and somatic venous oximetry in adults and infants. *Surg Neurol Int* 2010 Nov 27;1:75. doi: 10.4103/2152-7806.73316.
- Phelps HM, Mahle WT, Kim D, Simsic JM, Kirshbom PM, Kanter KR, et al. Postoperative cerebral oxygenation in hypoplastic left heart syndrome after the Norwood procedure. *Ann Thorac Surg* 2009;87(5):1490-4.
- Abdul-Khaliq H, Troitzsch D, Berger F, Lange PE. [Regional transcranial oximetry with near infrared spectroscopy (NIRS) in comparison with measuring oxygen saturation in the jugular bulb in infants and children for monitoring cerebral oxygenation]. *Biomed Tech (Berl)* 2000;45(11):328-32.
- Kim MB, Ward DS, Cartwright CR, Kolano J, Chlebowski S, Henson LC. Estimation of jugular venous O<sub>2</sub> saturation from cerebral oximetry or arterial O<sub>2</sub> saturation during isocapnic hypoxia. *J Clin Monit Comput* 2000; 16(3):191-9.
- Nagdyman N, Ewert P, Peters B, Miera O, Fleck T, Berger F. Comparison of different near-infrared spectroscopic cerebral oxygenation indices with central venous and jugular venous oxygenation saturation in children. *Paediatr Anaesth* 2008;18(2):160-6.
- Abdul-Khaliq H, Schubert S, Troitzsch D, Huebler M, Boettcher W, Baur MO, et al. Dynamic changes in cerebral oxygenation related to deep hypothermia and circulatory arrest evaluated by near-infrared spectroscopy. *Acta Anaesthesiol Scand* 2001; 45(6):696-701.
- Scheeren TW, Schober P, Schwarte LA. Monitoring tissue oxygenation by near infrared spectroscopy (NIRS): background and current applications. *J Clin Monit Comput* 2012;26(4):279-87.
- Murkin JM, Adams SJ, Novick RJ, Quantz M, Bainbridge D, Iglesias I, et al. Monitoring brain oxygen saturation during coronary bypass surgery: a randomized, prospective study. *Anesth Analg* 2007;104(1):51-8.
- Dworschak M. Critical cerebral oxygen desaturation: how should we define baseline saturation? *Eur J Anaesthesiol* 2012;29(7):351-2; author reply 352.
- Singer I, Edmonds HL Jr. Head-up tilt testing predicts syncope during ventricular tachycardia in implantable cardioverter-defibrillator patients. *J Intervent Cardiol* 1998; 11(5):205-11.
- Ömeroğlu SN, Yalvaç Denli ES. [Pediatric cardiovascular surgery and intensive care]. *Türkiye Klinikleri J Ped Surg* 2010;3(1):90-5.