

# Radiological Evaluation of the Posterior Superior Alveolar Artery on Cone Beam Computed Tomography Images: A Retrospective Study

## Konik Işınlı Bilgisayarlı Tomografi Kullanılarak Posterior Superior Alveolar Arterin Değerlendirilmesi: Bir Retrospektif Çalışma

Gülfem ÖZLÜ UÇAN<sup>a</sup>, Burak Kerem APAYDIN<sup>b</sup>, Derya İÇÖZ<sup>c</sup>

<sup>a</sup>İstanbul Gelişim University Faculty of Dentistry, Department of Maxillofacial Radiology, İstanbul, Türkiye

<sup>b</sup>Pamukkale University Faculty of Dentistry, Department of Maxillofacial Radiology, Denizli, Türkiye

<sup>c</sup>Selçuk University Faculty of Dentistry, Department of Maxillofacial Radiology, Konya, Türkiye

**ABSTRACT Objective:** The perfusion of the lateral wall of the maxillary sinus and the overlying membrane is provided by the posterior superior alveolar artery (PSAA) and infraorbital artery. The aim of our study is to evaluate the incidence, location, and diameter of PSAA in the lateral wall of the maxillary sinus due to its importance in surgical approaches involving the maxillary sinus. **Material and Methods:** In this study 300 maxillary sinuses were retrospectively analyzed in cone beam computed tomography (CBCT) images of 150 individuals. The presence of PSAA on the lateral wall of the maxillary sinus, its location was evaluated and the diameter and its perpendicular distance to the inferior and medial walls of the maxillary sinus and the alveolar crest were measured on CBCT images. Data were statistically analyzed with descriptive statistics, Kruskal-Wallis, Mann-Whitney U, and Pearson chi-square tests. **Results:** PSAA was detected in 205 (68.3%) of 300 maxillary sinus. The PSAA diameter was measured as a minimum of 0.2 mm and a maximum of 4.10 mm. PSAA was observed as 20% superficial, 53.7% intraosseous and 26.3% intrasinus positioned. A statistically significant relationship ( $p=0.00$ ) was found between PSAA diameter, the perpendicular distances of PSAA from the inferior wall and alveolar crest, and gender. The increase in PSAA diameter and PSAA distance from the alveolar crest with age was found statistically significant ( $p=0.02$ ,  $p=0.34$ ). **Conclusion:** It is important to know the anatomy of the region to perform preoperative CBCT examination to achieve higher success in surgical procedures and to prevent vascular damage in the maxillary sinus.

**Keywords:** Maxillary artery;  
cone beam computed tomography;  
maxillary sinus

**ÖZET Amaç:** Maksiller sinüsün lateral duvarı ve üzerini örten membranın perfüzyonu, posterior superior alveolar arter (PSAA) ve infraorbital arter tarafından sağlanmaktadır. Çalışmamızın amacı, maksiller sinüsü ilgilendiren cerrahi yaklaşımlardaki önemi nedeniyle PSAA'nın maksiller sinüs lateral duvarındaki görülme sıklığını, yerleşimini ve çapını değerlendirmektir. **Gereç ve Yöntemler:** Bu çalışmada, 150 bireye ait konik ışınli bilgisayarlı tomografi (KIBT) görüntülerinde 300 maksiller sinüs retrospektif olarak analiz edilmiştir. KIBT görüntüleri üzerinde maksiller sinüs lateral duvarında PSAA'nın varlığı, konumu değerlendirilmiş ve PSAA'nın çapı, PSAA'nın maksiller sinüs inferior, mediyal duvarlarına ve alveoler krete olan dik uzaklıkları ölçülmüştür. Veriler tanımlayıcı istatistikler, Kruskal-Wallis, Mann-Whitney U ve Pearson ki-kare testleri kullanılarak istatistiksel olarak analiz edilmiştir. **Bulgular:** 300 maksiller sinüsün 205'inde (%68,3) PSAA tespit edilmiştir. PSAA çapı minimum 0,2 mm, maksimum 4,10 mm olarak ölçülmüştür. PSAA'nın %20 yüzeysel, %53,7 intraosseöz ve %26,3 intrasinüs yerleşimli olduğu görülmüştür. PSAA çapı, PSAA'nın inferior duvara ve alveol tepesine dik uzaklıkları ve cinsiyetler arasında istatistiksel olarak anlamlı ilişki ( $p=0,00$ ) bulunmuştur. Yaşla birlikte PSAA çapındaki ve PSAA'nın alveoler krete olan uzaklığındaki artış istatistiksel olarak anlamlı bulunmuştur ( $p=0,02$ ,  $p=0,34$ ). **Sonuç:** Cerrahi işlemlerde daha yüksek başarı elde etmek ve maksiller sinüste damar hasarını önlemek için ameliyat öncesi KIBT incelemesi yapmak için bölgenin anatomisini bilmek önemlidir.

**Anahtar Kelimeler:** Maksiller arter;  
konik ışınli bilgisayarlı tomografi;  
maksiller sinüs

**Correspondence:** Gülfem ÖZLÜ UÇAN

İstanbul Gelişim University Faculty of Dentistry, Department of Maxillofacial Radiology, İstanbul, Türkiye

**E-mail:** gozlu@gelisim.edu.tr



Peer review under responsibility of Türkiye Klinikleri Journal of Dental Sciences.

**Received:** 13 Dec 2023

**Received in revised form:** 06 Mar 2024

**Accepted:** 23 Apr 2024

**Available online:** 10 May 2024

2146-8966 / Copyright © 2024 by Türkiye Klinikleri. This is an open access article under the CC BY-NC-ND license (<http://creativecommons.org/licenses/by-nc-nd/4.0/>).

Maxillary sinus (MS), located in the body of the maxilla, is the largest of the paranasal sinuses.<sup>1</sup> Perfusion of the MS and Schneiderian membrane is carried out by the maxillary artery.<sup>2,3</sup>

The posterior superior alveolar artery (PSAA) and infraorbital artery, branching from the pterygopalatine part of the maxillary artery, provide perfusion of the lateral wall of the MS and the covering membrane. These two arteries then form extraosseous and intraosseous branches that anastomose with each other around the MS.<sup>3-5</sup> Surgical procedures such as implant surgeries, elevations of MS floor using the lateral wall tract, orthognathic surgeries, Caldwell-Luc operations and Le Fort I osteotomies are procedures where performed on the lateral MS wall.<sup>4,6</sup>

Knowing the MS anatomy, having knowledge about vascular nutrition and location of the arteries before surgical procedures are important factors in the success of these procedures, in preventing the PSAA artery from being traumatized during the operation, and in preventing perioperative bleeding.<sup>7,8</sup>

MS expansion with the increase of pneumatization due to tooth loss with advancing age, alveolar bone resorption and past operations associated with this region lead to positional changes in vascular structures. These may cause traumatization of PSAA and bleeding during surgical interventions.<sup>6,9,10</sup>

3D imaging techniques are reported to be very useful techniques for visualizing the MS anatomically. Each technique has its own indications when performing radiographic imaging. These include accessibility, cost, radiation dose, and tissue to be imaged.<sup>8,11</sup>

Cone beam computed tomography (CBCT) is a digital imaging method that was introduced to the field of dentistry in the late 90s and has superior benefits in terms of hard tissue imaging. With CBCT, it is possible to obtain accurate information about bone morphology and anatomical landmarks. In addition, the lower radiation dose compared to computed tomography (CT) is known as a significant advantage for CBCT.<sup>8,11</sup>

The aim of this study is to evaluate the frequency of PSAA in the lateral MS wall and, when PSAA is present, its diameter and course in the MS wall, by

CBCT due to its importance in surgical approaches involving the MS.

In addition, determining the perpendicular distances of the MS floor, the crest and the medial MS wall, it is important to make accurate planning for surgical interventions such as sinus lifting and the placement of dental implants and to prevent possible clinical difficulties such as bleeding in these procedures.

## MATERIAL AND METHODS

This study was conducted in accordance with the Declaration of Helsinki and was ethically approved by the Pamukkale University Non-Interventional Clinical Research Ethics Committee (date: October 18, 2022; no: E-60116787-020-279098). The sample number of the study was calculated using the G\*Power 3.1.9.7 program. In the calculation made according to the statistical analyzes used in the study, the sample size was determined as at least 204, taking Cohen's medium effect size of 0.25 ( $d=0.30$ ), 5% margin of error ( $\alpha=0.05$ ) and 85% power ( $1-\beta=0.85$ ).

In the study, CBCT images taken for different reasons between May 2021 and January 2022 at Pamukkale University Faculty of Dentistry, Department of Oral and Maxillofacial Radiology were retrospectively analyzed.

CBCT images of individuals older than 18 years, free of artifacts, taken in the correct position, clearly evaluable, and the entire MS was entered in the examination area were included in the study. Presence of artifacts that make the images insufficient for comprehensive evaluation (foreign body artifact, artifacts due to positioning during shooting, motion artifact, etc.), images in which the entire MS does not included the examination area were excluded from our study. Moreover, the patients with craniofacial syndrome in the examination area, cleft lip and palate patients who have undergone orthognathic surgery, patients with metals (reconstruction plate, mini plate, mini screw, etc. used for fracture fixation) and CBCT images of individuals with cystic or tumoral formations were excluded from our study. In this study 300 maxillary sinuses of randomly selected 150 individuals (60 male, 90 female) who met the inclusion and

exclusion criteria were retrospectively analyzed. The total sample was classified in four age groups (18-35 years as Group 1, 36-50 years as Group 2, 51-65 years as Group 3, and over 66 years of age as Group 4). The ages of the individuals included in the study ranged between 18 and 80 and the average age was determined as  $46.48 \pm 16.66$ .

CBCT images were acquired on a NewTom 5G XL device (Quantitative Radiology systems, Verona, Italy) with scanner parameters maximum 110 kV and 6 mA, 0.25 mm voxel size, and approximately 3.6 s exposure time and field of view of  $18 \times 16$  or  $15 \times 12$  cm. CBCT examinations were performed on axial, coronal and sagittal images in multiplanar reconstructions in NNT Viewer software (Quantitative Radiology systems, Verona, Italy). Measurements on CBCT images were performed separately by an oral and maxillofacial radiologist with three years of experience. Any contradictions in the reviews are resolved by consensus with the participation of a licensed specialist with 13 years of experience.

Measurements were made on the coronal section where PSAA was most clearly displayed on CBCT images. In cases where PSAA was observed on the lateral wall of MS, it was defined as intraosseous, intrasinus and superficial according to location.<sup>11</sup> These locations are seen in Figure 1.

Then its diameter, and its perpendicular distance to the alveolar bone and inferior wall and medial wall

of the MS were measured.<sup>5,6</sup> Figure 2 shows measurements of the diameter the on coronal section where PSAA is most clearly visible.

SPSS software [SPSS, Inc., Chicago, IL, USA, (v 22.0)] was used in the analysis of the data. The data were statistically analyzed with descriptive statistics, Kruskal-Wallis, Mann-Whitney U and Pearson chi-square tests, and the  $p < 0.05$  level was considered statistically significant.

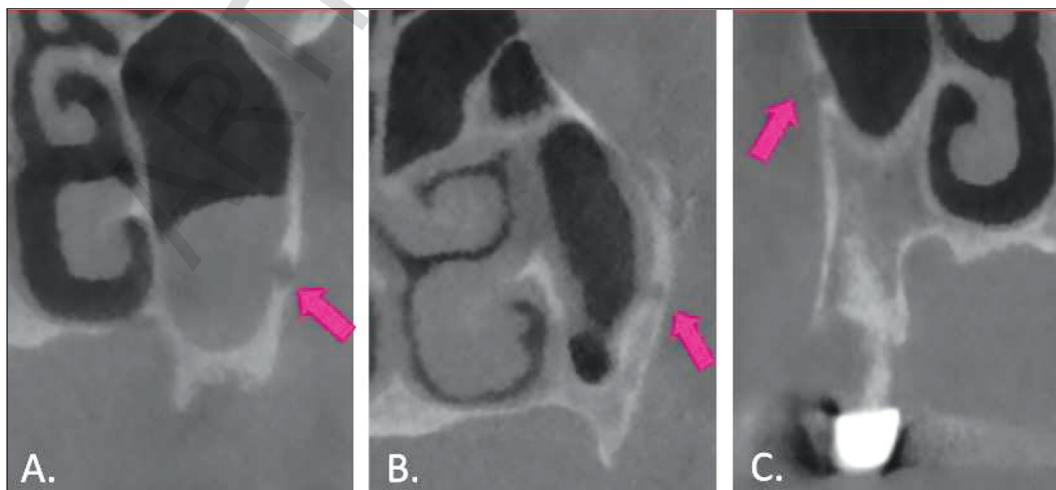
## RESULTS

PSAA was observed in 205 (68.3%) of the 300 evaluated MS. There was no significant relationship between the incidence of PSAA and age groups ( $p = 0.106$ ).

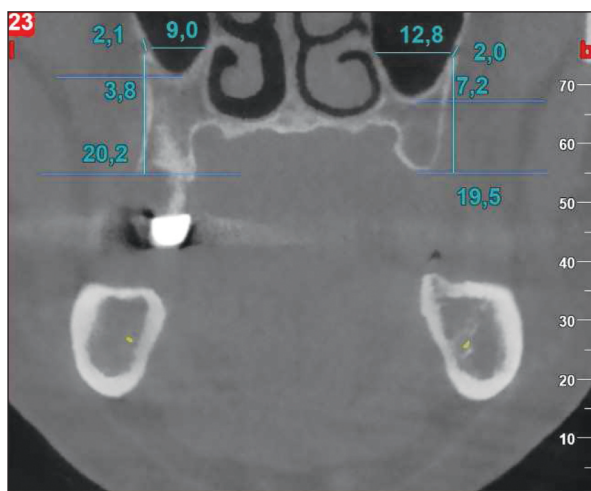
PSAA was observed in 20% superficial, 53.7% intraosseous, and 26.3% intrasinus localization. There is no significant relationship between PSAA localization types and genders as in Table 1.

The PSAA diameter was measured between 0.2 mm and 4.10 mm as shown in Table 2. There was statistically significant relationship ( $p = 0.000$ ) between the genders in terms of PSAA diameter as in Table 3. While the increase in PSAA diameter with age was statistically significant ( $p = 0.02$ ) as shown in Table 4.

The perpendicular distance of the PSAA to inferior wall was measured as a min 0.10 mm and a maximum of 19.50 mm as shown in Table 2. There



**FIGURE 1:** Location of PSAA in the maxillary sinus. **A)** Intraosseous location, **B)** Intrasinus location, **C)** Superficial location. PSAA: Posterior superior alveolar artery.



**FIGURE 2:** Measurements of the diameter on the coronal section where PSAA is most clearly visible.

PSAA: Posterior superior alveolar artery.

was statistically significant relationship ( $p=0.000$ ) between the genders in terms of inferior wall as shown in Table 3.

Perpendicular PSAA distance to medial wall was measured as a minimum of 0.80 mm and a maximum of 20.50 mm as shown in Table 2. No statistically significant relationship between the genders was observed for the perpendicular distance to the medial wall of MS ( $p=0.742$ ) shown in Table 3.

Perpendicular PSAA distance to the alveolar crest was measured as a minimum of 7.80 mm and a maximum of 17.55 mm shown in Table 2. There was statistically significant relationship ( $p=0.000$ ) between the genders in terms of the perpendicular distances of PSAA to the alveolar crest. While the

**TABLE 1:** PSAA localization and the relationship between genders.

		PSAA localization			Total	p value
		Superficial	Intraosseous	Intrasinus		
Gender	Female	20 (17.1%)	67 (57.3%)	30 (25.6%)	117	0.394
	Male	21 (23.9%)	43 (48.9%)	24 (27.3%)		
	Total	41 (20%)	110 (53.7%)	54 (26.3%)		

\*Chi-square test; \*\* $p<0.05$ ; PSAA: Posterior superior alveolar artery.

**TABLE 2:** Measurements of PSAA diameter and perpendicular distances.

	Minimum (mm)	Maximum (mm)	$\bar{X}\pm SD$ (mm)
PSAA diameter	0.20	4.10	0.98 $\pm$ 0.55
Perpendicular distance of the PSAA to inferior wall	0.10	19.50	7.86 $\pm$ 3.71
Perpendicular distance of the PSAA to medial wall	0.80	20.50	12.89 $\pm$ 3.06
Perpendicular distance of the PSAA to the alveolar crest	7.80	33.50	17.55 $\pm$ 4.26

PSAA: Posterior superior alveolar artery; SD: Standard deviation.

**TABLE 3:** The relationship between the measurements of PSAA and the genders.

	Gender	n	$\bar{X}\pm SD$	p value
PSAA Diameter	Male	88	1.16 $\pm$ 0.61	0.000**
	Female	117	0.86 $\pm$ 0.45	
Perpendicular distance of the PSAA to inferior wall	Male	88	9.16 $\pm$ 3.84	0.000**
	Female	117	6.87 $\pm$ 3.30	
Perpendicular distance of the PSAA to the alveolar crest	Male	88	18.96 $\pm$ 4.32	0.000**
	Female	117	16.50 $\pm$ 3.91	
Perpendicular distance of the PSAA to medial wall	Male	88	13.04 $\pm$ 2.92	0.742
	Female	117	12.77 $\pm$ 3.20	

\*Mann-Whitney U test; \*\* $p<0.05$ ; PSAA: Posterior superior alveolar artery; SD: Standard deviation.

**TABLE 4:** The relationship between the measurements of PSAA and the age groups.

		n	$\bar{X}\pm SD$	Minimum	Maximum	p value
PSAA diameter	Group 1	54	0.88±0.54	0.40	3.10	0.020**
	Group 2	48	0.90±0.48	0.30	2.40	
	Group 3	72	1.06±0.61	0.20	4.10	
	Group 4	31	1.09±0.47	0.50	2.20	
	Total	205	0.99±0.55	0.20	4.10	
Perpendicular distance of the PSAA to inferior wall	Group 1	54	7.41±3.62	1.80	19.50	0.535
	Group 2	48	7.98±3.40	0.10	17.00	
	Group 3	72	7.73±3.69	1.00	15.80	
	Group 4	31	8.74±4.38	1.00	19.00	
	Total	205	7.86±3.71	0.10	19.50	
Perpendicular distance of the PSAA to the alveolar crest	Group 1	54	16.26±4.52	8.20	29.80	0.034**
	Group 2	48	17.81±3.53	8.50	24.30	
	Group 3	72	18.25±4.82	7.80	33.50	
	Group 4	31	17.79±2.91	11.00	24.50	
	Total	205	17.56±4.27	7.80	33.50	
Perpendicular distance of the PSAA to medial wall	Group 1	54	13.71±3.05	5.00	20.00	0.051
	Group 2	48	12.30±3.30	0.80	20.00	
	Group 3	72	12.69±3.11	4.00	20.50	
	Group 4	31	12.83±2.50	8.00	18.80	
	Total	205	12.89±3.09	0.80	20.50	

\*Kruskal-Wallis test; \*\*p<0.05; PSAA: Posterior superior alveolar artery; SD: Standard deviation.

increase in alveolar crest distance with age was statistically significant ( $p=0.034$ ) as shown in Table 4.

## DISCUSSION

In cases such as implant surgery, surgical procedures in the MS area, the anatomy of region and vascular nutrition should be carefully evaluated in order to ensure the success of the operation and to prevent peri-operative bleeding.<sup>6,7</sup>

Many studies have been conducted in the literature to evaluate the incidence and location of PSAA. In these studies, methodologies such as CT, CBCT images and evaluation of cadavers were followed.<sup>2-6,8,11-17</sup>

In our study, a total of 300 MS of 150 individuals, were evaluated. The PSAA prevalence in the 300 evaluated maxillary sinuses was 68.3%.

The prevalence of PSAA in studies with CT were reported as 47% by Rosano et al. in 100 patient 200 sinuses, 52 % by Kim et al. in 200 patient 400 sinuses, 64.5% by Güncü et al. in 121 patient 242 si-

nuses, and CBCT were reported as 52.8% by Jung et al. in 250 patient 500 sinuses, 60.58% by Danes-Sani et al. in 430 patient 860 sinuses, 61% by Aksoy et al. in 300 patient 600 sinuses, 70% by Pandharbale et al. 50 patient 100 sinuses, 71% by Chitsazi et al. in 200 patient 400 sinuses, 87% by Tehranchi et al. in 300 patient 600 sinuses, 89.3% by Ilgüy et al. 135 in patient 270 sinuses.<sup>4-6,8,11-14,18,19</sup>

Differences in prevalence between studies may be caused by the population in which the study was directed, the coronal sections in which PSAA was evaluated, and the parameters of the devices was used.

The prevalence of PSAA in cadaver studies in the literature has been reported as 100%.<sup>2,3,5,15-17</sup> The reason why the prevalence of PSAA in studies performed with CBCT images is lower than in cadaver studies, is the difficulty in radiological evaluation of PSAA, which has a very small diameter, and the difficulty in evaluating PSAA in all cases. It may be that it is not always possible to evaluate with CBCT because it can sometimes progress through the soft tis-



---

sue rather than intraosseous, superficial or intrasinus located on the MS lateral wall.<sup>5</sup>

In our study, although the PSAA prevalence 65% in women and 73.3% in men, there was a slight male tendency, but according to the results of our study, there was no statistically significant difference between PSAA prevalence and gender. Consistent with our study, in the literature, Kim et al. noticed that PSAA was more common in males than females.<sup>18</sup> They also evaluated the relationship between age and PSAA prevalence. The prevalence of PSAA was reported that 56% in the group of individuals aged 45 to 55 and 48% in the group of people aged 56 to 65, however the researchers found no statistically significant difference between these rates.<sup>18</sup> Similarly, Ilgüy et al, reported that there was no statistically significant relationship between age and PSAA prevalence.<sup>11</sup> Age groups and PSAA prevalence were not significantly correlated in our results, which is consistent with the literature.

In our study, it was determined that the most common localization of PSAA was intraosseous with 57.3%, followed by intrasinus with 26.3% and superficial with 20%. In the literature, consistent with our study, Tehranchi et al 47%, Danesh-Sani et al. 69.6%, Ilgüy et al. 71% and Chitsazi et al. reported that 73.2% PSAA was detected in intraosseous localization.<sup>8,11,13,14</sup>

In our study, PSAA was most frequently observed as intraosseous localized in both men and women. In our study, the relationship between gender and the location type of PSAA was analyzed with the chi-square test, and no statistically significant relationship was found. Ilgüy et al. reported in their study that superficial localization was observed at a rate of 10% in men and 1.9% in women, and this difference between the genders in superficial location was statistically significant.<sup>11</sup> In our study, although superficial localization tended to be slightly higher in men (23.9% in men, 17.1% in women), this difference was not statistically significant. The male-female distribution of the individuals which constitute our study population may be the cause of this disparity.

In our study, the lowest PSAA diameter was 0.20 mm and the highest was 4.10 mm. The mean was found to be 0.98 mm. In the literature, PSAA has

been reported in diameters ranging from 0.94 to 1.37 mm on average.<sup>8,11,13,14,18</sup> Differences in the methodology of the studies and the cross-sectional level referenced for measurement may be the reason why the averages presented in the literature are so different.

PSAA diameter and age were evaluated in this study, a significant relationship was found between PSAA diameter and age, contrary to the study of Danesh-Sani et al.<sup>13</sup> This result may be due to differences in the study population.<sup>13</sup>

According to the findings of our study, a significant relationship was found between gender and PSAA diameter. PSAA diameter was found to be larger in males, consistent with the results reported in the literature.<sup>8,13,18</sup>

In this study, the distance of the PSAA perpendicular to the alveolar crest was measured and the minimum was 7.8 and the maximum was 33.5 mm. Its average was calculated as 17.55 mm. In the literature, cadaver studies have reported this value as 18.9-19.6 mm.<sup>2,3</sup> In studies performed with CBCT, the distance of PSAA to the alveolar crest was on average determined as 16.17 mm by Chitsazi et al., and by Tehranchi et al. 16.7 mm., Ilgüy et al. reported 16.88 mm.<sup>8,11,14</sup> The value we found in our study is less than cadaver studies and more than other CBCT studies. The reason for this difference may be due to the fact that the resorption pattern in the alveolar crest differs from individual to individual and the reference points are different when measuring due to the methodology used.

Contrary to the Kim et al. and Ilgüy et al. investigations, we found a significant relationship between the distance of PSAA from the alveolar crest and gender in this study.<sup>11,18</sup>

The distance between alveolar crest and PSAA was found to be greater in male individuals in the study population. The reason for this difference may be the individual differences in the individuals that make up our study population, and the gender-related morphological differences in males and females.

In this study the relationship between the distance between PSAA and the alveolar crest and age was evaluated, although a significant relationship was found between these two parameters, this distance

does not show a linear increase with age. In contrast to our study Ilgüy et al. and Kim et al. did not report any significant relationship between these two parameters in their studies.<sup>11,18</sup>

In cases of missing teeth, resorption is also seen in the inferior the MS wall due to the pneumatization of MS. Therefore, the distance between PSAA and the MS inferior wall is a reliable measurement in determining the PSAA position.

In our study, mean distance of PSAA to the inferior MS wall was 7.86 mm. Among the studies in the literature, Danesh-Sani et al. reported 8.16 mm, Pandharbale et al. 8.16 mm, Ilgüy et al. 8.7 mm.<sup>11,13,19</sup> We found a lower value in our study than the studies in the literature. The reason for this may be due to the differences in the edentulous duration of the individuals in the study population and the differences in the resorption pattern in the MS.

In this study, the relationship between gender and the distance of the PSAA to the inferior MS wall was evaluated, a significant difference was found ( $p=0.00$ ). We found that this value is higher in men. The individual variances among the people that make up our study population and the anatomical disparities between males and females may be the cause of this discrepancy. In our study, the relationship between the age and distance of PSAA to the inferior MS wall was examined, no statistically significant difference was found.

In the present study, we found the average distance of the PSAA to the medial MS wall to be 12.89 mm. Pandharbale et al. reported the distance of PSAA to the medial MS wall as 14.67 mm on average for the right and 15.5 mm on average for the left in their study.<sup>19</sup> In our study, no significant relationship was found between the distance of PSAA to the medial MS wall and gender. Ilgüy et al. reported a significant relationship between the distance of PSAA to the medial MS wall and gender.<sup>11</sup>

The relationship between the distance of PSAA to the medial MS wall and age was examined, no statistically significant difference was found in our study. Contrary to our findings, a statistically significant relationship was reported in the study of Ilgüy et al.<sup>11</sup> The reason for this finding is thought to be due

to the individual differences in the study population examined.

The first limitation of our study is that the dentition status of the patient in the study was not taken into account. In addition, the measurements were obtained from the coronal section where the PSAA artery was most prominent, which is thought limits the scope of our investigation. In future studies, the first and last sections where PSAA can be detected in the sagittal direction can also be determined and its course at various levels can be evaluated.

## CONCLUSION

Since the PSAA is localized in the MS region, it is necessary to determine its exact location before the operations to be performed in the region, and to consider individual, age and gender variances. As a result of the examinations, we made in our study, it is clearly seen that CBCT is a good diagnostic tool for localizing PSAA. Therefore, our opinion is that with preoperative CBCT evaluation, high success can be achieved in surgical procedures to be performed in the region and vascular damage can be prevented.

### Source of Finance

*During this study, no financial or spiritual support was received neither from any pharmaceutical company that has a direct connection with the research subject, nor from a company that provides or produces medical instruments and materials which may negatively affect the evaluation process of this study.*

### Conflict of Interest

*No conflicts of interest between the authors and / or family members of the scientific and medical committee members or members of the potential conflicts of interest, counseling, expertise, working conditions, share holding and similar situations in any firm.*

### Authorship Contributions

**Idea/Concept:** Gülfem Özlü Uçan, Burak Kerem Apaydın; **Design:** Gülfem Özlü Uçan, Burak Kerem Apaydın, Derya İçöz; **Control/Supervision:** Burak Kerem Apaydın, Derya İçöz; **Data Collection and/or Processing:** Gülfem Özlü Uçan, Burak Kerem Apaydın; **Analysis and/or Interpretation:** Gülfem Özlü Uçan, Burak Kerem Apaydın, Derya İçöz; **Literature Review:** Gülfem Özlü Uçan; **Writing the Article:** Gülfem Özlü Uçan; **Critical Review:** Burak Kerem Apaydın, Derya İçöz; **References and Fundings:** Gülfem Özlü Uçan, Burak Kerem Apaydın, Derya İçöz; **Materials:** Gülfem Özlü Uçan, Burak Kerem Apaydın, Derya İçöz.

## REFERENCES

1. Kalyvas D, Kapsalas A, Paikou S, Tsiklakis K. Thickness of the Schneiderian membrane and its correlation with anatomical structures and demographic parameters using CBCT tomography: a retrospective study. *Int J Implant Dent.* 2018;4(1):32. PMID: 30338431; PMCID: PMC6193890.
2. Solar P, Geyerhofer U, Traxler H, Windisch A, Ulm C, Watzek G. Blood supply to the maxillary sinus relevant to sinus floor elevation procedures. *Clin Oral Implants Res.* 1999;10(1):34-44. PMID: 10196788.
3. Traxler H, Windisch A, Geyerhofer U, Surd R, Solar P, Firas W. Arterial blood supply of the maxillary sinus. *Clin Anat.* 1999;12(6):417-21. PMID: 10545857.
4. Güncü GN, Yıldırım YD, Wang HL, Tözüm TF. Location of posterior superior alveolar artery and evaluation of maxillary sinus anatomy with computerized tomography: a clinical study. *Clin Oral Implants Res.* 2011;22(10):1164-7. PMID: 21244499.
5. Rosano G, Taschieri S, Gaudy JF, Weinstein T, Del Fabbro M. Maxillary sinus vascular anatomy and its relation to sinus lift surgery. *Clin Oral Implants Res.* 2011;22(7):711-5. PMID: 21143535.
6. Aksoy S, Mısırlı M, Orhan K. Posterior superior alveolar arterin KIBT ile değerlendirilmesi [Evaluation of the posterior superior alveolar artery using CBCT]. *AÜDHF.* 2020;47(1-3):37-43. <https://dergipark.org.tr/tr/pub/audhfd/issue/60299/879717>
7. Ella B, Sédarat C, Noble Rda C, Normand E, Lauerjat Y, Siberchicot F, et al. Vascular connections of the lateral wall of the sinus: surgical effect in sinus augmentation. *Int J Oral Maxillofac Implants.* 2008;23(6):1047-52. PMID: 19216273.
8. Tehranchi M, Taleghani F, Shahab S, Nouri A. Prevalence and location of the posterior superior alveolar artery using cone-beam computed tomography. *Imaging Sci Dent.* 2017;47(1):39-44. PMID: 28361028; PMCID: PMC5370253.
9. Velasco-Torres M, Padial-Molina M, Alarcón JA, O'Valle F, Catena A, Galindo-Moreno P. Maxillary sinus dimensions with respect to the posterior superior alveolar artery decrease with tooth loss. *Implant Dent.* 2016;25(4):464-70. PMID: 27455429.
10. Khojastehpour L, Dehbozorgi M, Tabrizi R, Esfandnia S. Evaluating the anatomical location of the posterior superior alveolar artery in cone beam computed tomography images. *Int J Oral Maxillofac Surg.* 2016;45(3):354-8. PMID: 26516028.
11. İlğüy D, İlğüy M, Dolekoglu S, Fisekcioglu E. Evaluation of the posterior superior alveolar artery and the maxillary sinus with CBCT. *Braz Oral Res.* 2013;27(5):431-7. PMID: 24036981.
12. Jung J, Yim JH, Kwon YD, Al-Nawas B, Kim GT, Choi BJ, et al. A radiographic study of the position and prevalence of the maxillary arterial endosseous anastomosis using cone beam computed tomography. *Int J Oral Maxillofac Implants.* 2011;26(6):1273-8. PMID: 22167433.
13. Danesh-Sani SA, Movahed A, ElChaar ES, Chong Chan K, Amintavakoli N. Radiographic evaluation of maxillary sinus lateral wall and posterior superior alveolar artery anatomy: a cone-beam computed tomographic study. *Clin Implant Dent Relat Res.* 2017;19(1):151-60. PMID: 27238049.
14. Chitsazi MT, Shirmohammadi A, Faramarzi M, Esmaili F, Chitsazi S. Evaluation of the position of the posterior superior alveolar artery in relation to the maxillary sinus using the Cone-Beam computed tomography scans. *J Clin Exp Dent.* 2017;9(3):e394-e9. PMID: 28298981; PMCID: PMC5347288.
15. Choi J, Park HS. The clinical anatomy of the maxillary artery in the pterygopalatine fossa. *J Oral Maxillofac Surg.* 2003;61(1):72-8. PMID: 12524612.
16. Caraballo J, Gálvez A, Manzanares-Céspedes MC, Valdivia-Gandur I, Figueiredo R, Valmaseda-Castellón E. Vascular structures of the lateral wall of the maxillary sinus: a vascular labeling technique. *Implant Dent.* 2017;26(1):153-7. PMID: 28067755.
17. Kqiku L, Biblekaj R, Weiglein AH, Kqiku X, Städtler P. Arterial blood architecture of the maxillary sinus in dentate specimens. *Croat Med J.* 2013;54(2):180-4. PMID: 23630145; PMCID: PMC3641875.
18. Kim JH, Ryu JS, Kim KD, Hwang SH, Moon HS. A radiographic study of the posterior superior alveolar artery. *Implant Dent.* 2011;20(4):306-10. PMID: 21778887.
19. Pandharbale AA, Gadgil RM, Bhoosreddy AR, Kunte VR, Ahire BS, Shinde MR, et al. Evaluation of the posterior superior alveolar artery using cone beam computed tomography. *Pol J Radiol.* 2016;81:606-10. PMID: 28058075; PMCID: PMC5175788.