



# Brooks Method for the Treatment of a Traumatic Carotidocavernous Fistula and a Historical Perspective to Endovascular Interventions: A Case Presentation and a Literature Review

## Travmatik Karotikokavernöz Fistülün Brooks Yöntemi ile Tedavisi ve Endovasküler Girişime Tarihsel Bakış: Bir Olgu Sunumu ve Literatür İncelemesi

 Faruk ALTINEL,<sup>a</sup>  
 Cihan ALTIN<sup>b</sup>

Clinics of  
<sup>a</sup>Neurosurgery,  
<sup>b</sup>Cardiology,  
Başkent University  
İzmir Zübeyde Hanım Teaching and  
Medical Research Center,  
İzmir, TURKEY

Received: 08.06.2018  
Received in revised form: 12.11.2018  
Accepted: 30.11.2018  
Available online: 03.12.2018

Correspondence:  
Faruk ALTINEL  
Başkent University  
İzmir Zübeyde Hanım Teaching and  
Medical Research Center,  
Clinic of Neurosurgery, İzmir,  
TURKEY/TÜRKİYE  
farukaltinel@gmail.com

**ABSTRACT** A carotidocavernous fistula is an abnormal communication between the internal or external carotid arteries and the cavernous sinus. This case report presents a patient with a carotid-cavernous sinus (CCSF) fistula, diagnosed and treated at a time when the endovascular interventions were not commonly performed. The diagnosis was made by evaluating the clinical symptoms and with a conventional percutaneous angiography of the right internal carotid artery (ICA). The patient was treated with the embolization of CCSF with a “free” piece of muscle (Brooks Method). The clinical symptoms of the patient were evaluated and noted before, during, and after the operation. The benefits of new technological products and devices on patient recoveries were reviewed with respect to the literature.

**Keywords:** Traumatic; carotidocavernous fistula; Brooks method

**ÖZET** Karotikokavernöz fistül, internal veya eksternal karotis arterler ile kavernöz sinüsler arasında oluşan anormal kan akımı geçişi sonucu ortaya çıkar. Bu makalede; endovasküler girişimlerin etkili olarak uygulanmadığı bir dönemde, klinik bulguları ve konvansiyonel perkütan sağ karotis anjiyografi tekniği ile tanısı konan bir olguya, cerrahi olarak, internal karotis arter yolu ile serbest adale embolizasyonu (Brooks tekniği) uygulandı. Olgunun ameliyat öncesi, esnası ve sonrası klinik bulgularında olan düzleme ile yeni teknoloji ürünlerinin ve cihazlarının hasta iyileşmesine olan katkıları gözden geçirildi.

**Anahtar Kelimeler:** Travmatik; karotikokavernöz fistül; Brooks tekniği

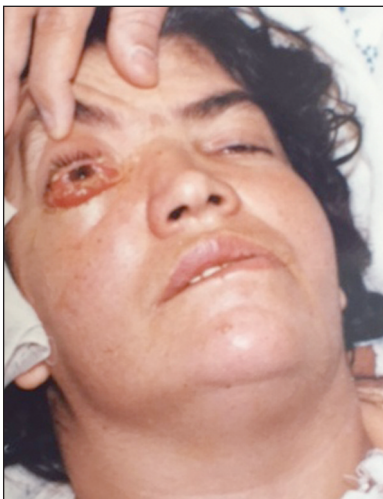**C**arotidocavernous fistulas (CCF) are abnormal arteriovenous anastomoses between the internal carotid artery (ICA) and the cavernous sinus.<sup>1</sup> CCF can be classified according to the aetiology (spontaneous or traumatic), flow rates (high or low speed), or anatomical characteristics (direct or indirect arterial supply).<sup>1</sup> The most widely used classification is the one made according to the arterial supply to CCF. A traumatic arteriovenous fistula is most frequently seen in the craniofacial area injuries. It is easy to identify arteriovenous fistulas occurring between the ICA, their branches, and the cavernous sinus with the characteristic symptoms of visual loss, exophthalmos, orbicular pulse, extraocular muscle paralysis, and an orbital blowout fracture.<sup>2</sup> In this article, a patient suffering from a traumatic carotid-cavernous sinus fistula treated with the Brooks method was presented.

## CASE REPORT

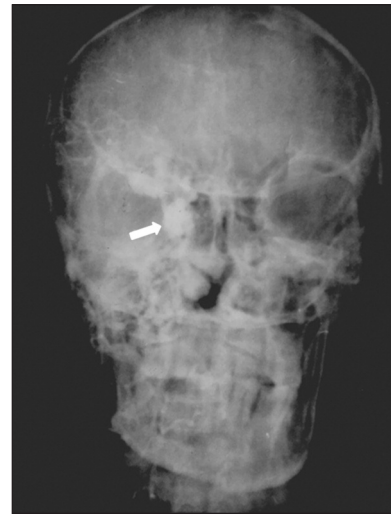
A 35-year-old woman was admitted to the hospital with the complaints of somnolence, visual loss, and subconjunctival hemorrhage in the right eye developing 2 months after a traffic accident. In the neurological examination, drowsiness was observed and she had a Glasgow Coma Scale (GCS) score of 7. In the physical examination; a pulsatile exophthalmos, restrictions in the upwards and downwards gaze, systolic murmur on the orbicular and frontal regions, chemosis, and a facial paralysis on the left were identified. Excluding a mandibular fracture on the left, the computed tomography (CT) findings were normal (Figure 1). A right internal carotid angiogram was performed with a percutaneous technique, revealing the drainage into the cavernous sinus along with an expansion of the cavernous sinus and the superior ophthalmic vein (Figures 2, 3). A left carotid angiogram was performed in the same session (**the cross compression technique**) due to the external compression to the right carotid artery, demonstrating that the left ICA supplied the arterial blood to the right cerebral hemisphere.

## OPERATION TECHNIQUE

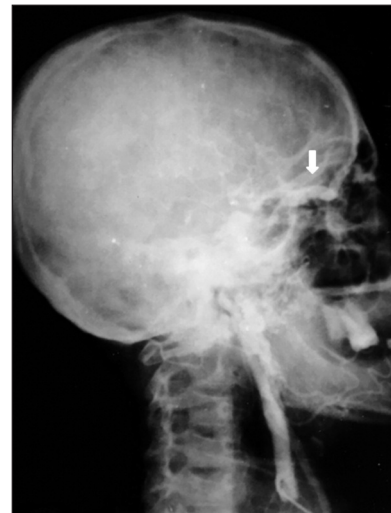The patient was prepared for the operation in the supine position. After administering general anesthesia, an oblique skin incision was performed in



**FIGURE 1:** Preoperative findings including the restriction of the gaze in the right eye, exophthalmos, chemosis, and proptosis.



**FIGURE 2:** Percutaneous angiography (anteroposterior) of the right common carotid artery and traumatic carotid-cavernous fistula



**FIGURE 3:** Percutaneous angiography (lateral) of the right common carotid artery with superior ophthalmic vein dilatation.

the sternocleidomastoid muscle. The right common carotid artery and the internal and external carotid arteries were clamped. A 2-cm-incision was made on the right internal carotid artery, and a Fogarty catheter was inserted into the artery through the incision. The catheter was inflated until the orbicular and frontal murmur stopped at the point where it was heard by auscultation with a stethoscope and a child fetoscope. The catheter length was measured by comparing it with the length of the deflated Fogarty catheter. Subsequently, the

muscle strip, attached to a silk thread in front of the balloon catheter, was proceeded in the part of the artery in the cranium, along with the distance calculated by the length of the deflated Fogarty catheter. At the point where the murmur stopped, as auscultated with a stethoscope and fetoscope, the proximal tip of the stripe-bound silk thread was fixed on the side wall of the carotid artery (Brooks Method). The orbicular and frontal murmur disappeared on the postoperative 1<sup>st</sup> day. No complications or neurological disorders developed due to the operation. It is noteworthy to remind that care should be exercised in managing the platelet aggregation in this kind of operations. The patient initially received subcutaneous heparin and then she was switched to receive acetylsalicylic acid treatment. On the fifth day after the operation, chemosis decreased and gradually disappeared. On the seventh day, the patient was discharged from the hospital. In the first month, the exophthalmos resolved completely. In the sixth month, a complete improvement in the eye symptoms was observed in the neurological examination. In the second postoperative year, it was revealed that the eye symptoms returned to normal and there were no neurological findings (Figure 4). The patient was lost to follow up for further control visits due to her socioeconomic conditions.

## DISCUSSION

A direct communication may often develop between the ICA and the cavernous sinus after

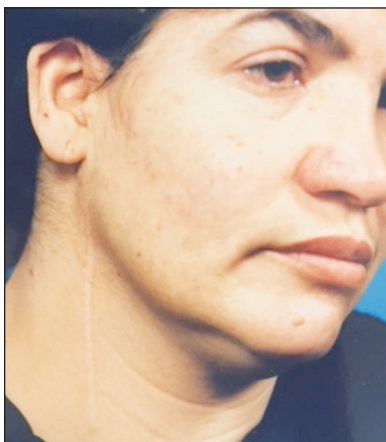

FIGURE 4: The patient in the 2<sup>nd</sup> year after the operation.

cranial traumas or aneurysm ruptures.<sup>1,3-5</sup> CCF symptoms and sequelae occur due to the passage of arterial blood through the cavernous sinus and may result from the high flow rate in the fistula. The symptoms may include ophthalmoplegia, a limitation in the eye movements, decreased visual acuity, and intracranial haemorrhage.<sup>2</sup>

The aetiology and the treatment of pulsatile exophthalmos developing due to the CCF were discussed in the literature in detail. Travers (1809) was the first to publish a carotid artery ligation. However, the recovery rate in complete carotid artery ligations is less than 30%.<sup>6</sup> The mortality rate was reported to be 7% in the common carotid artery ligations and 9.4% in the internal carotid artery ligations. The trapping operations were introduced by Hamby and Gardner (1932). The recovery rates after either the trapping operations with or without the use of embolization (Zeller 1911) or the combination of the two kinds of operations are higher than that of the single or combined ligation of the carotid artery in the neck region.<sup>6</sup> Although Hamby reported a recovery rate of 94%, the likelihood of risks with the intracranial approaches such as trapping and transcavernous high, especially in the patients at old ages.

To avoid the risk of craniotomy, some authors may prefer performing percutaneous or surgical methods only in the anterior neck. Vitek and Smith published a brief history of the Brooks method in the literature.<sup>7</sup> In 1930, Brooks was to first touse a long muscle band through the internal carotid artery to embolize a CCF. This method was interpreted as a real revolution at that time and arterial and venous occlusions were started to be treated with procedures distant to fistulas. Although Brooks reported successful results after the internal occlusion of fistulas with the Fogarty catheter technique, a careful discussion on the following issues should be performed for selected patients, including the closure of the fistula entirely, the lack of blood flow in the main vein involved in the development of a fistula, and whether the transcavernous approach should be used. Hamby and Gardner (1931) introduced a modification to this technique, using a radio-visible embolic clip as a

radio-marker for embolization. Embolization can be an ideal procedure as long as the size of the fistula is carefully determined. If the embolic material is small, it may proceed into the carotid sinus or into the cerebral circulation. If the embolic material is large, it may block the internal carotid artery without reaching the fistula<sup>6</sup>. However, these methods are not the only intervention options for the treatment of carotid-cavernous fistulae.

Lussenhopp et al. (1960) improved the technique of Brooks method by embolizing arteriovenous malformations with plastic balls. In 1964, for the first time, they closed the orifice of a supraclinoid segment aneurysm by placing an inflatable silicone balloon and placed a second balloon into the supraclinoid part of the carotid artery. Since the balloon was directed by the catheter in the vein and difficult to control, Alksne and Yodh (1968) attempted to solve these problems with a balloon catheter controlled by an electromagnetic system.

With the advances in minimally invasive procedures, inflatable balloon techniques began to be used in the treatment of CCF. Prolo and Hambery (1971) inserted the Fogarty catheter into the internal carotid artery performing a minor surgical operation. Rougerie and Guilmet; and Lepoire and Picard (1974) inserted a percutaneous Fogarty catheter (3F) with a No. 205 needle in two and six patients, respectively. At these interventions, the catheter was rotated and cut, and the small skin incision was fixed subcutaneously.

Thanapura documented twelve cases treated for traumatic carotid-cavernous fistulas in his clinic in a 5-year-period showing that this procedure was still an appropriate therapeutic option.<sup>8</sup>

Serbinnenko (1971-1974) performed the intracranial arterial catheterization and micro-balloon techniques in the Burdenko Institute in Moscow in 36 patients with intraluminal occlusion of the intracavernous part of the carotid artery. Serbinnenko also achieved a balloon occlusion in the cavernous sinus of 25 patients unilaterally, reporting that the patients with CCF could be suc-

cessfully treated with the interventions applied via the carotid artery. The balloon application technique is always performed via the transarterial route, by placing the inflatable balloon in the cavernous sinus.<sup>1,2</sup> In our study, a transarterial route was used. Guided by the Fogarty catheter, the embolization was performed by advancing the balloon along the length of the bifurcation to obstruct it completely, while monitoring the cranial and orbital murmur by auscultation with a stethoscope and fetoscope. This method may be preferred when the imaging techniques (transcranial ultrasound, DSA or MRI angiography) are not available. In the present case reported in this article, the orbital murmur disappeared on the 1<sup>st</sup> postoperative day. On the 7<sup>th</sup> days and in the 6<sup>th</sup> month in the postoperative period, the murmur could not be detected during the ophthalmologic findings. There are rare cases in which the transarterial technique cannot be performed, including the small fistulas allowing the passage of a balloon or the presence of sharp bony edges with a potential of causing tears in the balloon during the inflation process.<sup>9</sup>

In parallel with the advancements in the diagnostic and treatment modalities, fistulas can currently be treated with platinum coils placed both in the arterial and venous cavernous sinuses.<sup>9,10</sup> In some patients, the fistula may not be fully closed, however, subtotal closures may also improve the symptoms of patients. On the contrary, the increased venous drainage into the ophthalmic and cortical venules with the use of balloons and coils may sometimes cause an exacerbation in the symptoms or may lead to an intracranial hemorrhage.

Some fistulas may not recover without completely interrupting the blood flow in the main vessel. In large fistulas, it may not be possible to place a balloon into the arterial fistula. In these cases where a balloon cannot be placed in the orifice of the arteriovenous shunt; a micro-balloon and a catheter may be inserted to ensure the control distally. A microcatheter inserted distal to the fistula and a temporary balloon placed in the artery of the same side may not be sufficient in achieving the de-

sired outcome due to the retrograde aggressive blood flow distal to the fistula. Then, the proximal fistula can be blocked with a detachable balloon, interrupting the blood flow in the carotid artery. Subsequently, a microcatheter can be introduced into the anterior communicating artery or the posterior communicating artery. In some cases, soft or ultra-soft GDC® detachable coils can be used to occlude the short distal segment of the carotid artery without occluding the posterior communicating artery or the anterior choroidal artery.

A retrograde catheterization of the carotid artery has been performed through the Circle of Willis, especially when a unilateral approach is contraindicated due to an occlusion in the proximal vessel.<sup>11-13</sup> When the communicating arteries are intact, this technique is quite beneficial. Distal closing is also performed by using ultra-soft coils with high-quality hydrophilic microcatheters. This type of coiling is performed readily in a heparinized patient. Other intracranial stent methods were developed as other options to be used in the interventions, such as the devices developed by Onyx.<sup>13-17</sup>

In summary, the historical methods used for the treatment of CCF include the methods performed at locations away from the fistula (carotid ligation and closure of venous structures in the

orbit), craniotomy requiring techniques (trapping, trapping with embolization, or transcavernous approaches), and the techniques without the use of a craniotomy (embolization performed via the structures in the neck, “Brooks method”, inflatable or detectable micro-ball techniques, intraluminal occlusion of the carotid artery or cavernous sinus occlusion).

#### Source of Finance

*During this study, no financial or spiritual support was received neither from any pharmaceutical company that has a direct connection with the research subject, nor from a company that provides or produces medical instruments and materials which may negatively affect the evaluation process of this study.*

#### Conflict of Interest

*No conflicts of interest between the authors and / or family members of the scientific and medical committee members or members of the potential conflicts of interest, counseling, expertise, working conditions, share holding and similar situations in any firm.*

#### Authorship Contributions

**Idea/Concept:** Faruk Altinel, Cihan Altın; **Design:** Faruk Altinel, Cihan Altın; **Control/Supervision:** Faruk Altinel, Cihan Altın; **Data Collection and/or Processing:** Faruk Altinel; **Analysis and/or Interpretation:** Faruk Altinel, Cihan Altın; **Literature Review:** Faruk Altinel, Cihan Altın; **Writing the Article:** Faruk Altinel; **Critical Review:** Cihan Altın; **Materials:** Faruk Altinel.

## REFERENCES

- Barrow DL, Spector RH, Braun IF, Landman JA, Tindall SC, Tindall GT. Classification and treatment of spontaneous carotid-cavernous sinus fistulas. *J Neurosurg* 1985;62(2):248-56.
- Lasjaunias P, Chiu M, ter Brugge K, Tolia A, Hurth M, Bernstein M. Neurological manifestations of intracranial dural arteriovenous malformations. *J Neurosurg* 1986;64(5):724-30.
- Debrun GM, Viñuela F, Fox AJ, Davis KR, Ahn HS. Indications for treatment and classification of 132 carotid-cavernous fistulas. *Neurosurgery* 1988;22(2):285-9.
- Phatouros CC, Meyers PM, Dowd CF, Halbach VV, Malek AM, Higashiyama RT. Carotid artery cavernous fistulas. *Neurosurg Clin N Am* 2000;11(1):67-84.
- Fattahi TT, Brandt MT, Jenkins WS, Steinberg B. Traumatic carotid-cavernous fistula: pathophysiology and treatment. *J Craniofac Surg* 2003;14(2): 240-6.
- Lang ER, Bucy PC. Brooks method. *J Neurosurg* 1965;22(4):387-92.
- Vitek JJ, Smith MJ. The myth of the Brooks method of embolization: a brief history of the endovascular treatment of carotid-cavernous sinus fistula. *J Neurointerv Surg* 2009;1(2):108-11.
- Thanapura C. Treatment of traumatic carotid-cavernous fistula at the Udon Thani Center Hospital. *J Clin Neurosci* 2004;11(5):498-500.
- Halbach VV, Higashida RT, Hieshima GB, Hardin CW, Yang PJ. Transvenous embolization of direct carotid-cavernous fistulas. *AJNR Am J Neuroradiol* 1988;9(4):741-7.
- Halbach VV, Higashida RT, Barnwell SL, Dowd CF, Hieshima GB. Transarterial platinum coil embolization of carotid-cavernous fistulas. *AJNR Am J Neuroradiol* 1991;12(3):429-33.

11. Debrun GM, Ausman JI, Charbel FT, Aletich VA. Access to the cavernous sinus through the vertebral artery: technical case report. *Neurosurgery* 1995;37(1):144-7.
12. Luo CB, Chang FC, Teng MM, Lirng JF, Chen SS. Endovascular embolization of carotid-cavernous fistula using the posterior communicating artery approach: a case report. *Kaohsiung J Med Sci* 2001;17(2):112-5.
13. Wilms G, Demaerel P, Lagae L, Casteels I, Mombaerts I. Direct carotid-cavernous fistula and traumatic dissection of the ipsilateral internal carotid artery: endovascular treatment. *Neuroradiology* 2000;42(1):62-5.
14. Mawad ME, Cekirge S, Ciceri E, Saatci I. Endovascular treatment of giant and large intracranial aneurysms by using a combination of stent placement and liquid polymer injection. *J Neurosurg* 2002;96(3):474-82.
15. Kocer N, Kizilkilic O, Albayram S, Adaletli I, Kantarci F, Islak C. Treatment of iatrogenic internal carotid artery laceration and carotid-cavernous fistula with endovascular stent-graft placement. *AJNR Am J Neuroradiol* 2002;23(3):442-6.
16. Weber W, Henkes H, Berg-Dammer E, Esser J, Kühne D. Cure of a direct carotid-cavernous fistula by endovascular stent deployment. *Cerebrovasc Dis* 2001;12(3):272-5.
17. Islak C, Kocer N, Albayram S, Kizilkilic O, Uzma O, Cokyukse O. Bare stent-graft technique: a new method of endoluminal vascular reconstruction for the treatment of giant aneurysms and fusiform. *AJNR Am J Neuroradiol* 2002;23(9):1589-95.