

# A Rare Case of Pulmonary Hypertension: Pulmonary Capillary Hemangiomatosis

## Nadir Bir Pulmoner Hipertansiyon Olgusu: Pulmoner Kapiller Hemanjiyomatozis

Neşe DURSUNOĞLU,<sup>a</sup>  
Dursun DURSUNOĞLU,<sup>b</sup>  
Figen TÜRK,<sup>c</sup>  
Duygu HEREK,<sup>d</sup>  
Ferda BİR,<sup>e</sup>  
Gökhan YÜNCÜ<sup>c</sup>

Departments of

<sup>a</sup>Pulmonology,

<sup>b</sup>Cardiology,

<sup>c</sup>Thoracic Surgery,

<sup>d</sup>Radiology,

<sup>e</sup>Pathology,

Pamukkale University

Faculty of Medicine, Denizli

Geliş Tarihi/Received: 01.07.2011

Kabul Tarihi/Accepted: 25.10.2011

*This case report was presented as a poster  
in 11<sup>th</sup> Congress of Turkish Thoracic Society  
23-27 April 2008, Antalya, Turkey.*

Yazışma Adresi/Correspondence:

Neşe DURSUNOĞLU

Pamukkale University

Faculty of Medicine,

Department of Pulmonology, Denizli,

TÜRKİYE/TURKEY

ndursunoglu@yahoo.com

**ABSTRACT** Pulmonary capillary hemangiomatosis (PCH) is a rare cause of pulmonary arterial hypertension and a benign vascular neoplasm characterized by thin-walled microvessels infiltrating the peribronchial and perivascular interstitium, the lung parenchyma, and the pleura. At computerised tomography of lung, main pulmonary arterial enlargement and widespread ill-defined centrilobular nodules of ground-glass opacity are consistently described, often mixed with lobular ground-glass opacities. Pathological diagnosis requires surgical biopsy, but the compromised condition of the patients makes this hazardous. Majority of the reported cases have been discovered postmortem due to lack of awareness and difficulty in making that diagnosis. Hereby, a young woman who died with hematologic complications due to PCH was reported.

**Key Words:** Hypertension, pulmonary; hematology

**ÖZET** Pulmoner kapiller hemanjiomatozis (PCH), pulmoner arterial hipertansiyonun nadir nedenlerinden biri olup, ince duvarlı mikrodamarların, plevra, akciğer parenkimi, perivasküler ve peribronşiyel interstisyumu infiltre etmesi ile karakterize benign vasküler bir neoplazmdır. Akciğerin bilgisayarlı tomografisinde, ana pulmoner arterlerde genişleme, buzlu cam dansitesinde yaygın silik sentrilobüler nodüllere sıklıkla lobüler buzlu cam opasiteleri de eşlik eder. Patolojik tanı cerrahi biyopsiyi gerektirir ancak hastaların zor tabloları bunu riskli hale getirebilir. Vakaların çoğu bilgi eksikliği ve tanının konmasındaki güçlükler nedeniyle postmortem olarak tanınır. Burada PCH'ye bağlı hematolojik komplikasyonlar ile ölen bir genç kadın hasta sunulmuştur.

**Anahtar Kelimeler:** Hipertansiyon, pulmoner; hematoloji

**Türkiye Klinikleri J Cardiovasc Sci 2013;25(1):53-5**

**P**ulmonary capillary hemangiomatosis (PCH), a benign vascular neoplasm, was first defined by Wagenvoort et al. as caused by an uncontrollable proliferation of pulmonary capillaries infiltrating in 1978, about 40 cases of PCH have been described in the literature.<sup>1</sup> Although clinical signs and symptoms may suggest PCH, rarely is the disease diagnosed antemortem. Pathological diagnosis requires surgical biopsy, but the compromised condition of the patient makes this hazardous. The most distinctive histologic feature of PCH is proliferation of capillary channels within alveolar walls.<sup>1</sup> At computerised tomography, main pulmonary arterial enlargement and widespread ill-defined centrilobular nodules of ground-glass opacity are consistently described, often mixed with lobular

ground-glass opacities. Median survival is 3 years from initial presentation and lung or heart-lung transplantation is the only curative therapeutic option.<sup>2</sup>

Hereby, a young woman who died with hematologic complications due to PCH was reported.

## CASE REPORT

A 33-year-old woman was admitted with progressive exertional dyspnea since last 4 years and exertional chest pain and presyncope which had been added six months before. Her past medical history showed us exertional dyspnea during her pregnancy periods 10 and 13 years ago. She did not smoke cigarette or drink alcohol and had no family history of cancer. She had been diagnosed as primary pulmonary hypertension (PPH) 2 years ago and being treated with unsuccessful therapies such as endothelin receptor antagonists, intravenous prostacyclin. Physical examination revealed normal breath sounds in all lung fields, hard S2 in cardiac examination. She had severe dyspnea which was categorised as NYHA III. Pulmonary function tests were normal except a noteworthy lower lung diffusion capacity (DLCO: 5.52, %66). Her six minute walking distance was 258 meters. Transthoracic echocardiography revealed pulmonary arterial diameter 28 mm, right ventricular dilatation, mean pulmonary arterial pressure 44 mmHg and deviation of interventricular septum to the left. Her high resolution chest computerised tomography (HRCT) (Figure 1) showed ground glass opacity in both lower lung fields. Fiberoptic bronchoscopy showed no endobronchial pathology and transbronchial biopsies revealed interstitial capillary proliferation. Transbronchial brushings were clear for microbiologic and cytologic examinations. As we suspect PCH with these results, we decided to prove our prediagnosis with lung biopsy, so lingular segment wedge resection was performed via video associated thoracoscopic surgery (VATS) and histopathologically high number of thin walled microvessels which immunohistochemically CD31 (+) and HMB45 (-), infiltrating lung parenchyma were seen. Based on the above histological and im-

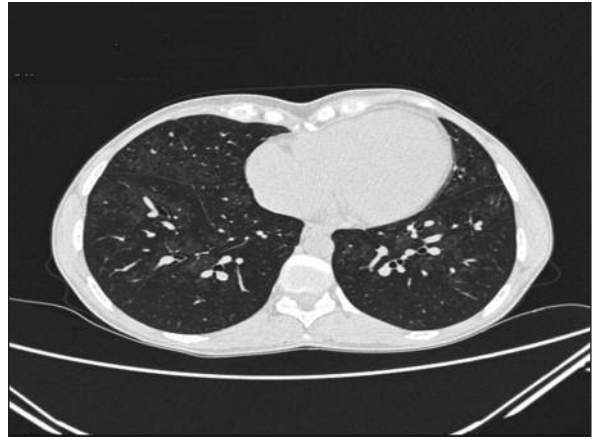


FIGURE 1: Ground glass opacities in both lower lung fields.

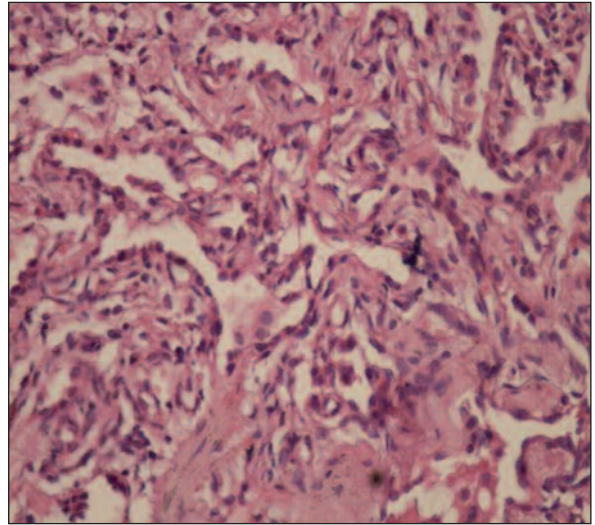


FIGURE 2: Thin-walled microvessels infiltrating the peribronchial and perivascular interstitium.

(See color figure at <http://cardiovascular.turkiyeklinikleri.com/>)

munohistological findings a diagnosis of hemangiomas was established (Figure 2). PCH was decided as the exact diagnosis and lung transplantation was planned to the patient. But unfortunately hematuria, hemothorax developed in postoperative 2<sup>nd</sup> day and she died 5 days after operation with hematologic complications which could not be explained via her blood sample analyses and unfortunately her family did not accept autopsy.

## DISCUSSION

Pulmonary capillary hemangiomatosis (PCH) is a rare cause of pulmonary arterial hypertension (PAH) characterized by thin-walled microvessels

infiltrating the peribronchial and perivascular interstitium, the lung parenchyma, and the pleura. These proliferating microvessels are prone to bleeding, resulting in accumulation of hemosiderin-laden macrophages in the alveolar spaces.<sup>3</sup>

Unfortunately, majority of the reported PCH cases have been discovered postmortem due to lack of awareness and difficulty in making that diagnosis. However, exact diagnosis has been put antemortem via lung biopsy in our case but unhappily we lost her 5 days after operation. Although, these cases have typical radiological patterns including parenchymal ground glass opacities and ill-defined centrilobular nodules, pericardial effusion, pleural effusion, lymphadenopathy, together with enlargement of main pulmonary arteries and right heart chambers.<sup>4</sup> most of the cases lost time until exact diagnosis and had been treated as primary pulmonary arterial hypertension (PAH). There is no any specific criteria for diagnosis of that disease, the most important clue is have suspect with all these clinical and radiological findings, the exact diagnosis is with histology.<sup>5</sup> Also our case had been diagnosed as primary PAH and had unsuccessful therapies such as endothelin receptor antagonists, intravenous prostacyclin and she lost time for real

treatment which is lung or heart-lung transplantation. Also we decided to perform lung transplantation to our patient but we lost her with postoperative hematologic complications.

In a recent study, it was shown that the expression of platelet-derived growth factors (*PDGFB* and *PDGFR- beta*) genes characterizes the nodular proliferations of PCH with increased numbers of mast cells, pericytes, and type II pneumocytes accompanying this endothelial proliferation so the up-regulation of these important angiogenic and antiapoptotic genes might suggest a mechanism and potential therapeutic approaches for PCH in the future.<sup>6</sup>

At first sight, PCH could be clinically indistinguishable from a primary PAH disorder such as PPH which do not produce thickening of the interlobular septa, that is caused by elevated pressures in the capillary or postcapillary circulation. In the differential diagnosis of PAH, HRCT of the lung parenchyma is very useful to evaluate any interstitial lung disease, PVOD or PCH. So we recommend that patients with presumed PPH should undergo a HRCT examination before initiation of vasodilator therapy that might induce florid and even fatal pulmonary edema in PCH patients.

## REFERENCES

1. Wagenvoort CA, Beetstra A, Spijker J. Capillary haemangiomas of the lungs. *Histopathology* 1978;2(6):401-6.
2. Montani D, Dorfmüller P, Maitre S, Jaïs X, Sitbon O, Simonneau G, et al. [Pulmonary veno-occlusive disease and pulmonary capillary hemangiomas]. *Presse Med* 2010;39(1):134-43.
3. Lantuéjoul S, Sheppard MN, Corrin B, Burke MM, Nicholson AG. Pulmonary veno-occlusive disease and pulmonary capillary hemangiomas: a clinicopathologic study of 35 cases. *Am J Surg Pathol* 2006;30(7):850-7.
4. Frazier AA, Franks TJ, Mohammed TL, Ozbudak IH, Galvin JR. From the Archives of the AFIP: pulmonary veno-occlusive disease and pulmonary capillary hemangiomas. *Radiographics* 2007;27(3):867-82.
5. Ito K, Ichiki T, Ohi K, Egashira K, Ohta M, Taguchi K, et al. Pulmonary capillary hemangiomas with severe pulmonary hypertension. *Circ J* 2003;67(9):793-5.
6. Assaad AM, Kawut SM, Arcasoy SM, Rosenzweig EB, Wilt JS, Sonett JR, et al. Platelet-derived growth factor is increased in pulmonary capillary hemangiomas. *Chest* 2007;131(3):850-5.