

## CASE REPORT

DOI: 10.5336/caserep.2022-90939

## Imaging of Intrathoracic Ectopic Kidney

Hasan DURSUN<sup>a</sup>, Özgür EKER<sup>b</sup>, Fadime ERSOY DURSUN<sup>c</sup><sup>a</sup>Department of Pediatric Nephrology, University of Health Science Prof. Dr. Cemil Taşcıoğlu City Hospital, İstanbul, Türkiye<sup>b</sup>Department of Nuclear Medicine, University of Health Science Prof. Dr. Cemil Taşcıoğlu City Hospital, İstanbul, Türkiye<sup>c</sup>Clinic of Hematology, Göztepe Prof. Dr. Süleyman Yalçın City Hospital, İstanbul, Türkiye

**ABSTRACT** The intrathoracic kidney is one of the rare causes of the congenital ectopic kidney. The present study discusses a case referred to our clinic with a pre-diagnosis of renal agenesis and a diagnosis of the intrathoracic ectopic kidney. The case is a 9-year-old patient who applied to our clinic complaining of abdominal pain. The left kidney could not be shown in the abdominal ultrasonography for the patient's abdominal pain. In the Tc-99m dimercaptosuccinic acid (DMSA) scintigraphy performed on this, the left kidney was detected far above its normal localization. On the thorax plus upper abdominal, the patient's computed tomography showed that the left kidney was intrathoracically located and the diaphragmatic hernia. The left kidney may not be visualized on ultrasonography in the patient. Therefore, the ectopic kidneys should be visualized by Tc-99m DMSA scintigraphy. In selected cases, computed tomography should be used to determine the proper localization of the intrathoracic kidney and whether there is a diaphragmatic hernia.

**Keywords:** Intrathoracic ectopic kidney; ultrasonography; scintigraphy; computed tomography

The ectopic kidney is one of the common congenital anomalies of the urinary system and kidney, and the intrathoracic kidney is one of the rare causes of this anomaly.<sup>1-5</sup> Four basic types of the intrathoracic ectopic kidney have been defined: a closed diaphragm, diaphragm evening, traumatic diaphragmatic rupture, and congenital diaphragmatic hernia.<sup>2,4,6</sup> A case referred to our clinic with a pre-diagnosis of renal agenesis and diagnosed as the intrathoracic ectopic kidney is discussed in the following. Before the study, the patient's parents were informed and an informed consent form was signed.

### CASE REPORT

A 9-year-old boy applied to the hospital with a complaint of abdominal pain. After abdominal ultrasonography, it was found that his left kidney was absent. The patient was admitted to our hospital's pediatric nephrology outpatient clinic with a pre-diagnosis of left renal agenesis. There were no features in

the patient's medical and family history. Physical examination revealed a body temperature of 37.1°C, a pulse of 84/min, a respiratory rate of 18/min, and blood pressure of 110/72 mmHg. No pathological sound was heard during respiratory system auscultation. Other systems examination was normal. The urine analysis showed a pH of 6, density of 1008, protein (-), blood (-), and normal microscopic examination. Urine culture remained negative, and complete blood count and renal function tests were normal. No kidney tissue was detected on the left side in ultrasonography.

The left kidney was not visible by abdominal ultrasonography. The left diaphragm event was detected on posterior-anterior and lateral chest radiographs (Figure 1A, 1B). Tc-99m dimercaptosuccinic acid (DMSA) scintigraphy could show the place of the kidney in the body. Therefore, we performed DMSA scintigraphy on the patient and showed that the left kidney was higher than its normal location (Figure 1C, 1D). However, it did not show

**Correspondence:** Hasan DURSUN

Department of Pediatric Nephrology, University of Health Science Prof. Dr. Cemil Taşcıoğlu City Hospital, İstanbul, Türkiye

**E-mail:** hasan.dursun@sbu.edu.tr



Peer review under responsibility of Türkiye Klinikleri Journal of Case Reports.

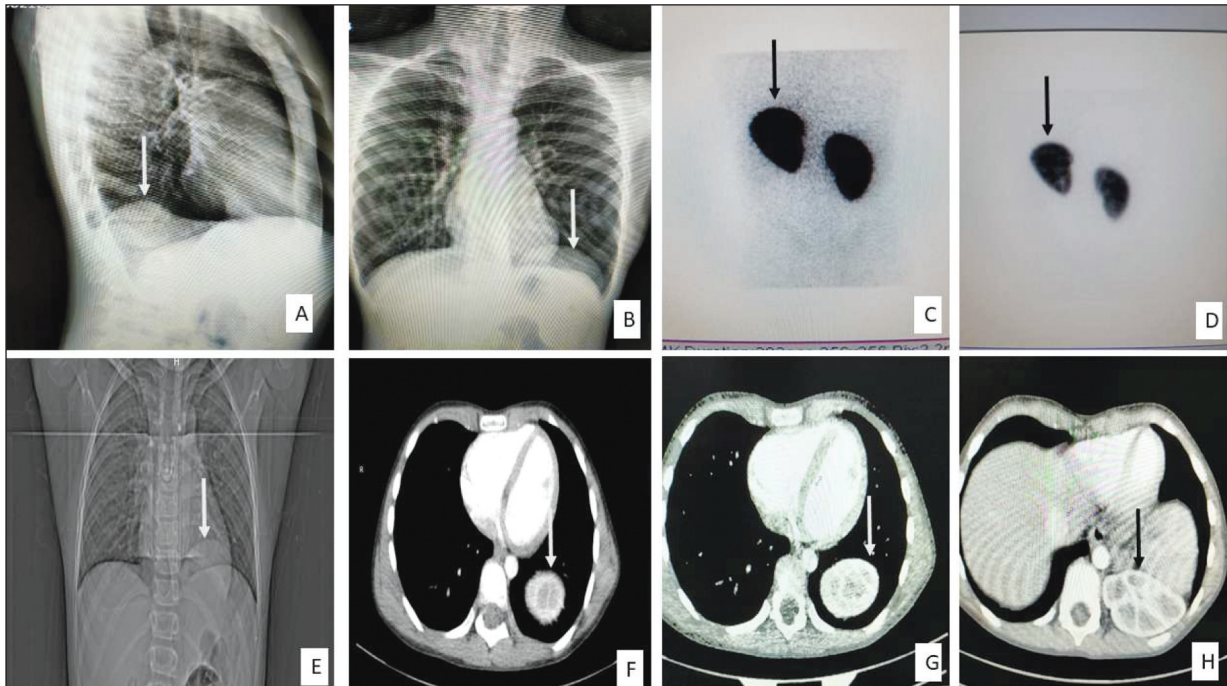
**Received:** 27 Apr 2022

**Received in revised form:** 23 Dec 2022

**Accepted:** 29 Dec 2022

**Available online:** 05 Jan 2023

2147-9291 / Copyright © 2023 by Türkiye Klinikleri. This is an open access article under the CC BY-NC-ND license (<http://creativecommons.org/licenses/by-nc-nd/4.0/>).



**FIGURE 1:** The diaphragm is elevated on the lateral chest X-ray (A) and the posterior-anterior chest X-ray (B), posterior view of the left kidney, which appears to be compressed from above, on dimercaptosuccinic acid scintigraphy (C, D), computed tomography of the thorax shows the localization of the left kidney in the thorax at different levels (E, F, G, H).

the kidney's exact localization and the diaphragm's state. The patient's thorax plus upper abdominal computed tomography (CT) showed that the left kidney was intrathoracically located and the diaphragmatic hernia (Figure 1E, 1F, 1G, and 1H). The patient was discussed in the pediatric urology and pediatric nephrology council, deciding that the operation was not required. In our case, although there was a left diaphragmatic hernia and a defect in the diaphragm accompanying the intrathoracic kidney, it was observed that other intra-abdominal organs, such as colon loops, did not pass into the thoracic area. Also, the patient did not have respiratory problems. It was recommended that the patient be followed up in our clinic regularly. Ethical approval was not taken for this case report. The research was conducted ethically in accordance with the World Medical Association Declaration of Helsinki.

## DISCUSSION

The intrathoracic kidney is a rare type of renal ectopia located at the highest level in body localization. It may be associated with diaphragmatic hernias that

occur as a result of trauma or congenitally as a result of the developmental disorder of the pleuroperitoneal membrane.<sup>7</sup> In our patient, the left kidney could not be visualized on ultrasonography. Therefore, the ectopic kidney was visualized by Tc-99m DMSA scintigraphy. Computed tomography or magnetic resonance imaging should be used to determine the exact localization of the kidney and whether the diaphragmatic hernia or defect.

In the presence of congenital diaphragmatic hernia accompanying renal ectopia, herniations of intraperitoneal organs such as the intestines are also common.<sup>7,8</sup> In our case, although there was a left diaphragmatic hernia and a defect in the diaphragm accompanying the intrathoracic kidney, it was observed that other intra-abdominal organs, such as colon loops, did not pass into the thoracic area. In the presence of congenital diaphragmatic hernia accompanying renal ectopia, herniations of intraperitoneal organs such as the intestines are also common.<sup>5,6</sup> The ureter shows continuity by entering through the foramen of the diaphragmatic hernia, which is longer than the normal kidney ureter.

Intrathoracic kidney anomaly is divided into 4 groups: renal ectopias (a) with a normal diaphragm, (b) with diaphragmatic eventration, (c) with congenital or acquired diaphragmatic hernia, such as Bochdalek hernia, and (d) with traumatic rupture of the diaphragm.<sup>9</sup> In many cases, the intrathoracic kidney can be easily lowered into the abdominal cavity without causing hemodynamic impairment because of its enough vascular length.<sup>1,5</sup> Surgical exploration is not required for asymptomatic intrathoracic kidneys, but it is unavoidable in Bochdalek hernia or post-traumatic diaphragmatic hernias.<sup>3</sup> The reduced kidney should be monitored by renal Doppler ultrasonography and renal cortical scintigraphy in subsequent follow-ups.<sup>3-5</sup>

The intrathoracic kidney is one of the rare causes of the congenital ectopic kidney. Ultrasonography is not always enough for diagnosis. Therefore, ectopic kidneys should be visualized by DMSA scintigraphy. However, in cases where the kidney cannot be determined precisely on DMSA scintigraphy (such as an intrathoracic or subdiaphragmatic kidney) or to determine whether the diaphragm is intact or not, thoracic CT may be required. For this reason, DMSA

scintigraphy and CT of the thorax may be required to detect the diaphragm's defect in the intrathoracic ectopic kidney.

### Source of Finance

*During this study, no financial or spiritual support was received neither from any pharmaceutical company that has a direct connection with the research subject, nor from a company that provides or produces medical instruments and materials which may negatively affect the evaluation process of this study.*

### Conflict of Interest

*No conflicts of interest between the authors and / or family members of the scientific and medical committee members or members of the potential conflicts of interest, counseling, expertise, working conditions, share holding and similar situations in any firm.*

### Authorship Contributions

**Idea/Concept:** Hasan Dursun, Özgür Eker; **Design:** Hasan Dursun, Fadime Ersoy Dursun; **Control/Supervision:** Hasan Dursun, Özgür Eker; **Data Collection and/or Processing:** Hasan Dursun, Özgür Eker, Fadime Ersoy Dursun; **Analysis and/or Interpretation:** Hasan Dursun; **Literature Review:** Fadime Ersoy Dursun; **Writing the Article:** Fadime Ersoy Dursun; **Critical Review:** Hasan Dursun; **References and Fundings:** Özgür Eker; **Materials:** Hasan Dursun, Özgür Eker.

## REFERENCES

- Kian B, Kayedi M, Teimouri A. Intrathoracic kidney: A rare presentation of ectopic kidney. *Radiol Case Rep.* 2022;17(8):2795-7. [[Crossref](#)] [[PubMed](#)] [[PMC](#)]
- Al Eraky M, Hassan L, Abou Zaid A, Arabi H. Congenital intrathoracic ectopic kidney in association with bochdalek hernia. *Cureus.* 2022;14(2):e22674. [[Crossref](#)] [[PubMed](#)] [[PMC](#)]
- Sarac M, Bakal U, Tartar T, Canpolat S, Kara A, Kazez A. Bochdalek hernia and intrathoracic ectopic kidney: Presentation of two case reports and review of the literature. *Niger J Clin Pract.* 2018;21(5):681-6. [[Crossref](#)] [[PubMed](#)]
- Langer FW, dos Santos D, Dartora EG, Alves GR, Haygert CJ. Ectopic intrathoracic kidney presenting as recurrent pneumonias in a 1-year-old infant: a case report. *Lung.* 2015;193(5):839-42. [[Crossref](#)] [[PubMed](#)]
- Dell'Atti L, Galosi AB. Right ectopic intrathoracic kidney: Unusual clinical presentation in a young patient affected by scrotal varicocele. *Arch Ital Urol Androl.* 2017;89(4):323-4. [[Crossref](#)] [[PubMed](#)]
- Arsilan H, Aydogan C, Orcen C, Gonlllu E. A rare case: congenital thoracic ectopic kidney with diaphragmatic eventration. *J Pak Med Assoc.* 2016;66(3):339-41. [[PubMed](#)]
- Kubricht WS 3rd, Henderson RJ, Bundrick WS, Venable DD, Eastham JA. Renal cell carcinoma in an intrathoracic kidney: radiographic findings and surgical considerations. *South Med J.* 1999;92(6):628-9. [[Crossref](#)] [[PubMed](#)]
- Pfister-Goedeke L, Brunier E. Die intrathorakale Niere im Kindesalter (mit besonderer Berücksichtigung der sekundären Nierenverlagerung bei Bochdalekscher Zwerchfellhernie) [Intrathoracic kidney in childhood with special reference to secondary renal transport in Bochdalek's hernia]. *Helv Paediatr Acta.* 1979;34(4):345-57. [[PubMed](#)]
- Jeong BD, Ahn SH, Song JW, Shim JY, Lee MY, Won HS, et al. Impaction of an intrathoracic kidney acted as a shield against herniation of the abdominal viscera in a case of right congenital diaphragmatic hernia. *Obstet Gynecol Sci.* 2016;59(1):58-61. [[Crossref](#)] [[PubMed](#)] [[PMC](#)]