

Penetrating Keratoplasty with Manually Assisted Pars Plana Infusion in Vitrectomized Eyes: Descriptive Study

Vitrektomize Gözlerde Pars Plana İnfüzyon Destekli Penetran Keratoplasti: Tanımlayıcı Araştırma

¹Burcu KASIM^a, ¹Yusuf KOÇLUK^a

^aClinic of Ophthalmology, Adana City Training and Research Hospital, Adana, Türkiye

ABSTRACT Objective: To present the cases with a history of vitrectomy, that underwent penetrating keratoplasty (PKP) combined with pars plana infusion in a closed. **Material and Methods:** The medical records and surgical videos of the patients, with a history of pars plana vitrectomy (PPV), who underwent PKP were reviewed retrospectively. Demographic data, including age at the time of the PKP, gender; indication for the PPV, the time between PPV and PKP, indication for PKP, best-corrected visual acuity (BCVA, LogMAR), lens status and additional ocular diseases preoperatively; intraoperative complications and BCVA, graft status and complications postoperatively were recorded. **Results:** PKP with manually assisted pars plana infusion was performed in 16 vitrectomized eyes of 16 (7 female and 9 males) patients in this study. Silicone oil extraction was performed in 7 (43.7%) patients (anteriorly in 4, posteriorly in 3). The mean BCVA was improved statistically significantly at the last follow-up visit (2.23 ± 0.3 vs 1.93 ± 0.7 , LogMAR, $p=0.040$). Optic atrophy was found in 11 (68.7%) patients. Choroidal detachment occurred in the early postoperative stage in 1 (6.2%) patient and managed with oral steroids. Graft rejection was seen in 6 (37.5%) patients. Four (25%) patients underwent repeated PKP and 2 (12.5%) patients were listed on the transplant list. At the last follow-up visit, 11 (68.7%) grafts were clear and 5 (31.2%) were edematous. **Conclusion:** PKP in vitrectomized eyes, pars plana infusion is a cheap and effective method that may prevent hypotony in these patients and the procedure may result in good visual outcomes where no additional retinal problems are accompanied.

ÖZET Amaç: Vitrektomi öyküsü olan olgularda, manuel pars plana infüzyon desteği ile kapalı ön kamarada (ÖK) penetran keratoplasti (PKP) uygulamasının sonuçlarının sunulması amaçlandı. **Gereç ve Yöntemler:** Pars plana vitrektomi (PPV) öyküsü olan ve PKP uygulanan olgulara ait hasta kartları ve cerrahi videolar retrospektif olarak incelendi. Hasta kartlarından demografik bilgiler, PPV endikasyonu, PPV ve PKP arası geçen süre, PKP endikasyonu, en iyi düzeltilmiş görme keskinliği (EİDGK, LogMAR); ameliyat öncesi lens durumu ve ek oküler hastalıklar; ameliyat sonrası EİDGK, greft durumu ve komplikasyonlar ve cerrahi videolardan ise intraoperatif komplikasyonlar kaydedildi. **Bulgular:** On altı hastanın 16 vitrektomize gözüne (7 kadın, 9 erkek) pars plana infüzyon desteği ile PKP uygulandı. Cerrahi sırasında 7 (%43,7) olguda silikon ekstraksiyonu (4 olguda ön, 7 olguda arka yaklaşım) uygulandı. Ameliyat sonrası ortalama EİDGK'nin istatistiksel olarak anlamlı olarak iyileşti (ameliyat öncesi: $2,23\pm 0,3$ ve ameliyat sonrası: $1,93\pm 0,7$, LogMAR, $p=0,040$). On bir (%68,7) olguda optik atrofi tespit edildi. Bir (%6,2) olguda erken dönemde koroid dekolmanı gözlemlendi ve oral steroid tedavisi ile tedavi edildi. Altı (%37,5) olguda greft reddi gözlemlendi. Bunların 4'üne (%25) tekrar PKP uygulanırken, diğer 2 (%12,5) olgu nakil sırasına alındı. Son takip muayenesinde, 11 (%68,7) olguda greft saydam, 5 (%31,2) olguda greft ödemli olarak bulundu. **Sonuç:** Vitrektomize gözlerde pars plana infüzyon desteği ile PKP, ucuz ve etkin bir yöntem olarak görülmektedir. Bu yöntemle, hipotoni riski azaltılmakta ve ek retina patolojileri olmayan olgularda iyi görsel sonuçlara ulaşılmaktadır.

Keywords: Penetrating keratoplasty; vitrectomized eyes; covered cornea technique

Anahtar Kelimeler: Penetran keratoplasti; vitrektomize göz; örtülü kornea tekniği

Penetrating keratoplasty (PKP) may be more challenging in vitrectomized eyes with poorer outcomes.^{1,2} Hypotony poses the most significant challenge in these situations, leading to complications like choroidal effusion or hemorrhage during surgery. Flaring rings

prevent the globe from collapsing suddenly, but they are not always sufficient to stabilize the pressure. Being an open-sky procedure also has additional effects on hypotony. By using the covered cornea technique described by Arslan et al., along with the pars plana in-

Correspondence: Burcu KASIM

Clinic of Ophthalmology, Adana City Training and Research Hospital, Adana, Türkiye

E-mail: burcukasim@gmail.com



Peer review under responsibility of Türkiye Klinikleri Journal of Ophthalmology.

Received: 06 Sep 2022

Received in revised form: 04 Dec 2022

Accepted: 21 Dec 2022

Available online: 29 Dec 2022

2146-9008 / Copyright © 2023 by Türkiye Klinikleri. This is an open access article under the CC BY-NC-ND license (<http://creativecommons.org/licenses/by-nc-nd/4.0/>).

fusion, hypotony may be prevented during the removal of silicone oil and pathologic cornea.³

In this study, cases with a history of vitrectomy will be presented who underwent PKP in combination with pars plana infusion in a closed anterior chamber (AC).

MATERIAL AND METHODS

SUBJECTS

The medical records and surgical videos of the patients, with a history of pars plana vitrectomy (PPV), who underwent PKP at the ophthalmology clinic of a training and research hospital between June 2014 and August 2020 were reviewed in this retrospective study. The study was approved Adana City Training and Research Hospital Clinical Research Ethics Committee (date: January 27, 2021, no: 1273) and adhered to the tenets of the Declaration of Helsinki. Written and verbal informed consent has been obtained from all patients.

Demographic data, including age at the time of the PKP, gender; indication for the PPV, the time between PPV and PKP, indication for PKP, best-corrected visual acuity (BCVA, LogMAR), lens status and additional ocular diseases preoperatively; intraoperative complications and BCVA, graft status and complications postoperatively were recorded. The patients with a follow-up of less than 6 months were excluded from the study.

SURGICAL PROCEDURE

All procedures were performed under general or retrobulbar anesthesia by 2 experienced surgeons (YK, BK). A 23G trocar was inserted 3.5 mm from the limbus into the vitreous cavity and an infusion cannula was connected manually, not connected to phacoemulsification or vitrectomy machine. Flaring ring was secured with 8.0 vicryl in the first 3 cases along with the infusion. After measuring the size of the corneal pathology or the previous graft with a caliper, the donor graft was prepared in a diameter 0.50 mm larger than the determined recipient size. The infusion was closed during the trephination. After entering the AC with a microvitorectinal (MVR) knife, cohesive viscoelastic was injected and

the infusion was opened approximately in half, manually by the surgical nurse, enough to stabilize the tonus of the globe (Figure 1A-C). If silicone oil extraction was necessary, removal was performed either anteriorly or posteriorly. After entering the AC, if silicone oil was present in the AC, the corneal incision was extended for about 5 mm and silicone oil extraction was performed anteriorly with the infusion fully opened. If no silicone oil was seen a suture was placed on the corneal incision. Then, an additional trocar was inserted and silicone oil was extracted posteriorly. After that, the recipient cornea was cut by corneal scissors, approximately 90 degrees, and sutured to the recipient, just in the middle of this part. This process was continued until 360 degrees of the cornea was cut and sutured with four 10.0 nylons (Figure 1D,E). Then, cohesive viscoelastic was put on the cornea and the graft was sutured between the existed sutures in 3 quadrants. After that, the sutures of the recipient cornea were cut and the pathologic cornea was removed under the graft. The donor graft was sutured with 16 interrupted sutures (Figure 1F-I). The infusion rate was changed manually by the surgical nurse also during the suturing stage. While passing the needle through the graft and the recipient, the infusion was opened fully to prevent hypotony and while securing the knot, the infusion flow rate was reduced to prevent high intraocular pressure and also keeping the globe stable. When the last knot was being secured, the infusion was stopped. The scleromies were closed with 8.0 vicryl. In the cases of an additional procedure, such as transscleral intraocular lens (IOL) fixation, pupilloplasty, or IOL repositioning, the infusion was opened fully. Subconjunctival gentamicin and dexamethasone were injected and a therapeutic contact lens was placed at the end of the surgery.

POSTOPERATIVE MANAGEMENT

The patients were administered topical dexamethasone and moxifloxacin every 2 hours for 1 week and then topical dexamethasone was tapered in 12 months. Topical and/or oral antiglaucomatous agents were used, where necessary. Preservative free artificial tears were used, hourly. All the patients were followed on the first day, first week, and first month postoperatively and monthly afterward.

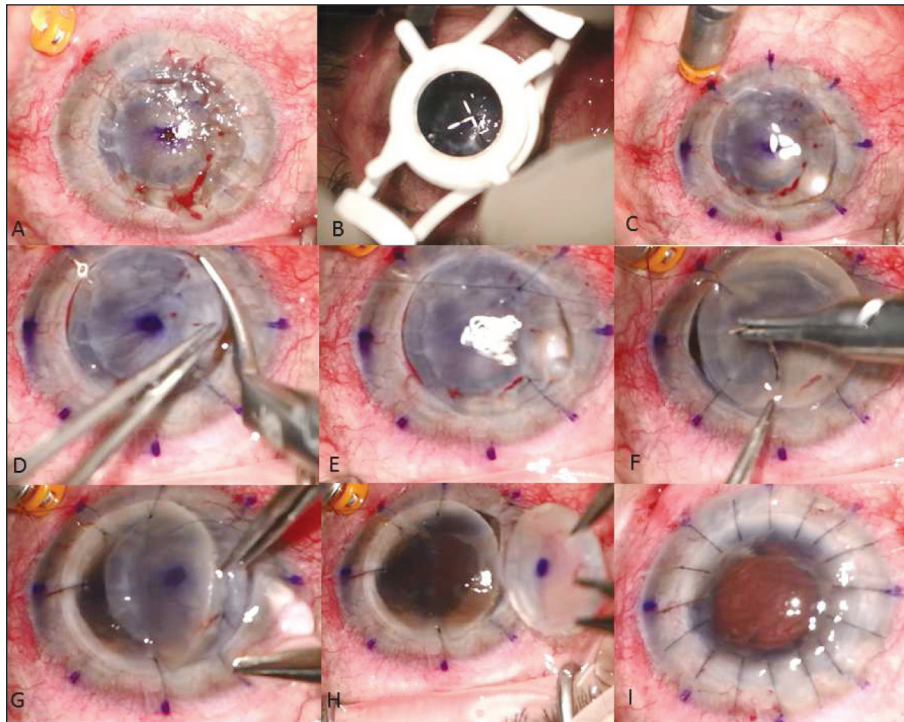


FIGURE 1: A) 23G trocar was inserted 3.0 mm from the limbus, inferotemporally, B) Trephination was made with a 7.0 mm trephine, C) After entering AC with an MVR blade, the incision was extended about 90 degrees and the infusion cannula was opened fully, D) 10.0 nylon suture was put in the middle of the incision and the incision was extended with corneal scissors about 90 degrees, E) 10.0 nylon suture was put in the middle of the incision, F) After securing the recipient with 4 sutures, 90 degrees apart, 7.50 mm donor graft was started to be sutured over the recipient, G-H) After suturing the inferior, superior, and temporal quadrant of the donor, the recipient cornea was removed under the donor, I) Donor cornea was sutured with 16 interrupted 10.0 nylon and the trocar was removed.

AC: Anterior chamber; MVR: Microvitrectorial.

STATISTICAL ANALYSIS

Data analysis was performed using SPSS for Windows software (SPSS version 16.0, SPSS Inc. Chicago, USA). The normality distribution of variables was tested by Kolmogorov-Smirnov test. The descriptive statistics of normally distributed continuous variables were expressed as mean±standard deviation (range), and descriptive statistics of abnormally distributed variables were expressed as median (minimum-maximum). Categorical variables were presented as frequency (%). Paired sample t-test was used to compare the BCVA before and after surgery. Statistical significance was determined as $p < 0.05$.

RESULTS

Sixteen eyes of 16 (7 female and 9 males) patients were enrolled in this study. The median age was 60 (9-82) years, with a median follow-up time of 19 (6-

65) months. The mean diameter of the recipient size was 7.16 ± 0.37 (6.00-7.50) and the graft size was 7.67 ± 0.37 (6.50-8.00). The indication for PPV was retinal detachment in 9 (56.2%) patients (4 cases due to trauma, 5 cases for an unknown etiology), vitreous hemorrhage due to proliferative diabetic retinopathy in 3 (18.8%) patients, endophthalmitis in 1 (6.2%) patient, dropped nucleus into the vitreous cavity in 1 (6.2%) patient and for an unknown etiology in 2 (12.5%) patients. The indication for PPV and PKP was summarized in Table 1. PPV was performed with a median of 48 (7-216) months before PKP. Seven patients were aphakic and 9 (56.2%) were pseudophakic (1 AC IOL, 8 posterior chamber IOL). Before surgery, 7 (43.7%) patients had glaucoma. Six (37.5%) of them were managed medically and 1 (6.2%) had an Ahmed glaucoma valve implantation. Silicone oil extraction was performed in 7 (43.7%) patients (anteriorly in 4, posteriorly in 3).

Pupilloplasty was performed in 1 (6.2%) patient, transscleral IOL fixation in 1 (6.2%) patient, and IOL repositioning in 1 (6.2%) patient. No perioperative complication occurred in any of the patients.

The preoperative and postoperative photographs of 2 patients were shown in Figure 2.

The mean BCVA was improved statistically significantly at the last follow-up visit (2.23 ± 0.3 vs 1.93 ± 0.7 , LogMAR, $p=0.040$) (Table 1). However, optic atrophy was found in 11 (68.7%) patients. Repeated PPV and silicone oil implantation were performed in 2 (12.5%) patients due to the recurrence of retinal detachment. Choroidal detachment occurred

TABLE 1: The preoperative, intraoperative, and postoperative findings of the patients.

Case No.	Indication for PPV	Preoperative BCVA (LogMAR)	Indication for PKP	SO extraction	RePPV+ SO	RePKP	Last visit BCVA (LogMAR)	Postoperative complication	Follow-up (months)
1	RD	2.30	Corneal perforation due to trauma	+	+	+	2.30	Choroidal effusion + graft rejection	24
2	RD	2.30	PBK	+	-	-	2.30	Graft rejection	65
3	Unknown	2.00	ABK	-	-	-	0.20	-	69
4	Unknown	2.30	Corneal opacity	-	-	+	2.30	Choroidal effusion + graft rejection	38
5	RD	2.70	Graft failure	+	-	-	2.70	-	6
6	PDRP	2.30	Graft failure	-	-	-	2.30	-	6
7	Endophthalmitis	1.80	Corneal opacity	-	-	-	0.40	-	14
8	RD	2.30	Graft failure	-	-	-	1.30	-	19
9	PDRP	2.30	Corneal opacity	-	-	-	2.30	Graft rejection	30
10	PDRP	2.30	Silicone keratopathy	+	-	+	2.30	Graft rejection	42
11	RD	1.80	Corneal perforation due to HSV	-	-	-	1.30	-	6
12	RD	3.00	Silicone keratopathy	+	-	-	3.00	-	6
13	RD	2.30	Graft failure	-	-	-	2.30	-	25
14	RD	1.80	Graft failure	+	-	-	1.80	-	6
15	RD	2.30	Silicone keratopathy	-	-	+	2.30	Graft rejection	48
16	Drop nucleus	2.30	Silicone keratopathy	+	+	-	1.80	-	6

PPV: Pars plana vitrectomy; BCVA: Best-corrected visual acuity; PKP: Penetrating keratoplasty; SO: Silicone oil; RD: Retinal detachment; PBK: Pseudophakic bullous keratopathy; ABK: Aphakic bullous keratopathy; HSV: Herpes simplex virus.

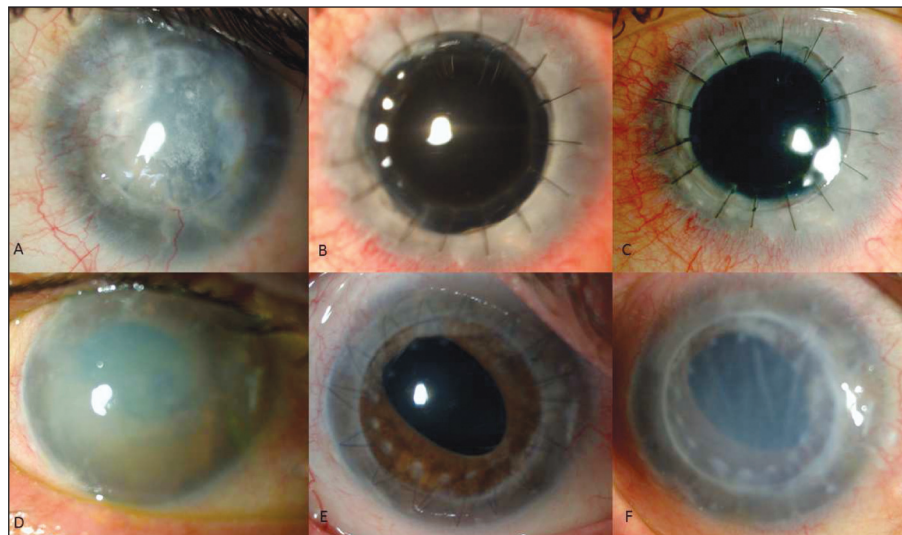


FIGURE 2: A) The preoperative photo of a case with graft failure, B) Clear graft at 4 months after rePKP, C) Clear graft at 21 months postoperatively, D) The preoperative photo of a case with bullous keratopathy, E) Clear graft at 13 months after PKP and silicone oil extraction, F) Graft failure at 42 months postoperatively. PKP: Penetrating keratoplasty.

in the early postoperative stage in 1 (6.2%) patient and managed with oral steroids. Meanwhile, in another patient choroidal detachment occurred 12 months after surgery, presumed to be due to preexisting uveitis. Graft rejection was seen in 6 (37.5%) patients (Table 1). All of the rejection episodes occurred more than 12 months after the initial surgery. Four (25%) patients underwent repeated PKP and 2 (12.5%) patients were listed on the transplant list. At the last follow-up visit, 11 (68.7%) grafts were clear and 5 (31.2%) were edematous. No significant differences in terms of preoperative glaucoma, the duration between PPV and PKP, silicone extraction, recipient and donor size were found between the patients with clear grafts when compared to graft rejection at the end of the follow-up time ($p=0.364, 0.827, 0.844, 0.320, 0.583$; respectively).

DISCUSSION

PKP may be indicated in vitrectomized eyes due to several corneal pathologies, such as silicone oil keratopathy, full-thickness opacities due to the previous corneal perforation, or graft failure due to silicone oil or increased endothelial cell loss after vitrectomy.^{1,4,5} The most common indications for PKP in this study were graft failure (31.2%) and silicone oil keratopathy (25%). Although silicone oil injection is commonly used by retinal surgeons as a tamponading agent in PPV, it has several complications such as silicone oil keratopathy, especially where silicone oil was kept for long times. Previous studies have shown 6-9.4% rates of silicone oil keratopathy after 12 months.^{6,7}

It has been shown lower success rates of PKP in silicone oil keratopathy than other keratopathies.^{1,2,8} The graft survival rate after PKP for silicone oil keratopathy was shown to be between 41.7 to 63.7%. However, the functional success rate may vary from 0 to 58%.⁸ In this study, the clear graft rate was 68.7%. In a previous study by Lee et al. silicone oil was shown to be the most significant risk factor for graft failure.¹ However no significant risk factor was shown in our study. The functional success (BCVA>0.1 Snellen, 1.0 LogMAR) rate was 12.5% (2/14 patients). In these patients, the duration be-

tween PKP and PPV was less than 12 months. In the other 14/16 patients had guarded visual prognosis, mostly due to optic atrophy and/or macular problems caused by diabetes. Thus, this lower rate of visual success may be a result of the primary pathology that indicated PPV or prolonged time of silicone oil retention and increased IOP that results in optic atrophy.

Also, open-sky PKP in vitrectomized eyes can be a challenging procedure, as they are more prone to hypotony and the sudden collapse of the globe, which may lead to devastating complications, such as choroidal detachment or hemorrhage.⁹ To avoid the collapse of the globe flaring ring is commonly used, but it does not prevent hypotony. The covered cornea technique combined with a pars plana infusion with staged flow rates, adjusted manually, is a cheap, effective, and easy technique that prevents hypotony, while no intraoperative complication was seen. In this study choroidal effusion occurred in only 1 patient, in the early postoperative period, which was treated medically with oral steroids. It may be combined with flaring rings, but the ring may make it difficult to insert the trocar and manipulate the infusion cannula. Thus, we left the use of flaring rings since infusion prevents hypotony and the collapse of the globe. Besides, since it is possible to adjust it manually, no additional expensive equipment is required.

The limitations of this study are the limited number of patients and its retrospective nature. The absence of a control group to compare our technique was another limitation.

CONCLUSION

In conclusion, PKP in a closed AC with pars plana infusion is a cheap and effective method that may prevent hypotony in vitrectomized patients and the procedure may result in good visual outcomes where no additional retinal problems are accompanied.

Source of Finance

During this study, no financial or spiritual support was received neither from any pharmaceutical company that has a direct connection with the research subject, nor from a company that provides or produces medical instruments and materials which may negatively affect the evaluation process of this study.

Conflict of Interest

No conflicts of interest between the authors and / or family members of the scientific and medical committee members or members of the potential conflicts of interest, counseling, expertise, working conditions, share holding and similar situations in any firm.

Authorship Contributions

Idea/Concept: Burcu Kasım; **Design:** Burcu Kasım, Yusuf Koçluk; **Control/Supervision:** Yusuf Koçluk; **Data Collection and/or Processing:** Burcu Kasım, Yusuf Koçluk; **Analysis and/or Interpretation:** Burcu Kasım; **Literature Review:** Burcu Kasım; **Writing the Article:** Burcu Kasım; **Critical Review:** Yusuf Koçluk; **References and Fundings:** Burcu Kasım; **Materials:** Burcu Kasım, Yusuf Koçluk.

REFERENCES

1. Lee GA, Shah P, Cooling RJ, Dart JK, Bunce C. Penetrating keratoplasty for silicone oil keratopathy. Clin Exp Ophthalmol. 2001;29(5):303-6. [\[Crossref\]](#) [\[PubMed\]](#)
2. Noorily SW, Foulks GN, McCuen BW. Results of penetrating keratoplasty associated with silicone oil retinal tamponade. Ophthalmology. 1991;98(8):1186-9. [\[Crossref\]](#) [\[PubMed\]](#)
3. Arslan OS, Unal M, Arici C, Cicik E, Mangan S, Atalay E. Novel method to avoid the open-sky condition in penetrating keratoplasty: covered cornea technique. Cornea. 2014;33(9):994-8. [\[Crossref\]](#) [\[PubMed\]](#)
4. Koushan K, Mikhail M, Beattie A, Ahuja N, Liszauer A, Kobetz L, et al. Corneal endothelial cell loss after pars plana vitrectomy and combined phacoemulsification-vitrectomy surgeries. Can J Ophthalmol. 2017;52(1):4-8. [\[Crossref\]](#) [\[PubMed\]](#)
5. Legler U, Seiberth V, Knorz MC, Jung E, Liesenhoff H. Endothelzellverlust nach Pars-plana-Vitrectomie und Silikonölimplantation [Loss of corneal endothelial cells following pars plana vitrectomy and silicone oil implantation]. Fortschr Ophthalmol. 1990;87(3):290-3. German. [\[PubMed\]](#)
6. Berker N, Batman C, Ozdamar Y, Eranil S, Aslan O, Zilelioglu O. Long-term outcomes of heavy silicone oil tamponade for complicated retinal detachment. Eur J Ophthalmol. 2007;17(5):797-803. [\[Crossref\]](#) [\[PubMed\]](#)
7. Abu-Yaghi NE, Abu Gharbieh YA, Al-Amer AM, AIRyalat SAS, Nawaiseh MB, Darweesh MJ, et al. Characteristics, fates and complications of long-term silicone oil tamponade after pars plana vitrectomy. BMC Ophthalmol. 2020;20(1):336. [\[Crossref\]](#) [\[PubMed\]](#) [\[PMC\]](#)
8. Karel I, Kalvodová B, Kuthan P. Results of penetrating keratoplasty in bullous silicone oil keratopathy. Graefes Arch Clin Exp Ophthalmol. 1998;236(4):255-8. [\[Crossref\]](#) [\[PubMed\]](#)
9. Chen W, Ren Y, Zheng Q, Li J, Waller SG. Securing the anterior chamber in penetrating keratoplasty: an innovative surgical technique. Cornea. 2013;32(9):1291-5. [\[Crossref\]](#) [\[PubMed\]](#)