

# Primary Hyperparathyroidism Caused by Ectopic Adenoma Resected by Video-Assisted Thoracic Surgery: Case Report

## Ektopik Adenoma Bağlı Primer Hiperparatiroidili Olgunun Video Yardımlı Torakoskopik Rezeksiyonu

Narin NASIROĞLU İMGA,<sup>a</sup>  
Özgür KARAKURT,<sup>b</sup>  
Berçem AYÇİÇEK DOĞAN,<sup>a</sup>  
Zeynep KARABULUT,<sup>c</sup>  
Yasemin TÛTÛNCÛ,<sup>a</sup>  
Dilek BERKER,<sup>a</sup>  
Bülent KOÇER<sup>b</sup>  
Serdar GÛLER<sup>a</sup>

Clinics of

<sup>a</sup>Endocrinology and Metabolism,

<sup>b</sup>Thoracic Surgery,

<sup>c</sup>Internal Medicine,

Ankara Numune Training and  
Research Hospital, Ankara

Geliş Tarihi/Received: 20.02.2015

Kabul Tarihi/Accepted: 27.04.2015

Yazışma Adresi/Correspondence:

Narin NASIROĞLU İMGA

Ankara Numune Training and

Research Hospital,

Clinic of Endocrinology and Metabolism,

Ankara,

TÛRKİYE/TURKEY

xnarinx@yahoo.com

**ABSTRACT** Primary hyperparathyroidism is characterized with excessive parathormone (PTH) secretion from parathyroid gland. Ectopic parathyroid adenomas are rare. Herein we present a case of primary hyperparathyroidism with severe long term elevated PTH levels due to ectopic parathyroid adenoma in mediastinal region and its successful surgical management with minimally invasive techniques. Parathyroid adenomectomy was performed via left video assisted thoracoscopic surgery (VATS). We concluded that VATS resection of an ectopic parathyroid gland in the anterior mediastinum is simple and effective. This approach is less invasive than sternotomy and thoracotomy, and it may be first choice method for resection of ectopic parathyroid glands in the anterior mediastinum.

**Key Words:** Hyperparathyroidism, primary; thoracic surgery, video-assisted; parathyroid neoplasms

**ÖZET** Primer hiperparatiroidizm, paratiroid bezinden aşırı parathormon (PTH) salgılanması ile karakterize bir hastalıktır. Ektopik paratiroid adenomları daha nadir görülürler. Biz burada mediastinal bölge yerleşimli ektopik paratiroid adenomundan kaynaklanan ve minimal invaziv teknikler kullanılarak başarılı bir cerrahi tedavi uygulanan aşırı yüksek PTH düzeyleri ile seyreden primer hiperparatiroidizm olgusunu sunmayı amaçladık. Sol mediasten yerleşimli ektopik paratiroid adenomu eksizyonu amacıyla yapılan paratiroid adenomektomi sol taraflı video torakoskopik cerrahi (VATS) yoluyla gerçekleştirildi. Ön mediastende lokalize ektopik paratiroid adenom rezeksiyonu için VATS yönteminin basit ve etkili olabileceği sonucuna varıldı. Bu yaklaşım anterior mediastende lokalize ektopik paratiroid adenomlarının rezeksiyonu için sternotomi ve torakotomiye oranla daha az invaziv olduğundan eğer mümkünse ilk yöntem olarak tercih edilebilir.

**Anahtar Kelimeler:** Hiperparatiroidi, primer; göğüs cerrahisi, video yardımcı; paratiroid neoplazileri

**Türkiye Klinikleri J Endocrin 2015;10(2):62-5**

Primary hyperparathyroidism is characterized with excessive parathormone (PTH) secretion from parathyroid gland. Laboratory findings are hypercalcemia, hypophosphatemia and excessive bone resorption.<sup>1</sup> Solitary parathyroid adenoma is seen in approximately 85% of primary hyperparathyroidism cases. Parathyroid hyperplasia and parathyroid carcinoma account for 15% and 1% of the cases respectively.<sup>2</sup> Ectopic parathyroid adenoma is detected in 4-16% of cases and 22% of them may be located in the anterosuperior mediastinal region.<sup>3,4</sup> Herein we present a case of primary hyperparathyroidism with severe long term elevated PTH levels due to ectopic parathyroid adenoma in mediastinal region and its suc-

successful surgical management with minimally invasive technique. Video-assisted thoracoscopic surgery (VATS) is a type of thoracic surgery performed by the small ports and videoscope for visualization. When compared with thoracotomy or sternotomy, VATS may result in less pain and shorten recovery time.<sup>3</sup>

## CASE REPORT

A 38-year-old female admitted to our clinic with long term complaints of severe back pain and gait disturbance. In laboratory tests, serum calcium (Ca): 11,64 mg/dL (8,5-10,5), alkaline phosphatase (ALP): 764 U/l (35-105), phosphorus (P): 1,51 mg/dL (2,5-4,5) and parathormone (PTH) levels were 1385 pg/mL (15-65). Twenty four hour urine calcium level was 1050 mg/day (100-321) and also urinary calcium excretion was 2.5%. The bone mineral density results were compatible for osteoporosis. Urinary ultrasonography (USG) showed cortical millimetric calcifications in interpolar part of left kidney. For location of parathyroid adenoma at first parathyroid USG was performed. Parathyroid USG did not show any adenoma or hyperplasia. Thyroid USG demonstrated microcalcification in 5x5x8 mm irregular hypoechoic nonhemorrhagic nodule at infero-posterior of right thyroid gland. Thyroid fine needle aspiration biopsy evaluation was reported as benign. Parathyroid single-photon emission computed tomography (SPECT) showed nearly a 27x48 mm lesion starting from first costosternal joint on the left mediastinal midline surrounding the aortic arch and reaching to parasternal area (Figure 1). Thorax computed tomography (CT) revealed a 46x20x31 mm of hypodense lesion located anterior to aortic arch in anterior mediastinal fatty tissue. The patient was transferred to thoracic surgery department for surgical excision of the adenoma. Parathyroid adenectomy was performed via left video assisted thoracoscopic surgery (VATS) (Figure 2). After operation within few hours PTH was decreased 50% of preoperative levels. Postoperative first day both Ca (6.79 mg/dL) and PTH (150 pg/mL) levels were decreased and P level turned to normal range (3.1 mg/dL).

## DISCUSSION

There are four parathyroid glands. Two of them in the bottom and other two at the top on both sides of thyroid gland location. During embryogenesis the upper parathyroid glands migrate with lateral thyroid tissue and lower parathyroid glands migrate with thymus. Because of the track can be regarded quite long, parathyroid glands may be seen in any region from carotid bifurcation to pericardium.<sup>5,6</sup> The most significant laboratory finding in primary hyperparathyroidism is hypercalcemia. Furthermore, there may be hypophosphatemia, hyperchloremia, increased Alkaline phosphatase (ALP) and excretion of urinary calcium.<sup>7</sup> In primary hyperparathyroidism, asymptomatic hypercalcemia is the most frequent finding. Skeletal, urinary and gastrointestinal system symptoms may be seen in symptomatic patients. Bone pain may be seen in patients. Demineralization, pathologic fractures, bone cysts and deformities are frequent findings. Due to osteoclastic activity, osteitis fibrosa cystica may occur.<sup>8</sup> Kidney stones, polyuria and polydipsia may be seen.<sup>9</sup> In our case, lytic lesions were shown in bone graphs and in bone mineral densitometry osteoporosis was reported. Long term hypercalcemia and irreversible renal damage due to precipitation of calcium into renal parenchyma may lead to acute renal failure. However, there was no abnormality in renal function tests of our patient.

USG, magnetic resonance imaging (MRI) and CT are used in detection of parathyroid adenomas. Tc-99m sestamibi SPECT is the most important imaging method for detection of ectopic parathyroid adenomas.<sup>10</sup> In our case, by using Tc-99m sestamibi scintigraphy, increased activity was observed in mediastinum and diagnosis of ectopic parathyroid adenoma was supported by thorax CT investigation.

The only curative treatment of primary hyperparathyroidism due to adenomas is surgical excision.<sup>11</sup> Although it is rare, ectopic location of adenoma always should be kept in mind. Intraoperative gamma probe during surgery is a very useful device to differentiate the ectopic parathyroid

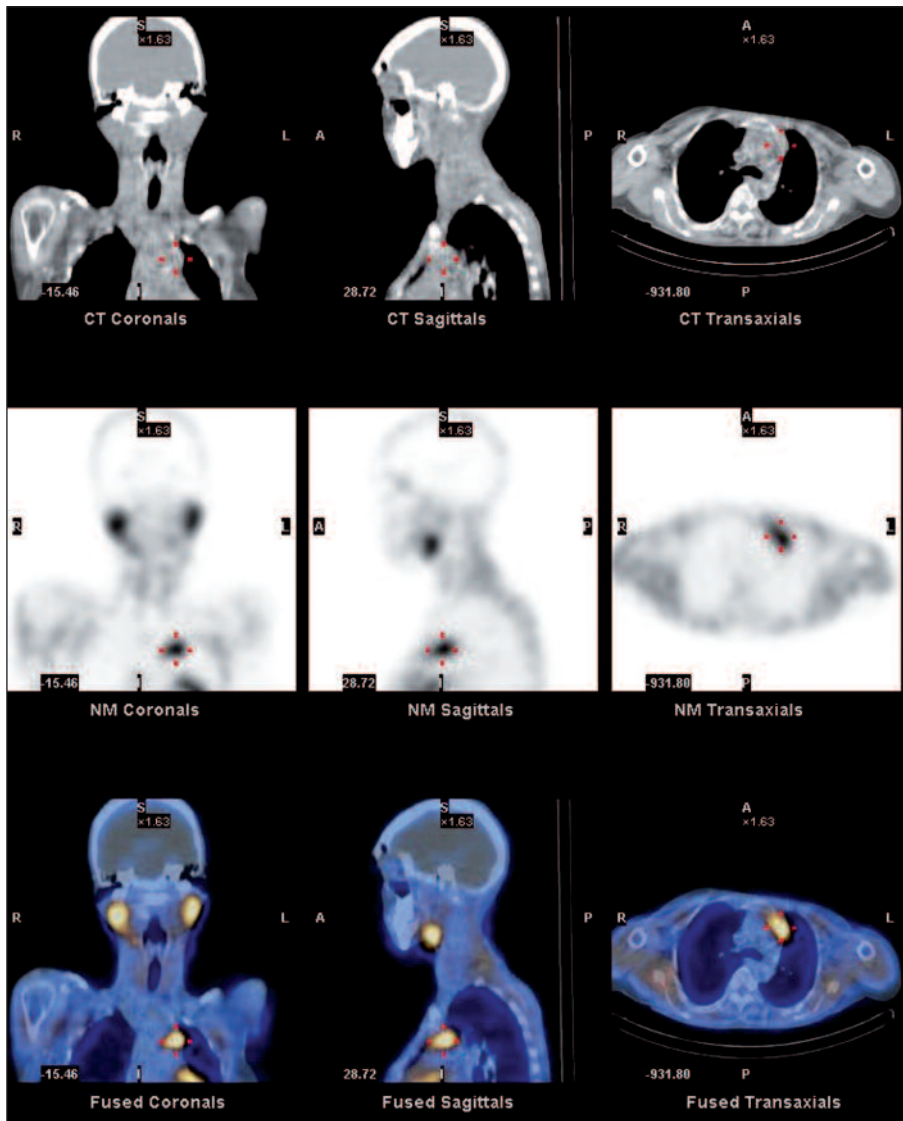


FIGURE 1: Parathyroid SPECT of the lesion seen in the mediastinum.

adenoma from surrounding tissues for complete surgical excision.

It is estimated that 11%-25% of all ectopic parathyroid glands are present in the mediastinum and 2% of these are not accessible through a cervical incision.<sup>12</sup> These cases require sternotomy or thoracotomy, which has a morbidity rate that approaches 20%.<sup>13</sup> In the anterior mediastinal compartment, VATS has been widely applied as a less invasive procedure. It is feasible and less invasive; the incision is small therefore the postoperative pain is less. Parasternal mediastinotomy (Chamberlain procedure) may be an alternative approach

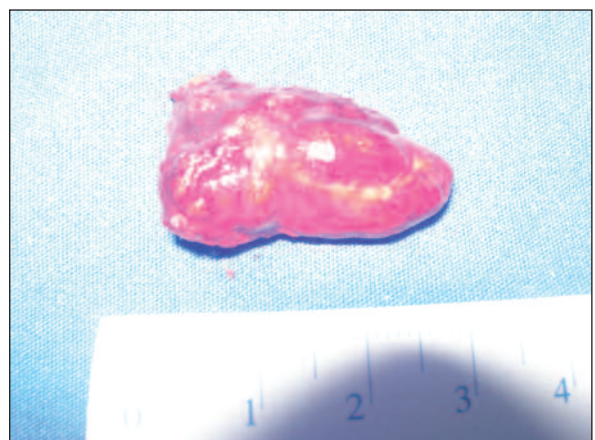

FIGURE 2: The parathyroid adenoma after the left video assisted thoracoscopic surgery (VATS).

in the resection of anterior mediastinal parathyroid adenomas. As in this case VATS performed through two trochars with 2-3 cm of skin incisions, its cosmetic result is superior to Chamberlain procedure. In the literature it is recommended that ectopic mediastinal parathyroid adenomas may be accurately resected using video-assisted thoracic surgery to avoid open approaches.<sup>14</sup>

We concluded that VATS resection of an ectopic parathyroid gland in the anterior mediastinum may be simple and effective than thoracotomy. This approach is less invasive than sternotomy and thoracotomy, and if possible it should be first choice method for resection of ectopic parathyroid glands in the anterior mediastinum.

## REFERENCES

1. Fraser WD. Hyperparathyroidism. *Lancet* 2009;374(9684):145-58.
2. Phitayakorn R, McHenry CR. Incidence and location of ectopic abnormal parathyroid glands. *Am J Surg* 2006;191(3):418-23.
3. Khoo LT, Beisse R, Potulski M. Thoracoscopic-assisted treatment of thoracic and lumbar fractures: a series of 371 consecutive cases. *Neurosurgery* 2002;51(5 Suppl):S104-17.
4. Dağlı G, Fındık G, Öztürk F, Hazer S, Şahin M, Yazıcı Ü, et al. [Ectopic parathyroid adenoma]. *Solunum Hastalıkları* 2010;21(2):56-9.
5. Lumachi F, Zucchetta P, Varotto S, Polistina F, Favia G, D'Amico D. Noninvasive localization procedures in ectopic hyperfunctioning parathyroid tumors. *Endocr Relat Cancer* 1999;6(1):123-5.
6. Caporale DM, Bobbio A, Accordino R, Ampollini L, Internullo E, Cattelani L, et al. Ectopic mediastinal parathyroid adenoma. *Acta Biomed* 2003;74(3):157-9.
7. Lal G, Clark OH. Primary hyperparathyroidism: controversies in surgical management. *Trends Endocrinol Metab* 2003;14(9):417-22.
8. Harman M, Algün E, Ayakta H, Sakarya ME, Etlük O. [Multidetector computed tomography in the diagnosis of parathyroid adenomas: contribution of contrast enhancement pattern to diagnosis]. *Tani Girişim Radyol* 2004;10(3):204-9.
9. Pietschmann F, Breslau NA, Pak CY. Reduced vertebral bone density in hypercalciuric nephrolithiasis. *J Bone Miner Res* 1992;7(12):1383-8.
10. Ishibashi M, Nishida H, Hiromatsu Y, Kojima K, Uchida M, Hayabuchi N. Localization of ectopic parathyroid glands using technetium-99m sestamibi imaging: comparison with magnetic resonance and computed tomographic imaging. *Eur J Nucl Med* 1997;24(2):197-201.
11. Kearns AE, Thompson GB. Medical and surgical management of hyperparathyroidism. *Mayo Clin Proc* 2002;77(1):87-91.
12. Dinçer SI, Demir A, Kara HV, Günlüoğlu MZ. Thoracoscopic removal of a maternal mediastinal ectopic parathyroid adenoma causing neonatal hypocalcemia: a case report. *Ann Thorac Cardiovasc Surg* 2008;14(5):325-8.
13. Prinz RA, Lonchyna V, Carnaille B, Wurtz A, Proye C. Thoracoscopic excision of enlarged mediastinal parathyroid glands. *Surgery* 1994;116(6):999-1004.
14. Medrano C, Hazelrigg SR, Landrenau RJ, Boley TM, Shawgo T, Grascch A. Thoracoscopic resection of ectopic parathyroid glands. *Ann Thorac Surg* 2000;69(1):221-3.