

Myelomatous Pleural Effusion: A Rare Involvement in Multiple Myeloma: Case Report

Miyelomatöz Plevral Efüzyon: Multipl Miyelomda Nadir Bir Tutulum

Nevin Taci HOCA, MD,^a
Oğuz ÖZGEDİK, MD,^a
Mehtap AYDIN ÖZCAN, MD,^b
Filiz ÇİMEN, MD,^a
Nilgün ALPTEKİNOĞLU, MD,^a
Mihriban ÖĞRETSOY, MD^a

Clinics of

^aThoracic Diseases,

^bMedical Pathology,

Atatürk Chest Diseases and

Thoracic Surgery Training and

Research Hospital, Ankara

Geliş Tarihi/Received: 14.05.2009

Kabul Tarihi/Accepted: 24.02.2010

The abstract of this article was presented as a poster at TÜSAD 29th National Congress, 28-31 October 2007, Muğla, Turkey.

Yazışma Adresi/Correspondence:

Nevin Taci HOCA, MD

Atatürk Chest Diseases and

Thoracic Surgery Training and

Research Hospital,

Clinic of Thoracic Diseases, Ankara,

TÜRKİYE/TURKEY

nevintacihoca@yahoo.com

ABSTRACT Multiple myeloma is a neoplastic disorder caused by the proliferation of a single plasma cell clone and is associated with the production of monoclonal immunoglobulin. Multiple myeloma rarely involves the pleura, and this involvement indicates an unfavorable prognosis. We report a 53-year-old man with multiple myeloma and a myelomatous right-sided pleural effusion with elevated adenosine deaminase (ADA) activity. The diagnosis was made by examination of the pleural fluid cytology and pleural biopsy specimen. Systemic chemotherapy was administered to the patient, and pleurectomy was performed. However, the patient died 3.5 months after the diagnosis. Increased ADA activity may be observed in myelomatous pleural effusion, and it may mimic tuberculous pleuritis.

Key Words: Pleural effusion; adenosine deaminase; multiple myeloma

ÖZET Multipl miyeloma tek bir plazma hücre klonunun proliferasyonunun sebep olduğu, neoplastik bir bozukluktur ve monoklonal immünoglobulin üretimi ile ilişkilidir. Multipl miyeloma nadiren plevrayı tutar ve bu tutulum olumsuz bir prognoza işaret eder. Biz multipl miyelomasi ve artmış adenosin deaminaz (ADA) aktivitesi ile sağ taraflı miyelomatöz plevral efüzyonu olan 53 yaşında bir erkek hasta bildiriyoruz. Tanı plevral sıvı sitolojisi ve plevral biyopsi örneği incelenerek konuldu. Hastaya sistemik kemoterapi verildi ve plöredez yapıldı, ancak hasta tanıdan 3.5 ay sonra öldü. Miyelomatöz plevral efüzyonda ADA aktivitesinde artış gözlenebilir ve bu durum tüberküloz plöriti taklit edebilir.

Anahtar Kelimeler: Plevral efüzyon; adenosin deaminaz; multipl miyelom

Türkiye Klinikleri J Med Sci 2011;31(4):998-1001

Pleural involvement in multiple myeloma is distinctly rare and accepted as an indicator of an unfavorable prognosis.¹⁻³

A high adenosine deaminase (ADA) level in the pleural fluid is especially frequent in pleural involvement due to tuberculosis and malignant and lymphoproliferative disease.⁴

We present a case with myelomatous pleural effusion in which a significantly increased pleural fluid ADA level was detected. To our knowledge, this is the fourth case showing a high ADA activity in pleural effusion due to multiple myeloma.

doi:10.5336/medsci.2009-13482

Copyright © 2011 by Türkiye Klinikleri

CASE REPORT

A 53-year-old male patient was transferred to our clinic from another center with complaints of dyspnea, cough, and fever of two months. The thoracic magnetic resonance imaging (MRI) performed in November 2004 for back pain showed a compression fracture on the T8-T9 vertebral corpuses, kyphosis deformation at this level, and effacement of the epidural fat distance. The cranial MRI was normal. The patient was investigated for hypercalcemia, and the bone marrow biopsy led to a diagnosis of Lambda type multiple myeloma. The patient received seven chemotherapy cycles consisting of vincristine, adriamycin, and dexamethasone. Palliative radiotherapy was also applied to the vertebrae. The patient then used thalidomide for one year, but this treatment was stopped due to the development of peripheral neuropathy. The patient was admitted to our clinic in August 2006. The patient had a smoking history of 70 pack-years. Physical examination revealed no respiratory sounds at the basal section of the right hemithorax. Laboratory examination results were as follows: hemoglobin 8.4 g/dL, erythrocyte sedimentation rate 80 mm/h, C-reactive protein 111 mg/L (N: 0-6 mg/L), total protein 5.9 g/dL, albumin 2.4 g/dL and lactate dehydrogenase (LDH) 1536 IU/L. Other laboratory parameters were normal.

Posteroanterior chest x-ray showed a homogenous density increase due to pleural effusion covering the sinuses and effacing the diaphragm and cardiac contour in the right lower zone (Figure 1).

Fifty milliliters of hemorrhagic liquid was evacuated from the right hemithorax by thoracentesis. The pleural effusion analyses were as follows: glucose 51 mg/dL, albumin 1.4 g/dL, total protein 2.9 g/dL, LDH 4820 IU/L and ADA 198.8 U/L (normal value: < 45 U/L). The pleural fluid acid-resistant bacilli smear was negative. There was no growth in the pleural fluid cultures.

A pleural biopsy was performed (Abrams needle). Microscopic examination of the smears prepared from the pleural fluid showed that cells that were mitotic and apoptotic, mostly with eccentric nuclei, some with perinuclear halo and some with

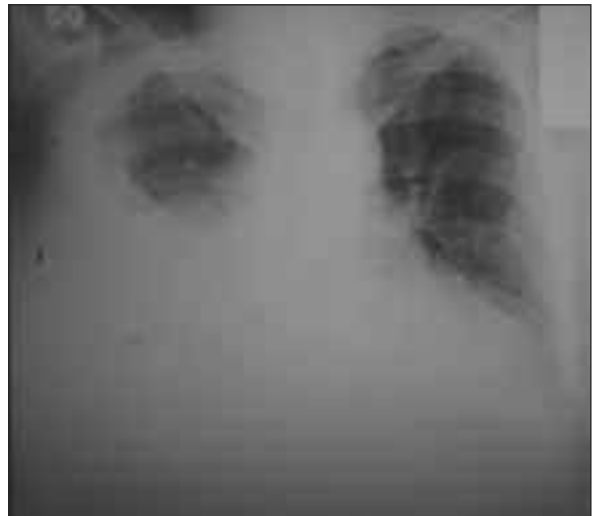

FIGURE 1: Chest x-ray showed a homogenous density increase due to pleural effusion covering the sinuses and effacing the diaphragm and cardiac contour in the right lower zone.

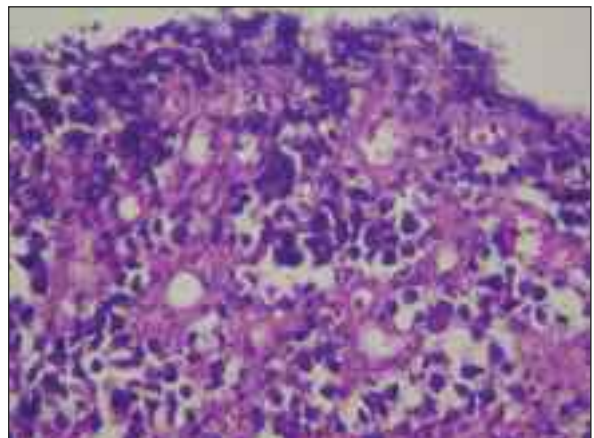


FIGURE 2: Atypical cells representing single infiltration seen in the pleural biopsy material (HE, x200).

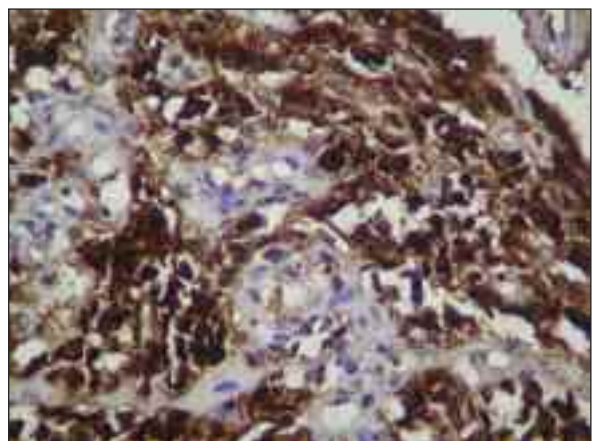


FIGURE 3: Lambda positively observed on immunohistochemical staining (x200).

bilobular or multilobular nuclei. The pleural biopsy contained a tumoral lesion with diffuse infiltration on microscopy. The tumor consisted of single atypical cells, some eccentrically placed, with hyperchromatic nuclei, granular chromatin and eosinophilic cytoplasm (Figure 2). There was a strong positivity for lambda on immunohistochemical tests (Figure 3).

There was no staining with kappa, CD45, CD56 and panceratin. The diagnosis of plasmacytoma infiltration was made after histological and immunohistochemical tests and cytological analyses.

Thoracenteses were repeated to drain 3000 ml of fluid to relieve the shortness of breath. Talc pleurodesis was performed after fluid drainage since fluid was accumulating rapidly after the repeated thoracenteses.

One cycle of bortezomib (1.3 mg/m²/day on day 1, 4, 8 and 11) had been administered but was discontinued when peripheral neuropathy findings increased. Melphalan (6 mg/m², four days) and prednisone (60 mg/m², 4 days) chemotherapy was started. Pleural effusion developed again and was drained by percutaneous pleural catheter administration. Despite therapy, the patient showed a downhill course and died 3.5 months after the pleural involvement due to multiple myeloma.

DISCUSSION

Multiple myeloma is a malignancy characterized by uncontrolled proliferation of plasma cells that is usually limited to the bone marrow. Extramedullary involvement can occur occasionally in the nasopharynx, upper respiratory tract, or gastrointestinal tract.^{5,6} Pleural involvement in multiple myeloma is rare.^{1,2} Kintzer et al have reported the general pleural effusion rate as 6% and the myelomatous effusion rate as 0.8% in their study on 958 multiple myeloma patients.¹ Our patient showed an unusual extramedullary spread to the pleura with an aggressive disease.

Thoracic involvement by multiple myeloma may be in the form of bone lesions, plasmacytoma, pulmonary infiltration, and pulmonary effusion. Myelomatous effusion may be the result of pleural

involvement by the thoracic bone structure or parenchymal tumor, direct implantation of the tumor, or by mediastinal lymph node involvement causing lymphatic obstruction.¹ We had observed thoracic vertebral involvement in our case, and this is the probable cause of pleural involvement.

The pleural involvement is patchy, and it may not always be possible to make a pathological diagnosis with pleural biopsy. Three criteria are necessary to diagnose myelomatous pleural effusion; to demonstrate monoclonal proteins in pleural fluid electrophoresis, atypical plasma cells in the pleural fluid, and/or pleural involvement in pleural biopsy.² A diagnosis of myelomatous pleural effusion was made in this case following the demonstration of atypical plasma cells in the pleural fluid and involvement in the pleural biopsy.

There may be reactive plasma cells in the pleural fluid secondary to cardiac surgery, tuberculosis, HIV-related infections, collagen tissue disease, Hodgkin's disease and carcinomatosis.⁴ High cellularity with a predominant plasma cell population featuring immature and atypical plasma cells would favor a diagnosis of myelomatous effusion over a reactive one.

A high ADA level in the pleural fluid is especially frequent in pleural involvement due to tuberculosis but it has also been shown to be present in empyema, lymphoma, rheumatoid arthritis and malignancies.⁴ There is a case report, by Rodriguez et al, regarding a high ADA level (61U/L) in the pleural fluid of an IgA-K multiple myeloma.⁷ To our knowledge, this is the fourth case showing a high ADA activity in pleural effusion due to multiple myeloma.⁷⁻⁹ The increased ADA activity in benign disease especially tuberculous pleurisy and malignant disease is due to lymphocyte activation.⁴ Especially in countries with high prevalence of tuberculosis, when increased ADA level (>70 IU/L) in pleural fluid was shown, misdiagnosis of tuberculous pleuritis can be made. This case report is important because it shows that increased pleural fluid ADA level can be due to malignant pleural effusions. Therefore, in all cases with high ADA levels, malignancies especially lymphoproliferative

ones should be ruled out and for indistinctive cases pleural fluid examination for acid-fast bacilli and pleural biopsy must be done.

Myelomatous effusion in multiple myeloma is associated with poor prognosis.^{3,10,11} Meoli et al investigated 58 reported patients and found that 30 (51.7%) died within four months and 12 (20.7%) lived more than four months while the survival pe-

riod had not been reported for 16 patients (27.6%).³ Palmer et al reported that 90% of 56 patients died within a year.⁴ Our case died 3.5 months after receiving a diagnosis of myelomatous effusion.

In conclusion, pleural involvement in multiple myeloma reflects aggressive disease and increased ADA activity may be observed in myelomatous pleural effusion.

REFERENCES

1. Kintzer JS Jr, Rosenow EC 3rd, Kyle RA. Thoracic and pulmonary abnormalities in multiple myeloma. A review of 958 cases. *Arch Intern Med* 1978;138(5):727-30.
2. Palmer HE, Wilson CS, Bardales RH. Cytology and flow cytometry of malignant effusions of multiple myeloma. *Diagn Cytopathol* 2000;22(3):147-51.
3. Meoli A, Willsie S, Fiorella R. Myelomatous pleural effusion. *South Med J* 1997;90(1):65-8.
4. Light RW. Clinical manifestations and useful tests. *Pleural Diseases*. 3rd ed. California: Williams&Wilkins; 1995. p.36-74.
5. Bataille R, Harousseau JL. Multiple myeloma. *N Engl J Med* 1997;336(23):1657-64.
6. Tuncer Ü, Aydoğan F, Aydoğan LB, Ergin M. [Tracheal plasmacytoma: a case report]. *Türkiye Klinikleri J Med Sci* 2006;26(2):202-5.
7. Rodríguez JN, Pereira A, Martínez JC, Conde J, Pujol E. Pleural effusion in multiple myeloma. *Chest* 1994;105(2):622-4.
8. Urrutia A, Ribera JM, Rey-Joly C, Foz M. [Myelomatous pleural effusion with elevated adenosine desaminase activity]. *Med Clin (Barc)* 1991;96(6):236.
9. Fernández de Quirós J, Susano RC, Telenti M, Rodríguez C. [Adenosine deaminase in tumors: a marker of the pleural invasion of lymphoproliferative processes?]. *Med Clin (Barc)* 1992;98(7):276-7.
10. Gogia A, Agarwal PK, Jain S, Jain KP. Myelomatous pleural effusion. *J Assoc Physicians India* 2005;53:734-6.
11. Ulubay G, Eyüboğlu FO, Simşek A, Ozyilkın O. Multiple myeloma with pleural involvement: a case report. *Am J Clin Oncol* 2005; 28(4): 429-30.