

Surgical Extrusion of A Complicated Crown-Root Fractured Tooth: Case Report

Komplike Kron-Kök Kırığı Bulunan Bir Dişin Cerrahi Ekstrüzyonu

Hüseyin TEZEL, Dr., Prof.^a
Hüseyin KOCA, Dr., Prof.^b
Tijen PAMİR, Dr., Assoc.Prof.^a
Çiğdem ATALAYIN, Dr., Dt.^a

Departments of

^aRestorative Dentistry and Endodontics,

^bOral and Maxillofacial Surgery,

Ege University Faculty of Dentistry,

İzmir

Geliş Tarihi/Received: 17.08.2010

Kabul Tarihi/Accepted: 23.03.2011

Yazışma Adresi/Correspondence:

Hüseyin TEZEL, Dr., Prof.

Ege University Faculty of Dentistry,

Department of Restorative Dentistry and

Endodontics, İzmir,

TÜRKİYE/TURKEY

huseyin.tezel@ege.edu.tr

ABSTRACT Crown-root fracture is defined as a fracture involving enamel, dentin and pulp. It causes a lot of problems for coronal restoration especially when the fracture line extends below the marginal bone level. There are different treatment alternatives for crown-root fracture. Surgical extrusion is a treatment alternative for elevating sound tooth structure from the alveolar socket. This article presents a case with surgical extrusion of the crown-root fracture and the successful results of five-year follow up. This case report confirms that this technique did not cause any clinical or radiographic pathology; on the contrary, it provided functional and aesthetic success.

Key Words: Tooth fractures; surgical procedures, operative; dental restoration, permanent

ÖZET Mine, dentin ve pulpayı içeren kırıklara kron-kök kırığı adı verilmektedir. Bu durum özellikle kırık hattı marjinal kemik seviyesinin altına kadar uzandığında pek çok soruna neden olmaktadır. Kron-kök kırığı için farklı tedavi seçenekleri mevcuttur. Alveolar soketten sağlam diş dokusunun yükseltilmesi için, cerrahi ekstrüzyon bir tedavi seçeneğidir. Bu olgu sunumunda, cerrahi ekstrüzyon uygulanan bir kron-kök kırığı olgusunun beş yıllık başarılı izlem bulguları bildirilmektedir. Bu bulgular, söz konusu tekniğin klinik ve radyografik olarak herhangi bir patolojiye neden olmadığını ve fonksiyonel ve estetik başarı sağladığını doğrulamaktadır.

Anahtar Kelimeler: Diş kırıkları; cerrahi işlemler, operasyon; diş onarımı, kalıcı

Türkiye Klinikleri J Dental Sci 2012;18(1):144-50

Crown-root fracture is defined as a fracture involving enamel, dentin and pulp. It can be classified as either complicated or uncomplicated.^{1,2} Crown-root fracture can be seen 5% in permanent dentition and 2% in primary dentition. The cause of crown root fracture is generally a traumatic injury.³

The crown-root fracture presents a clinical challenge when the fracture line extends below the marginal bone level. Extraction of the tooth is possibly preferred. However, many treatment alternatives for this kind of fracture may also be recommended:^{1,4,5}

- Periodontal gingival and osseous surgery to expose an adequate amount of tooth structure for a crown margin;

- Orthodontic or surgical extrusion of the root until all the fracture site is supragingival sufficient for restoring the tooth;

- Combined orthodontic extrusion and periodontal gingival and osseous recontouring for adequate margination;

- Fragment recemented even with invasion of the biological width;

- Removing the clinical crown segment and retaining the submerged root with its vital pulp followed by the placement of a fixed bridge across the space.

This article presents a case with surgical extrusion of the crown-root fracture and the successful results of a five-year follow-up.

CASE REPORT

A 32-year-old healthy man applied to the Ege University, Faculty of Dentistry, Department of Restorative Dentistry and Endodontics in February 2004 because of dental pain and esthetic care. He notified the clinician that he had fallen down the stairs two days ago. The patient's extraoral examination was normal however the intra-oral and radiographic examinations revealed a complicated crown-root fracture of the maxillary right lateral incisor. The fracture line extended to the marginal bone level, the coronal fragment was missing and the pulp was exposed to the oral cavity (Figure

1A, 1B). The electrical pulp test response was positive. The patient had both spontaneous and provocative pain. Radiographic examination did not reveal any horizontal root fractures (Figure 2A, 2B).

The patient was informed about the orthodontic and surgical extrusion alternatives. He did not accept the orthodontic extrusion because of psychological stress arising from the appliance, elastics and long treatment period. Thus, we decided to perform surgical extrusion. The patient was asked to sign the 'Patient Instructive Form' before the treatment procedures. Temporary endodontic treatment with calcium hydroxide was initiated before surgical process.

The patient referred to Ege University, Faculty of Dentistry, Department of Oral and Maxillofacial Surgery for surgical extrusion. He was administered local anesthesia (0.125 mg/mL epinephrine, 2 g/mL lidocaine). After anesthesia, gingival tissues were separated by a Bein elevator without causing trauma to the surrounding bone. The tooth was extruded till the fracture line was leveled by canine and controlled for hemostasis (Figure 3A, 3B, 3C).

After the surgical extrusion, tooth was splinted to the right central incisor and right canine with composite resin for two weeks (Figure 4). Antibiotic therapy was prescribed for 10 days and the patient was motivated to maintain oral hygiene.

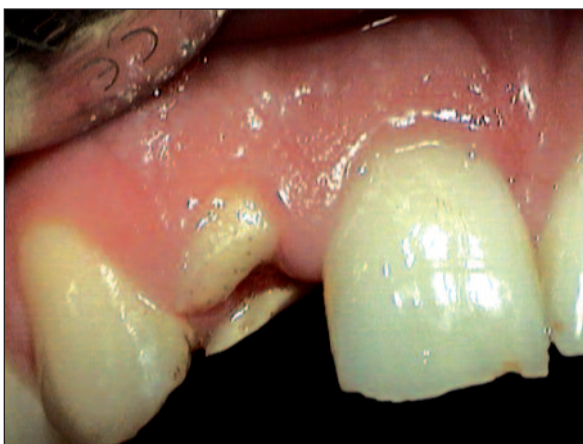

FIGURE 1A: Labial view of the tooth before surgical extrusion. (see for colored form <http://dishekimligi.turkiyeklinikleri.com/>)

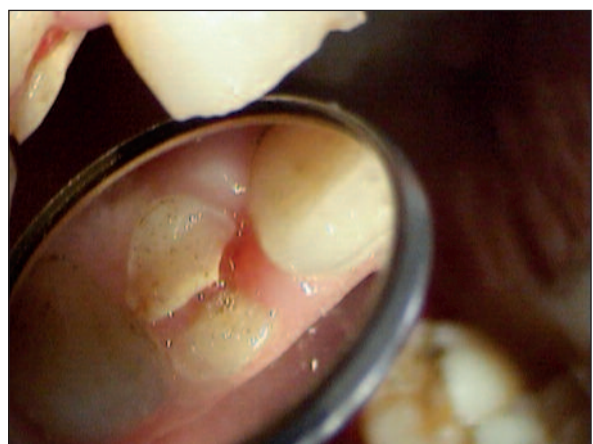

FIGURE 1B: Palatal view of the tooth before surgical extrusion. Note the proliferation of the gingival tissue between the coronal fragments. (see for colored form <http://dishekimligi.turkiyeklinikleri.com/>)

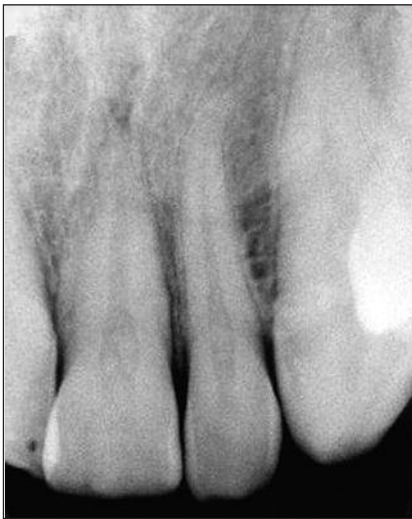

FIGURE 2B: The radiographic image of the other side after trauma.

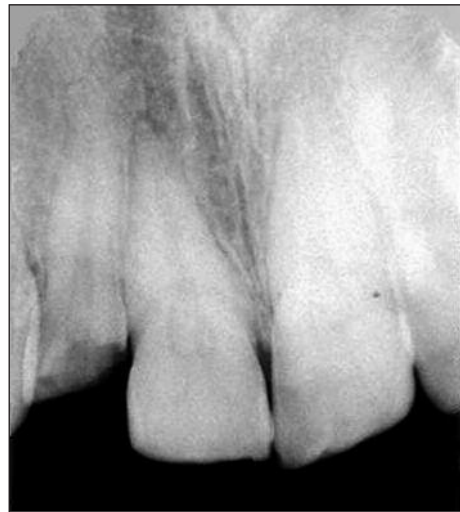

FIGURE 2A: The radiographic image of the tooth after trauma.

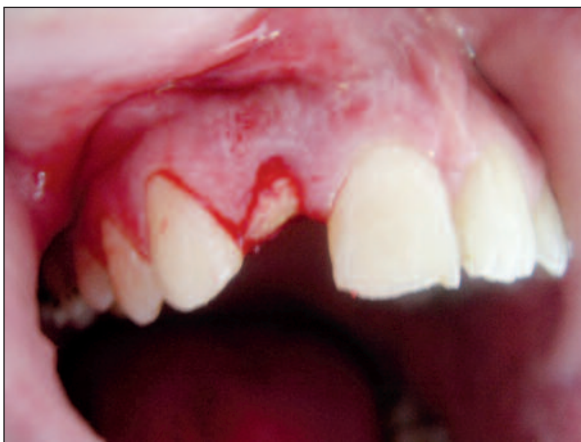

FIGURE 3A: Gingival tissues separated without causing trauma to the surrounding bone.
(see for colored form <http://dishekimligi.turkiyeklinikleri.com/>)

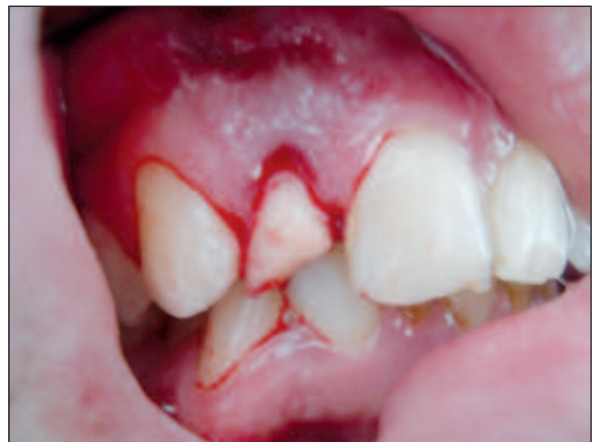

FIGURE 3B: The lateral incisor repositioned inferiorly till fracture line leveled by canine tooth.
(see for colored form <http://dishekimligi.turkiyeklinikleri.com/>)

At the end of the third week, following the mechanical preparation (with hand instruments and step-back technique) and irrigation of the root canal (with 5% EDTA and 2.5% NaOCl solution), the root canal was dried with sterile paper-points and filled with fresh calcium hydroxide paste (calcium hydroxide and barium sulphate powder in a ratio of 8:1 mixed with glycerine as a medium) by means of a lentulo spiral filler in a slow-speed hand piece. The access cavity was sealed with zinc oxide eugenol cement (Alganol, Kemdent, UK). The calcium hydroxide intracanal dressing was changed once at 3-week intervals and maintained for three months. At the end of this pe-

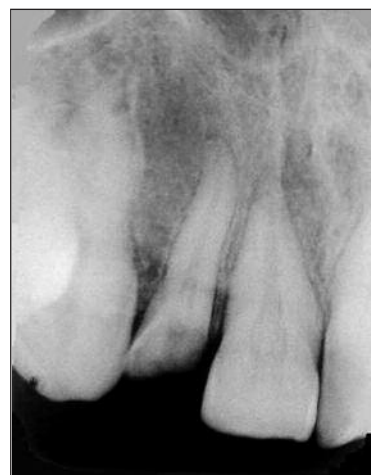

FIGURE 3C: The radiographic image of the tooth after surgical extrusion.

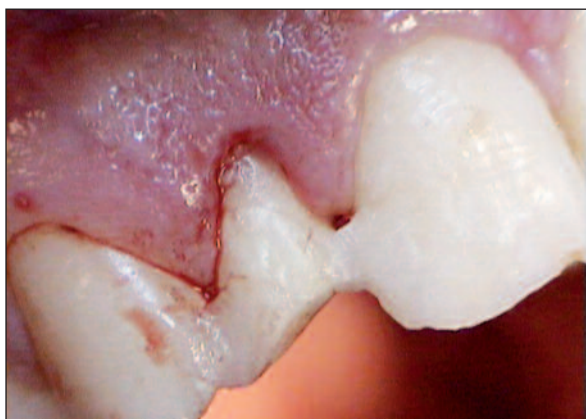


FIGURE 4: Labial view of the tooth after being splinted to adjacent teeth with composite resin.

(see for colored form <http://dishekimligi.turkiyeklinikleri.com/>)

riod, the intracanal dressing was removed, the root canal was irrigated with 2.5% NaOCl, dried with sterile paper-points and obturated with Diaket (Espe GmbH, Seefeld, Germany) and gutta-percha (Hygenic Akron, OH, USA) using cold lateral condensation technique.

Before the fabrication of the porcelain fused-to-metal crown, a metal post was placed into the root canal and a composite core was built up (Figure 5). Then, porcelain fused-to-metal crown was fabricated with conventional technique (Figure 6A, 6B).

Radiographic and clinical examinations were performed on the 3rd, 6th, 12th, 18th, 24th, 30th, 36th, 42nd and 48th months after the trauma, during the five-year follow up. The examinations involved the assessment of mobility, pain, gingival pocket depth, occlusal trauma, ankylosis, marginal bone loss, periapical lesion and root resorption. During the follow-up period, the tooth was clinically asymptomatic and the appearance was normal. Neither post-operative complications nor infection were observed. The gingival pocket depth was normal and the periodontal tissues were healthy. The percussion sound was normal and did not differ from the adjacent healthy teeth, indicating no ankylosis. There were no radiographic signs of progressive root resorption, marginal bone loss or periapical disease (Figure 7A, 7B). The last control was made with computerize tomography (Siemst Somatom Plus 4, Dental CT Programme) in addition to dental periapical radiography and it was revealed that

there was no marginal bone loss, either (Figure 8A, 8B, 8C). The tooth and the restoration were functionally and aesthetically acceptable.

DISCUSSION

Crown-root fracture is generally observed after a traumatic injury and the level and the position of the fracture determine the type of treatment.^{1,2,4} Invasion of the biologic width with traumatic fracture presents a clinical challenge. There are several options for the treatment of tooth fracture involving the biologic width. Crown-root fracture below the gingival attachment and reduced alveolar bone level causes restorative difficulties and extraction is formerly used in many cases. However extraction must not be the first choice of treatment. Loss of a tooth in anterior region may create esthetic and emotional problems especially in young patients, and that's why, alternative treatment modalities must be considered.⁶

Surgical extrusion and orthodontic extrusion have been recommended to save fractured and extremely broken tooth in the anterior region.⁷ Surgical extrusion is a one step procedure which is simpler and less time-consuming than orthodontic extrusion. The treatment requires little time, the esthetics is quickly restored to an acceptable

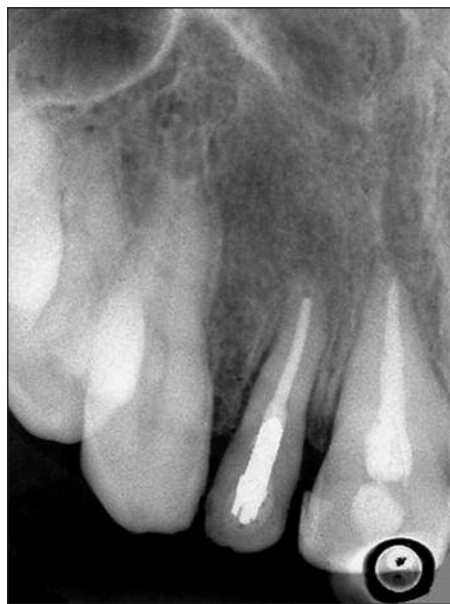

FIGURE 5: The radiographic image of the tooth after the root canal treatment and the placement of the metal post.

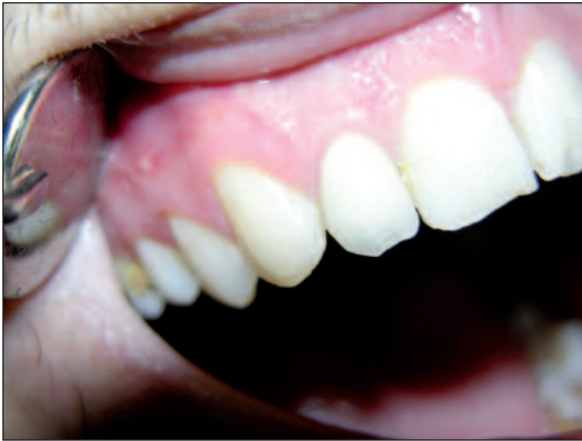

FIGURE 6A: Labial view of the tooth after porcelain fused-to-metal crown was fabricated.

(see for colored form <http://dishekimligi.turkiyeklinikleri.com/>)

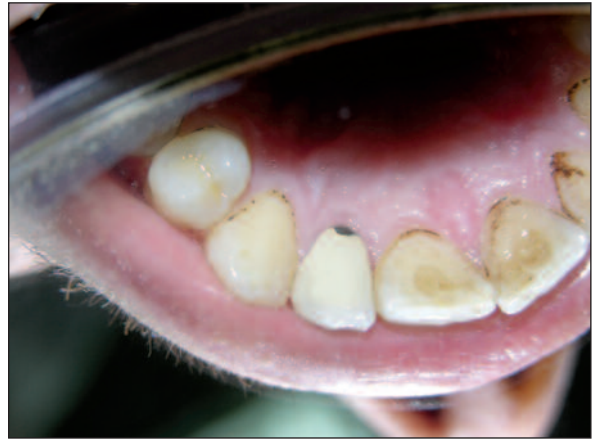

FIGURE 6B: Palatinal view of the tooth after porcelain fused-to-metal crown was fabricated.

(see for colored form <http://dishekimligi.turkiyeklinikleri.com/>)

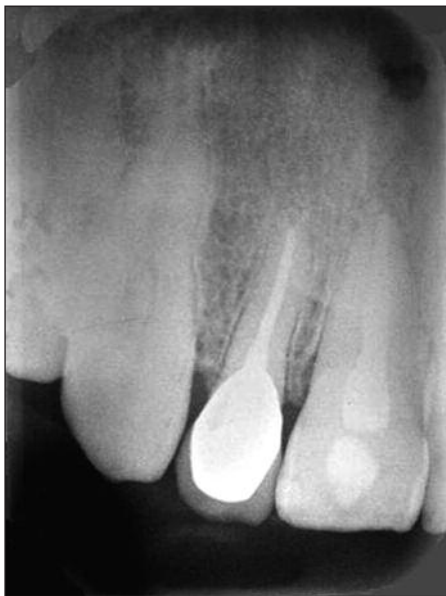

FIGURE 7A: The radiographic image of the tooth after one year.

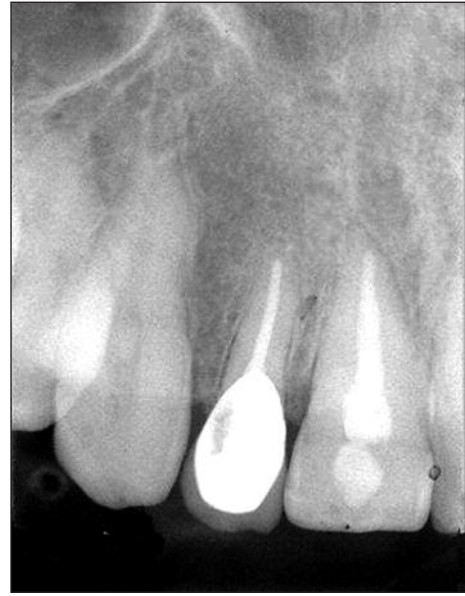

FIGURE 7B: The radiographic image of the tooth after three years.

level, and the procedure is easily accepted by the patient. Orthodontic extrusion restores the physiological periodontal attachment and preserves the alveolar bone; It, however, requires multiple visits and excellent cooperation of the patient.^{6,8,9}

Age-dependent decrease in alveolar bone turnover activity, in response to mechanical forces may negatively affect the amount of tooth movement. Thus, it is recommended to apply low force during long period for adults to supply safe orthodontic tooth move.^{10,11} In our case we firstly de-

cided to prepare orthodontic appliance with elastics, but our patient did not want to use the appliance or elastics because of the psychological stress and long treatment period. Therefore, we decided to apply surgical extrusion.

Kahnberg, described two different surgical extrusion techniques.^{12,13} The first technique involved intraalveolar transplantation with or without bone transplants and avoided surgery in the periapical area and kept apical area isolated from the oral cavity, reducing the incidence of root resorption of the

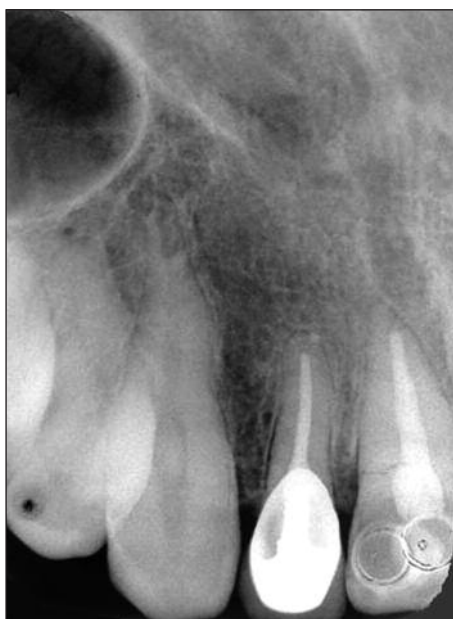

FIGURE 8A: A five-years follow-up radiograph showing no root resorption and marginal bone loss.

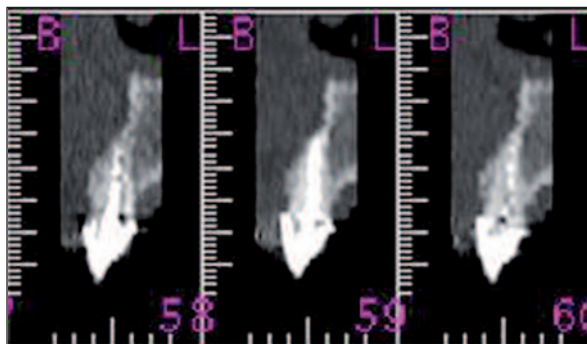


FIGURE 8B: The view of the maxilla obtained from computerized tomography after five years (Siemens Somatom Plus4, Dental CT Programme). (see for colored form <http://dishekimligi.turkiyeklinikleri.com/>)

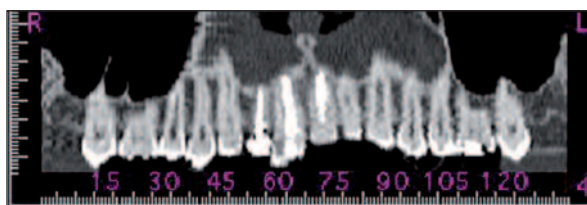


FIGURE 8C: The image obtained from CT was spirally scanned with 1 mm of cross-section after five years. (see for colored form <http://dishekimligi.turkiyeklinikleri.com/>)

tooth. The second technique involved careful extrusion of the tooth by marginal luxation with elevators and stabilization with splints.¹³ We used the second technique and an extrusion of about 7 mm

was obtained and no root resorption was observed during the follow-up period.

Dehydration of the root surface cells can lead to ankylosis and root resorption.^{14,15} The viability of the cementoblast is very important for the healing of the socket and the formation of a new, functioning periodontal membrane.¹² In our case, the tooth was kept in its alveolar housing. The periodontal ligament was kept intact and after the surgical extrusion, tooth was splinted to adjacent teeth with composite resin for two weeks to promote periodontal repair. By means of this procedure, there were no radiographic signs of progressive root resorption, and the percussion sound was normal; similar to healthy adjacent teeth, indicating no ankylosis.

When alveolar bone is subjected to a surgical procedure, a loss of osseous crest may be expected during healing.¹⁶ The loss of marginal bone was examined with radiographic controls during the follow-up period. It is known that dental periapical radiography supplies only two dimensional image, and it is insufficient to examine the changes of alveolar bone. However, computerize tomography is a developed technique which supplies three dimensional image. Therefore, in this study, computerize tomography (Siemens Somatom Plus 4, Dental CT Programme) was used together with dental periapical radiography for the last radiographic control to examine root resorption and/or alveolar bone loss (Figure 8B). Then the image obtained from CT was spirally scanned with 1 mm of cross-section (Figure 8C) and the examination revealed that there was no loss of marginal bone or root resorption.

The use of intracanal calcium hydroxide is effective for the control of contamination, infection and resorption.¹⁷ On the other hand, it has been speculated that calcium hydroxide passing through the apical foramen damages the periodontal ligaments causing resorption and ankylosis.¹⁸ In our case, the calcium hydroxide intracanal dressing was maintained for three months and there were no signs of mobility, tenderness, or pain indicating underlying pathology.

Surgical extrusion is a predictable treatment alternative for a fractured tooth when the fracture line extends below the marginal bone level. In this process, the root should be elevated until the fractured site is above the gingival level to be able to restore the tooth sufficiently. This article presents a case with surgical extrusion of the crown-root fracture and the results of a five-year follow-up indicate that this technique did not cause any clinical or radiographic pathology; on the contrary, it

provided functional and aesthetic success. Under successful conditions of our case, we can recommend the surgical extrusion of teeth with crown-root fractures as an alternative multi-disciplinary treatment approach when the orthodontic procedures are not accepted or preferred by the patients.

Acknowledgement

We sincerely thank Gül Kayrak for language editing.

REFERENCES

1. Andreasen JO, Andreasen FM. Crown-root fractures. Textbook and Color Atlas of Traumatic Injuries to the Teeth. 3rd ed. Copenhagen: Munksgaard: 1994. p.257-77.
2. Andreasen JO, Andreasen FM. Classification, etiology and epidemiology. Textbook and Color Atlas of Traumatic Injuries to the Teeth. 3rd ed. Copenhagen: Munksgaard: 1994. p.151-80.
3. Alaçam A. [Tooth injuries caused by trauma and treatments]. Alaçam T, Uzel İ, Alaçam A, Aydın M, editörler. Endodonti. 2. Baskı. Ankara: Barış Yayınları: 2000. p.607-35.
4. Baratieri LN, Monteiro S Jr, de Albuquerque FM, Vieira LC, Andrada MA, de Melo Filho JC. Tooth fragment reattachment. In: Baratieri LN, ed. Direct Adhesive Restorations on Fractured Anterior Teeth. Chapter 6. 2nd ed. Sao Paulo: Quintessence Books: 1998. p.134-205.
5. Fountain BS, Camp JH. Traumatic injuries. In: Cohen S, Burns RC, eds. Pathways of the Pulp. 6th ed. Chicago: Mosby; 1994. p.436-85.
6. Kirzioğlu Z, Karayılmaz H. Surgical extrusion of a crown-root fractured immature permanent incisor: 36 month follow-up. Dent Traumatol 2007;23(6):380-5.
7. Koyuturk AE, Malkoc S. Orthodontic extrusion of subgingivally fractured incisor before restoration. A case report: 3-years follow-up. Dent Traumatol 2005;21(3):174-8.
8. Calişkan MK, Türkün M, Gommel M. Surgical extrusion of crown-root-fractured teeth: a clinical review. Int Endod J 1999;32(2):146-51.
9. Calişkan MK. Surgical extrusion of a completely intruded permanent incisor. J Endod 1998;24(5):381-4.
10. McDonald F, Cobourne M. Adult orthodontics: perils and pitfalls. Prog Orthod 2007;8(2):308-13.
11. Misawa-Kageyama Y, Kageyama T, Moriyama K, Kurihara S, Yagasaki H, Deguchi T, et al. Histomorphometric study on the effects of age on orthodontic tooth movement and alveolar bone turnover in rats. Eur J Oral Sci 2007; 115(2):124-30.
12. Kahnberg KE. Intraalveolar transplantation of teeth with crown-root fractures. J Oral Maxillofac Surg 1985;43(1):38-42.
13. Kahnberg KE. Surgical extrusion of root fractured teeth a follow-up study of two surgical methods. Endod Dent Traumatol 1988;4(2): 85-9.
14. Andreasen JO, Kristerson L. The effect of limited drying or removal of the periodontal ligament. Periodontal healing after replantation of mature permanent incisors in monkeys. Acta Odontol Scand 1981;39(1):1-13.
15. Söder PO, Otteskog P, Andreasen JO, Modéer T. Effect of drying on viability of periodontal membrane. Scand J Dent Res 1977;85(3): 164-8.
16. Wilderman MN, Pennel BM, King K, Barron JM. Histogenesis of repair following osseous surgery. J Periodontol 1970;41(10):551-65.
17. Tronstad L. Root resorption etiology, terminology and clinical manifestations. Endod Dent Traumatol 1988;4(6):241-52.
18. Vanderas AP. Effect of intracanal medications on inflammatory resorption or occurrence of ankylosis in mature traumatized teeth: a review. Endod Dent Traumatol 1993;9(5): 175-84.