

## CASE REPORT

DOI: 10.5336/caserep.2024-102805

# Benign Episodic Unilateral Mydriasis with Family History of Migraine Attacks and Alternating Pupils

<sup>id</sup> Alara KILIÇÇIOĞLU<sup>a</sup>, <sup>id</sup> Erkan ACAR<sup>b</sup>, <sup>id</sup> Zeynep ÖZDEMİR<sup>c</sup>

<sup>a</sup>Acıbadem University Faculty of Medicine, İstanbul, Türkiye

<sup>b</sup>Acıbadem University Faculty of Medicine, Department of Neurology, İstanbul, Türkiye

<sup>c</sup>Bakırköy Prof. Dr. Mazhar Osman Mental and Neurological Diseases Training and Research Hospital, Clinic of Neurology, İstanbul, Türkiye

**ABSTRACT** Benign episodic unilateral mydriasis (BEUM) is an isolated benign cause of intermittent pupil asymmetry. The definitive pathophysiology of BEUM is not fully understood, yet many articles published are in favor of a link between ophthalmoplegic migraine and hypoactivity of the parasympathetic nervous system. In this article, we present a 24-year old female who has been diagnosed with BEUM with a family history of migraine attacks, who initially presented with R>L anisocoria. Other than the apparent anisocoria, her examination did not yield any pathologies. Upon another attack 3 months later, during her examination, it was noted that anisocoria had alternated to the other eye (L>R).

**Keywords:** Anisocoria; benign; mydriasis; unilateral; migraine

Benign episodic unilateral mydriasis (BEUM) is a medical condition which primarily affects the size of the pupil, resulting in a temporary dilation of one of the pupils. The size difference between the two pupils is referred to as anisocoria, which is the hallmark of the medical condition. Although the definitive pathophysiology of BEUM is still a topic of research, it is speculated to be secondary to hyperactivity of the sympathetic nervous system or hypoactivity of the parasympathetic nervous system.<sup>1</sup> Previous studies have shown a correlation between BEUM and migraine headaches as well as other symptoms. The most frequently associated symptoms during migraine-related pupil dilation include blurred vision in 56.1%, photophobia in 24.4%, and orbital pain in 17.0%.<sup>1</sup>

This case report showcases a patient who has had recurrent attacks and advised treatment options.

## CASE REPORT

A 24-year-old female was admitted to Acıbadem Maslak University Hospital Neurology outpatient clinic with complaints of blurred vision in left eye and accompanying headache. She states that 6 days prior, whilst she was working, she experienced a dizzy spell and blurred vision. It was also the first time that she has noticed the difference in her pupil size. 2 hours after the spontaneous resolution of the dizzy spell, she reported a headache, which she describes as the worst headache she has experienced. The nature of the headache was bilateral and throbbing, worse at her temples, and she expressed worsening of her symptoms when she was subjected to light, sound, and movement.

She expressed that she did not take any over-the-counter (OTC) medication for the first 24 hours, but

### TO CITE THIS ARTICLE:

Kiliççioğlu A, Acar E, Özdemir Z. Benign episodic unilateral mydriasis with family history of migraine attacks and alternating pupils. Türkiye Klinikleri J Case Rep. 2024;32(4):121-3.

**Correspondence:** Alara KILIÇÇIOĞLU  
Acıbadem University Faculty of Medicine, İstanbul, Türkiye  
**E-mail:** kiliccioglualara@gmail.com



Peer review under responsibility of Türkiye Klinikleri Journal of Case Reports.

**Received:** 15 Mar 2024 **Accepted:** 29 Apr 2024 **Available online:** 13 May 2024

2147-9291 / Copyright © 2024 by Türkiye Klinikleri. This is an open access article under the CC BY-NC-ND license (<http://creativecommons.org/licenses/by-nc-nd/4.0/>).

due to the persistent nature of the throbbing pain, she used numerous and a variety of different nonsteroidal anti-inflammatory drugs (NSAID) on the 2<sup>nd</sup> and 3<sup>rd</sup> days. NSAIDs partly alleviated the headache, but the blurred vision as well as anisocoria did not resolve until the end of the second day. On the 4<sup>th</sup> day, she had no further symptoms.

Her past medical history was significant for episodes with relatively strong headaches for the past three years, as often as 1-2 episodes per year, with a duration of 30 minutes without taking any OTC medications. Upon further questioning, it was noted that her mother also suffered from classic migraine headaches.

At the time of the initial examination, her neurological examination did not yield any pathology. Her blood pressure was within normal range (120/80 mmHg). She had normal light reflexes, her extraocular movements were intact, she had no apparent ptosis or asymmetry. Ophthalmic examination revealed the diameters of her right and left pupils to be 7 mm and 4 mm, respectively, with an apparent anisocoria (R>L) (Figure 1). Visual acuity was 20/16 in both eyes. Visual fields were full. Intraocular pressure was 16 mmHg in both eyes, within normal range.

The patient's routine blood work such as complete blood count, coagulation studies, short metabolic panels and urine analysis did not point to any abnormalities. For further testing, imaging studies were ordered. Magnetic resonance imaging (MRI) of the brain and intracranial MRI Angiography were found to be within normal parameters.

In case of a recurrent attack, she was advised to use NSAID and eletriptan for her migraine headaches. 3 months later, the patient applied with another attack with similar complaints, and upon examination it was noted that she had (L>R) anisocoria (Figure 2). The treatment consisting of NSAID+eletriptan was started promptly, her blurred vision and anisocoria was resolved at the end of her first day. On the second day she had no further symptoms or complaints. Her revised neurological examination did not yield any pathologies.

Due to the nature of her complaints being non-progressive and no obvious pathology being seen in

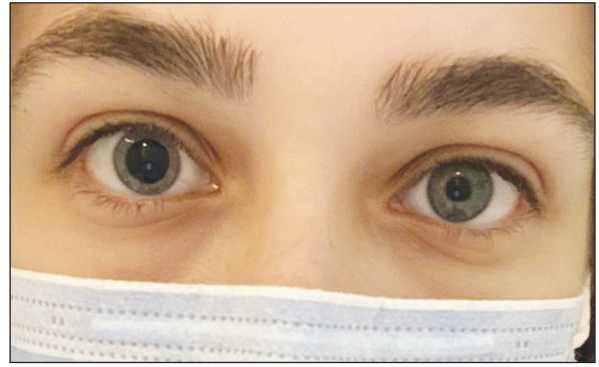


FIGURE 1: Is the (R>L) anisocoria.

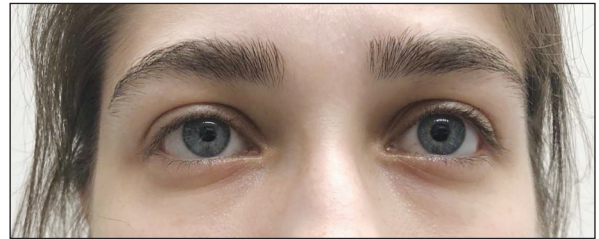

FIGURE 2: Is the (L>R) anisocoria.

further testing, she was diagnosed with BEUM and routine follow-ups were advised to be sufficient enough.

Informed consent has been obtained from the patient.

## DISCUSSION

Anisocoria, the size difference between pupils, is a condition which may be caused by a wide range of physiological or pathological causes. 20% of the anisocoria cases may be physiological, but any case with anisocoria must be diligently researched to exclude any conditions which may be sight-threatening. Intracerebral hemorrhage or ischemic stroke are two examples that require immediate intervention, and they should be excluded in the first approach to preserve both cerebral function and vision. Other causes of pupil asymmetry may include application of topical ophthalmic medications, topical medications applied to the face, orbital cellulitis, third cranial nerve palsy causing inhibition of the parasympathetic short ciliary nerves that cause pupillary constriction, trauma to the orbit damaging the iris sphincter muscle, and angle closure glaucoma.<sup>1</sup>

The case presented above, BEUM, is one of the benign conditions of anisocoria. BEUM usually presents with blurred vision, orbital pain, headaches, photosensitivity, scotoma and confusional state of mind. Past medical history often includes migraine headaches, especially in women, or a family history of migraine headaches are also commonly seen.

Even though the pathophysiology of BEUM is not yet fully understood and a topic of research, in cases of unilateral mydriasis, decreased activity of ipsilateral parasympathetic fibers are thought to be the key player.

A detailed past medical history and family history, including prescribed medications which the patient has been actively using must be questioned. An extensive physical examination, including ophthalmic and neurological system evaluation must be carried out. Laboratory tests and further imaging studies can be used in order to rule out any other potentially life-threatening conditions. These steps are particularly important in order to understand the underlying etiology of the symptoms, and it will take part in determining the most appropriate treatment and management options as well as giving an accurate prognosis.<sup>2,3</sup>

In similar case reports, isolated benign episodic mydriasis (BEM) was reported to have a good neurological prognosis, and it was stated that patients with BEM did not require any further neurodiagnostic studies. Aside from the cosmetic inconvenience and discomfort of migraine-associated symptoms (if present), BEM is a harmless entity, and there is no known irreversible damage to the eye or visual system.<sup>4</sup>

Regarding our patient, absence of a prior migraine attack, acute onset anisocoria, severe headache and blurred vision was regarded as a red-flag and it was deemed appropriate to use further imaging studies in order to exclude diagnoses such as intracerebral hemorrhage, aneurysm and optic neuritis. Once further studies showed no abnormalities in the imaging, spontaneous resolution of the symptoms on the 4<sup>th</sup> day, re-occurrence of a similar attack in the following months, led us to consider the diagnosis of BEUM with migraine headaches.

#### Source of Finance

*During this study, no financial or spiritual support was received neither from any pharmaceutical company that has a direct connection with the research subject, nor from a company that provides or produces medical instruments and materials which may negatively affect the evaluation process of this study.*

#### Conflict of Interest

*No conflicts of interest between the authors and / or family members of the scientific and medical committee members or members of the potential conflicts of interest, counseling, expertise, working conditions, share holding and similar situations in any firm.*

#### Authorship Contributions

**Idea/Concept:** Erkan Acar, Zeynep Özdemir; **Design:** Erkan Acar, Alara Kılıççioğlu; **Control/Supervision:** Erkan Acar, Zeynep Özdemir, Alara Kılıççioğlu; **Data Collection and/or Processing:** Erkan Acar, Alara Kılıççioğlu; **Analysis and/or Interpretation:** Erkan Acar, Alara Kılıççioğlu; **Literature Review:** Alara Kılıççioğlu, Zeynep Özdemir; **Writing the Article:** Alara Kılıççioğlu, Erkan Acar; **Critical Review:** Alara Kılıççioğlu, Erkan Acar; **References and Fundings:** Erkan Acar, Zeynep Özdemir; **Materials:** Erkan Acar, Zeynep Özdemir, Alara Kılıççioğlu.

## REFERENCES

1. Caty JT, Kogan M, Reidy JJ, Siddiqui AH, Farooq O, Li P. A case of recurrent benign episodic unilateral mydriasis and decreased visual acuity and review of the literature. *North American Journal of Medicine & Science*. 2015;8(3):139-42. [[Crossref](#)]
2. Skeik N, Jabr FI. Migraine with benign episodic unilateral mydriasis. *Int J Gen Med*. 2011;4:501-3. [[Crossref](#)] [[PubMed](#)] [[PMC](#)]
3. Jacobson DM. Benign episodic unilateral mydriasis. Clinical characteristics. *Ophthalmology*. 1995;102(11):1623-7. [[Crossref](#)] [[PubMed](#)]
4. Martín-Santana I, González-Hernández A, Tandon-Cárdenes L, López-Méndez P. Benign episodic mydriasis. Experience in a specialist neuro-ophthalmology clinic of a tertiary hospital. *Neurología*. 2015;30(5):290-4. English, Spanish. [[Crossref](#)] [[PubMed](#)]