

# Acute Respiratory Failure Due to Pulmonary Tuberculosis and its Successful Treatment with Medical Therapy: A Case Report

## PULMONER TÜBERKÜLOZA BAĞLI AKUT SOLUNUM YETMEZLİĞİ VE BAŞARILI MEDİKAL TEDAVİSİ

Deniz KÖKSAL, MD,<sup>a</sup> Ayşenaz ÖZCAN, MD,<sup>a</sup> Şeref ÖZKARA, MD<sup>a</sup>

<sup>a</sup>Clinics of Thorax Surgery, Atatürk Thorax Diseases and Thorax Surgery Training and Research Hospital, ANKARA

### Abstract

A 64-year-old male patient who had been hospitalized in an otolaryngology clinic for the evaluation of hoarseness for 20 days was referred to our clinic due to sudden onset of respiratory distress. Indirect laryngoscopy revealed a mass lesion on epiglottis. The patient was severely hypoxemic. Chest radiography revealed bilateral reticulo-nodular infiltrates predominately on the middle zones, a fibrocavitary image and volume loss on right upper zone, blunting of right costophrenic angle and left pleural effusion. High flow oxygen therapy via nasal canule, an empirical regimen of antibiotics, corticosteroid, and diuretic was instituted. On the fourth day of hospitalization sputum smear was positive for acid-fast bacilli and antituberculous therapy was immediately administered despite a mild elevation of liver function tests. After 10 days, due to the further elevation of liver function tests, antituberculous therapy was switched to a non-hepatotoxic regimen. The therapy was continued for 9 months. The mass lesion on the epiglottis disappeared after 2 months of therapy. In conclusion, it is essential to consider tuberculosis (TB) in the differential diagnosis of acute respiratory failure. Rapid diagnosis, immediate and continuous antituberculosis therapy is critical for a successful outcome and good prognosis.

**Key Words:** Tuberculosis, respiratory insufficiency, therapy

Türkiye Klinikleri J Med Sci 2006, 26:449-452

### Özet

Ses kısıklığı nedeniyle 20 gündür bir kulak burun boğaz kliniğinde yatmakta olan 64 yaşındaki erkek hasta, ani gelişen solunum sıkıntısı nedeniyle kliniğimize sevk edilmişti. Yapılan indirekt laringoskopide epiglot üzerinde kitle lezyonu görülmüştü. Hasta ağır hipoksemikti. Akciğer grafisinde, orta zonlarda daha yoğun olmak üzere bilateral retikülonodüler infiltratlar, sağ üst zonda fibrokaviter imaj ve hacim kaybı, sağ kostofrenik açıda küntleşme ve sol hemitoraksta pleural efüzyon mevcuttu. Hastaya nazal kanül aracılığıyla yüksek akımlı oksijen, ampirik antibiyotik, kortikosteroid ve diüretik tedavi verildi. Hastanın hastaneye yatışının 4. gününde balgamda aside dirençli basil teksifi pozitif gelmesi üzerine yapılan, karaciğer fonksiyon testlerinde hafif yükseklik olmasına karşın hemen antitüberküloz tedavi başlandı. On gün sonra, karaciğer fonksiyon testlerinin daha da bozulması üzerine hepatotoksik olmayan rejime geçildi. Tedavi 9 ay sürdürüldü. İki aylık tedavi sonrasında epiglot üzerindeki kitle lezyonunun kaybolduğu görüldü. Sonuç olarak, akut solunum yetmezliğinin ayırıcı tanısında tüberküloz düşünülmelidir. Hızlı tanı, hızlı tedavi ve tedavinin sürekliliği başarılı tedavi yanıtı ve iyi prognoz için önemlidir.

**Anahtar Kelimeler:** Tüberküloz, solunum yetmezliği, tedavi

**P**ulmonary TB is still the leading cause of death due to infectious diseases all over the world.<sup>1</sup> Respiratory failure secondary to miliary and bronchogenic TB is well described in the literature.<sup>2-5</sup> While patients with miliary and disseminated TB are more prone to develop acute

respiratory distress syndrome and respiratory failure requiring mechanical ventilation, patients with bronchogenic TB occasionally present with acute respiratory failure.<sup>6</sup> Several researchers reported the incidence of respiratory failure secondary to pulmonary TB to be 1.5-1.9%.<sup>5,7,8</sup> In this paper we report a patient with pulmonary and epiglottic TB presenting with acute respiratory failure who was treated successfully with antituberculous therapy. The treatment regimen consisted of high flow oxygen therapy via a nasal canule, empirical antibiotic, corticosteroid (60 mg methylprednisolone) and diuretic.

Geliş Tarihi/Received: 01.03.2005 Kabul Tarihi/Accepted: 06.06.2006

**Yazışma Adresi/Correspondence:** Deniz KÖKSAL, MD  
Atatürk Thorax Diseases and Thorax Surgery  
Training and Research Hospital,  
Clinics of Thorax Surgery, ANKARA  
deniz\_koksal@yahoo.com

Copyright © 2006 by Türkiye Klinikleri

## Case Report

A 64-year-old male patient was admitted to our hospital with a 1-month history of hoarseness, dispnea, fatigue, malaise, weight loss, fever and night sweats. During the preceding 20 days he was hospitalized in an otolaryngology clinic for evaluation of hoarseness and indirect laryngoscopy revealed a mass lesion on the epiglottis. He was referred to a chest diseases clinic due to the sudden onset of respiratory distress. The past medical history of the patient was uneventful except for a smoking history of 43 pack-years.

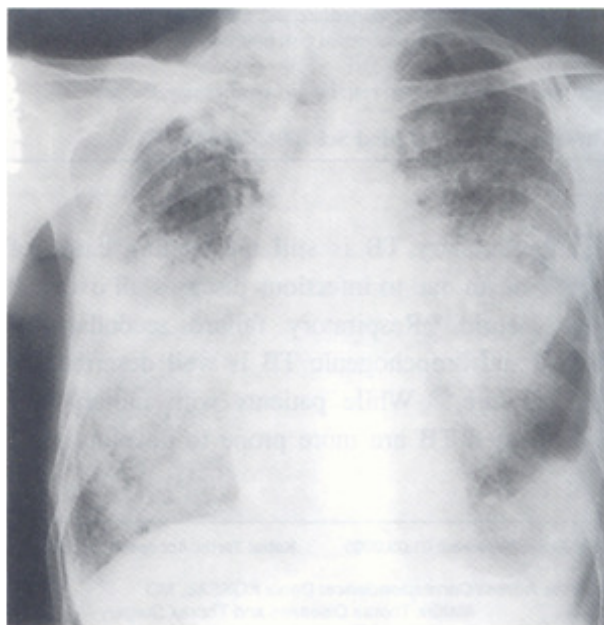On physical examination, temperature was 36.7°C, pulse rate 110/min, respiratory rate 36/min, and arterial blood pressure 100/70 mmHg. He was ortopneic and cyanosed. Chest examination revealed rales on both sides. Lung bases were dull on percussion and respiratory voices were diminished prominently at the base of the left lung. The liver was enlarged and 3 cm palpable below the right costal margin.

On laboratory analysis, arterial blood gas analysis while breathing room air revealed the following: pH 7.39, PaCO<sub>2</sub> 29 mmHg, PaO<sub>2</sub> 34 mmHg, SaO<sub>2</sub> 67%, and HCO<sub>3</sub> 18 mEq/L. Complete blood count, erythrocyte sedimentation rate, and urine analysis were normal. Biochemical analysis revealed increased levels of aspartate aminotransferase (AST: 82 U/L, N: 5-40), alanine aminotransferase (ALT: 55 U/L, N: 5-35), alkaline phosphatase (ALP: 765 U/L, N: 0-270), gamma-glutamyl transferase (GGT: 298 U/L, N: 8-61), lactate dehydrogenase (1886 U/L, N: 230-460), total bilirubin (1.9 mg/dL, N: 0.2-1.3), direct bilirubin (1 mg/dL, N: 0.1-0.2), blood urea nitrogen (43 mg/dL, N: 5-25), and creatinine (1.5 mg/dL, N: 0.5-1.2), and decreased levels of serum sodium (133 mEq/L, N: 135-148), total protein (5.9 g/dL, N: 6.2-8.3), and albumin (2.5 g/dL, N: 3.5-5). Anti-human immunodeficiency virus antibody was negative. Sinus tachycardia was present on electrocardiogram.

A chest radiography showed bilateral reticulo-nodular infiltrates predominantly at the middle zones, a fibrocavitary image and volume loss at the

right upper zone, blunting of right costophrenic angle and left pleural effusion. The cardio-thoracic ratio was normal (Figure 1). On computed tomography (CT) imaging of thorax, there was bilateral fibronodular infiltration at the upper zones prominently at the right and ground glass opacities bilaterally at the middle and lower zones. Ejection fraction was 55% on echocardiography without any hypokinesias. Hepatosteatosi was present on abdominal ultrasonography. Diagnostic thoracentesis from left pleural effusion yielded a transudative effusion.

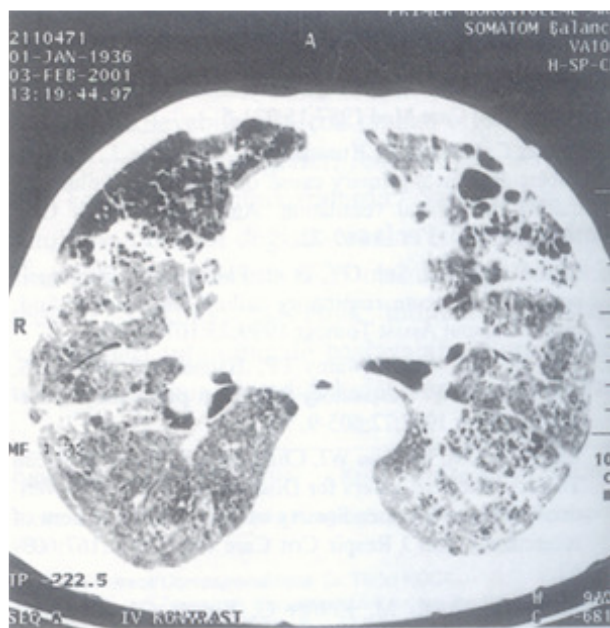
High flow oxygen therapy via nasal canule, empirical antibiotic, corticosteroid (60 mg methylprednisolone) and diuretic therapy was instituted. The patient was quite well with this therapy and did not require mechanical ventilation. On the fourth day of hospitalization sputum smear was positive for acid-fast bacilli and antituberculous therapy was immediately administered with isoniazid (300 mg), rifampicin (600 mg), morphozinamide (2500 mg) and ethambutol (1250 mg). Marked clinical improvement was observed after one week. On the 10<sup>th</sup> day, liver function tests were further elevated (AST: 146 U/L, ALT: 163 U/L, GGT: 359 U/L,



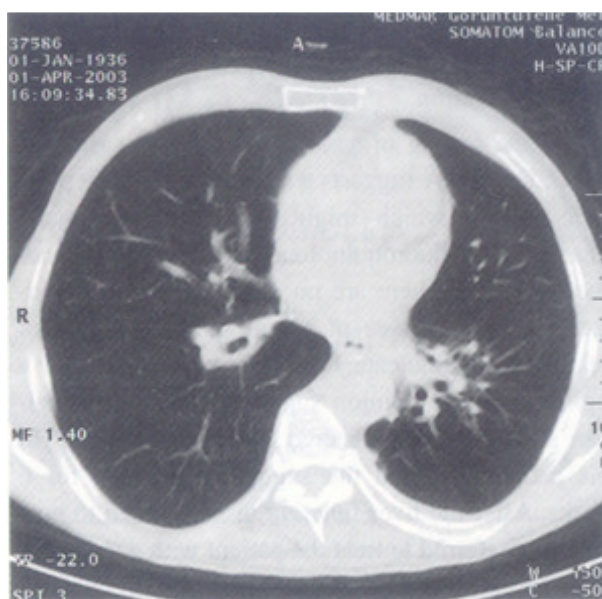
**Figure 1.** Posterior-anterior chest radiography of the patient showing bilateral reticulo-nodular infiltrates predominantly at the middle zones.

ALP: 677 U/L, Total/direct bilirubin: 5/3.6 mg/dL), thrombocyte count decreased ( $36.000/\text{mm}^3$ ) and petechial hemorrhages occurred. The therapy was switched to a non-hepatotoxic regimen (ethambutol 1250 mg, streptomycin 750 mg, ofloxacin 800 mg). After liver function tests and platelet levels returned to normal, isoniazid and rifampicin was administered sequentially and streptomycin, ofloxacin was discontinued respectively.

After 2 months, *Mycobacterium tuberculosis* was isolated from the sputum cultures. It was susceptible to all major drugs. No laryngeal disease could be identified and the mass lesion seen on the epiglottis at baseline was considered to be due to TB. Control echocardiography revealed an ejection fraction of 66%. Due to the persistent presence of interstitial pattern on control thorax CT imaging, fiberoptic bronchoscopy and transbronchial lung biopsy (TBLB) from the right middle lobe were performed (Figure 2). TBLB revealed granulomatous inflammation with caseification. Antituberculous therapy was continued for 9 months and corticosteroid therapy for 3 months. The patient was well in the follow-up period. Control thorax tomography after 2 years revealed the resolution of interstitial lesions (Figure 3).



**Figure 2.** CT of thorax after 2 months of therapy showing interstitial pattern.



**Figure 3.** Control CT of thorax after 2 years showing resolution of the interstitial lesions.

## Discussion

Here we report a patient who was first admitted to an otolaryngology clinic with the major complaint of hoarseness. Then he was referred to our clinic due to acute respiratory distress that did not permit further evaluation for the etiology of hoarseness. Based on clinical, radiological and laboratory findings, an acute interstitial pneumonia, infectious pneumonia or cardiac failure were first considered in the differential diagnoses. Besides, constitutional symptoms such as fever, malaise, fatigue, night sweats and weight loss were strongly suggestive of TB; hence, a sputum smear for acid-fast bacilli was performed and was positive on the 3<sup>rd</sup> sputum sample.

The patient was administered standard antituberculous therapy immediately despite impaired liver functions. Modest elevations of hepatic enzymes are not uncommon in the pretreatment liver function tests of TB patients. It is known that TB itself may involve the liver, causing abnormal liver function; thus, not all abnormalities in liver function tests at baseline should be attributed to causes other than TB.<sup>9</sup> On the tenth day, liver functions were further impaired and thrombocytopenia developed. Due to the critical condition of the pa-

tient, antituberculous therapy was switched to a non-hepatotoxic regimen in order to prevent further deterioration.

In the setting of severe unstable liver disease, ATS/CDC/IDSA suggests a regimen with no hepatotoxic agents, which might include streptomycin, ethambutol, a fluoroquinolone, and another second-line oral drug. There are no data that provide guidance as to the choice of agents or the duration of treatment that indicate the effectiveness of such a regimen. Expert opinion suggests that such a regimen should be administered for 18-24 months.<sup>9</sup> In this patient we used the suggested regimen for 6 weeks. After the liver function tests returned to normal, we preferred to treat the patient with a short and effective regimen including isoniazid and rifampicin.

It was just one week after discontinuation of major antituberculous therapy, the thrombocyte counts returned to normal limits. Although administration of rifampicin is not suggested in a patient who developed thrombocytopenia, we did not want to exclude such a drug with high sterilizing activity. Moreover, rifampicin has the ability to shorten the treatment time. Thus, we preferred to use rifampicin while we strictly controlled the thrombocyte levels. No adverse reactions due to rifampicin were observed.

In pulmonary TB patients presenting with acute respiratory failure, chest radiography most commonly shows bilateral small nodular lesions often accompanied with consolidation or ground-glass opacity, whereas high resolution CT demonstrates findings of miliary or bronchogenic disseminated TB with diffuse areas of ground-glass attenuation.<sup>7</sup> Ground-glass opacities were the predominant pattern on thorax CT images of our patient. They resolved mostly after two months of antituberculous therapy.

Laryngeal TB is a common complication of pulmonary TB and it usually results from the inoculation of infected sputum to the larynx. It must be considered in the differential diagnosis of patients presenting with hoarseness, odynophagia, otorrhea, pharyngitis, or mucous membrane lesions, or with unexplained weight loss, malaise,

fatigue and fever. The vocal folds are the most commonly affected site, closely followed by ventricular bands. The other sites affected are aryepiglottic folds, arytenoids, posterior commissure, subglottis and epiglottis. Epiglottis is the least involved part of the larynx.<sup>10</sup> The response of epiglottic TB to antituberculous therapy is excellent, with most lesions disappearing over a 2-month period, as in the case of our patient. Besides, steroid therapy administered in conjunction with antituberculosis therapy probably diminished the fibrotic reaction that could be a serious therapeutic problem.

In conclusion, it is essential to consider TB in the differential diagnosis of acute respiratory failure. Rapid diagnosis, immediate and continuous antituberculous therapy is important for a successful outcome and good prognosis.

## REFERENCES

1. World Health Organization. WHO Tuberculosis Programme: Framework for effective tuberculosis control. 1994 WHO/TB/94.179.
2. Murray HW, Tuazon CU, Kirmani N, Sheagren JN. The adult respiratory distress syndrome associated with miliary tuberculosis. *Chest* 1978;73:37-43.
3. Dyer RA, Chappell WA, Potgieter PD. Adult respiratory distress syndrome associated with miliary tuberculosis. *Crit Care Med* 1985;13:12-5.
4. Dyer RA, Potgieter PD. The adult respiratory distress syndrome and bronchogenic pulmonary tuberculosis. *Thorax* 1984;39:383-7.
5. Levy H, Kallenbach JM, Feldman C, Thorburn JR, Abramowitz JA. Acute respiratory failure in active tuberculosis. *Crit Care Med* 1987;15:221-5.
6. Penner C, Roberts D, Kunimoto D, Manfreda J, Long R. Tuberculosis as a primary cause of respiratory failure requiring mechanical ventilation. *Am J Respir Crit Care Med* 1995;151(3 Pt 1):867-72.
7. Choi D, Lee KS, Suh GY, et al. Pulmonary tuberculosis presenting as acute respiratory failure: Radiologic findings. *J Comput Assist Tomogr* 1999;23:107-13.
8. Agarwal MK, Muthuswamy PP, Banner AS, Shah RS, Addington WW. Respiratory failure in pulmonary tuberculosis. *Chest* 1977;72:605-9.
9. Blumberg HM, Burman WJ, Chaisson RE, et al. American Thoracic Society/Centers for Disease Control and Prevention/Infectious Diseases Society of America: Treatment of tuberculosis. *Am J Respir Crit Care Med* 2003;167:603-62.
10. Richter B, Fradis M, Kohler G, Ridder GJ. Epiglottic tuberculosis: Differential diagnosis and treatment. Case report and review of the literature. *Ann Otol Rhinol Laryngol* 2001;110:197-201.