

# Medial Canthoplasty with Miniscrew Insertion (A Case Report)

## MİNİVİDA KULLANIMI İLE MEDİAL KANTOPLASTİ (OLGU SUNUMU)

A. Eksal KARGI\*, A. Teoman TELLİOĞLU\*, Şebnem KARGI\*\*, Bülent ERDOĞAN\*, Ömer ŞENSÖZ\*

\* Ankara Numune Hospital Plastic and Reconstructive Surgery Department,

\*\* Ankara Numune Hospital Ophthalmology Department

### Summary

*There are many ways to reconstruct the disrupted medial canthal tendon. In this report, we describe a simple way for medial canthal tendon reattachment. Our technique using a miniscrew is limited to the ipsilateral orbit. It is safe, rapid and has few complications. Therefore it can be used in isolated medial canthal tendon injuries.*

**Key Words:** Medial canthoplasty, Miniscrew

T Klin J Med Sci 1998, 18:406-408

### Özet

*Hasarlanmış medial kantal tendon rekonstrüksiyonu için birçok yöntem mevcuttur. Bu makalede, medial kantal tendon tamiri için kolay uygulanabilir bir yöntem tariflenmiştir. Bir minivida kullanılarak uygulanan teknik ipsilateral orbitle sınırlıdır. Güvenilir, kolay ve az komplikasyona sahiptir. Bu nedenle izole medial kantal tendon yaralanmalarında kullanılabilir bir tekniktir.*

**Anahtar Kelimeler:** Medial kantoplasti, Minivida

T Klin Tıp Bilimleri 1998, 18:406-408

The medial canthal tendon is a complex anatomical structure that arises from the medial margin of the upper and lower tarsi and the orbicularis oculi. It inserts in a tripartate fashion into the region of the lacrimal crest at the medial orbit (1).

The normal bony insertion of the medial canthal tendon can be disrupted after trauma, as a result of ablative surgery or as a consequence of subperiosteal detachment during a craniofacial surgical procedure (1-5). Medial canthoplasty is required to avoid telecanthus following these events (2,4,6).

Several surgical techniques have been described to reattach the tendon to the base of the medial canthal tendon (1,6,7). All techniques require proper repositioning of the tendon deep to the medial orbital rim in the area of the posterior superior lacrimal crest (1,6). The techniques of transnasal wiring has been used widely to reconstruct medial

canthal tendon (8-12). However, some surgeons have preferred the use of ipsilateral techniques that include the nylon anchor suture, the stainless steel screw and miniplates (1,6,7).

This paper presents a medial canthoplasty technique by using a miniscrew.

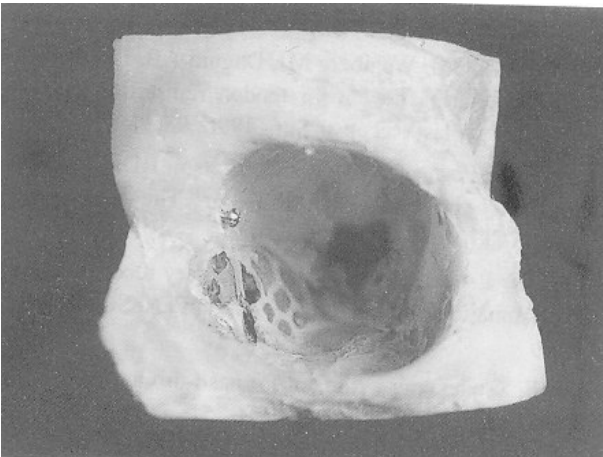
### Case Report

A 25 year-old man presented to our clinic with left telecanthus and epyphora. He sustained multiple facial fractures, including orbital medial wall fracture, in a car accident 2 years ago. The facial fractures were repaired with rigid fixation at another center, but medial canthal tendon repair wasn't performed at that time. Telecanthus occurred completely 22 months later. Epyphora was due to the laceration of the inferior canaliculi. The patient underwent a medial canthopexy with a miniscrew. Under general anaesthesia and after infiltration of the vasoconstriction solution, a small incision is made over the medial canthal area and dissection around the lacrimal fossa is carried out subperiosteally. A hole is drilled at the posterosuperior

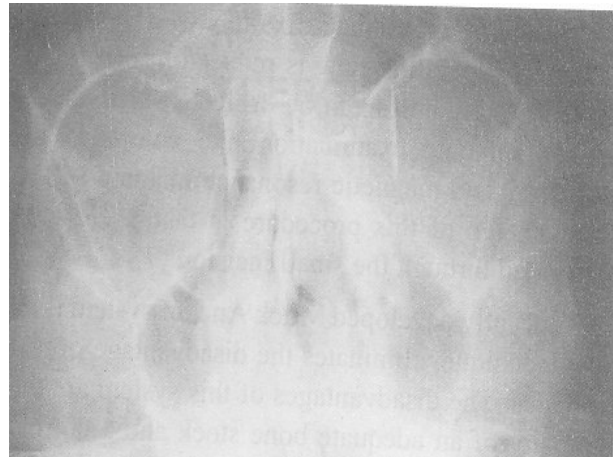
**Geliş Tarihi:** 11.08.1998

**Yazışma Adresi:** Dr.A. Eksal KARGI

Halide Nusret Zorlutuna Sokak.  
5/6 06550 Y.Ayrancı, ANKARA



**Figure 1.** Appearance of the miniscrew on a skeleton model.



**Figure 2.** Postoperative radiographic view of the miniscrew.

point of the posterior lacrimal crest. An 8 mm, titanium miniscrew is placed in the hole, but 2-3 mm of the screw's shaft is left out of the bone (Figure 1). The medial canthal tendon is identified and fully mobilized. The tendon is fixated to the screw with a 3/0 prolene suture. At the same time, dacryocystorhinostomy is performed in order to eliminate epiphora.

Eight months after surgery epiphora stopped, the tendon was in good position and the telecanthus was corrected. Postoperative radiographic view of the miniscrew is shown in Figure 2.

### Discussion

The normal attachment of the medial canthal tendon may be disrupted by different causes. Medial canthal tendon disruption may follow craniomaxillofacial injury, including nasoethmoid fractures, Le Fort II and III fractures (4,6).

Until now, a variety of surgical techniques have been described to reattach the tendon to its normal insertion (1,2,6-8,10-12). Mustarde developed the concept of transnasal wiring in 1966 (13). Since then, transnasal wiring has been a well accepted method for management of naso-orbital fractures with loss of medial canthal insertion and for treatment of congenital telecanthus (6,7). But it requires normal contralateral medial canthus. Additionally, transnasal wiring invades nasal cavity, contralateral ocular and periocular structures (7). On the other hand, the procedure is technically difficult, necessitates wide exposure and dissection

to allow transverse passage of a wire and protection of the contralateral orbit (1).

Limitations of transnasal wiring include the risk of injury to ocular and periocular structures, pressure necrosis and skin ulceration, intranasal hemorrhage and bilateral scarring (11). As a result of these disadvantages of transnasal canthopexy, techniques that permit ipsilateral fixation of the medial canthal tendon have become more popular. Ipsilateral techniques are more advantageous because the dissection is restricted to the ipsilateral side (1). Among these, there have been many ways described by different authors. Callahan described a technique in which two vertical holes drilled along the posterior lacrimal crest and steel wire or strong nylon inserted. This technique was left because of surgical difficulty, nasal and periocular trauma and recurrent infection (6,7). Wilkins developed a procedure for medial canthal repair using a stainless steel bar (6). At the same time, Callahan repaired the medial canthal tendon with a stainless steel screw or piton placed in the naso-orbital region. But stainless steel pitons or screw were found to be useful in isolated canthal tendon avulsions, but not useful in complex naso-orbital fractures (6).

Complex naso-orbital fractures can be corrected with miniplates. Besides this advantage, placement of the plate on the stable bone of the frontal process of the maxilla allows the plate into correct anatomic position. This is not possible with piton fixation and difficult with transnasal wiring (6).

Titanium microplate fixation is a unilateral procedure, operating time is reduced, it can be removed or new holes can be drilled. It also allows for radiographic examination like computed tomography and magnetic resonance imaging (6). A disadvantage of this procedure is that it can't be performed through the small incision (7).

Recently developed Mitek Anchor system is an easy technique, eliminates the disadvantage of microplates. The disadvantages of this system are the necessity of an adequate bone stock and a normal positioned medial orbit. These anchors are difficult to remove and have increased risk of infection (7).

Our method is a simple way of repairing medial canthal tendon. It has some advantage and disadvantages compared with other techniques. It has all the advantages of unilateral repairing techniques. That is, it doesn't need a normal contralateral medial wall, it doesn't give harm to nasal, ocular and periocular structures, it is technically easy. Incision length in our method is small; as a result this, scarring is minimal and operating time is reduced. As we use miniscrew, risk of penetration into ethmoid sinus and infection is minimal.

But the disadvantage of our technique is its usage for isolated medial canthal tendon repair more than complex fractures. That is, a normal positioned medial orbital wall is needed.

These advantages and fewer disadvantages make our technique an easy, rapid and safer method for medial canthal tendon repair.

## REFERENCES

1. Antonyshyn OM, Weinberg MJ, Dagum AB, Eng B. Use of a new anchoring device for tendon reinsertion in medial canthopexy. *Plast Reconstr Surg* 1996; 98(3): 520-3.
2. Duvall AJ, Foster CA, Lyons DP, Letson RD. Medial canthoplasty: early and delayed repair. *The Laryngoscope* 1981; XCI (2): 173-83.
3. Whitaker LA, Yaremchuk MJ. Secondary reconstruction of posttraumatic orbital deformities. *Ann Plast Surg* 1990; 25: 440-9.
4. Ellis E. Sequencing treatment for naso-orbito-ethmoid fractures. *J Oral Maxillofac Surg* 1993; 51: 543-58.
5. Spinelli HM, Jelks GW. Periocular reconstruction: a systematic approach. *Plast Reconstr Surg* 1993; 91(6): 1017-24.
6. Howard GR, Nerad JA, Kersten RC. Medial canthoplasty with microplate fixation. *Arch Ophthalmol* 1992; 110: 1793-97.
7. Okazaki M, Akizuki T, Ohmori K. Medial canthoplasty with the Mitek Anchor System. *Ann Plast Surg* 1997; 38(2): 124-8.
8. Smith B, Beyer CK. Medial canthoplasty. *Arch Ophthalmol* 1969; 82: 344-8.
9. Karacaoğlan N, Şahin U, Ercan U, Bozdoğan N. One-stage repair of blepharophimosis: a new method. *Plast Reconstr Surg* 1994; 93: 1406-09.
10. Davis DG. Medial canthoplasty in a child with Waardenburg's syndrome. *Plast Reconstr Surg* 1969; 44(1): 81-5.
11. Freihofner HPM. Experience with transnasal canthopexy. *J Maxillofac Surg* 1980; 8: 119-24.
12. Nakajima T, Yoshimura Y, Onishi K, Sakakibara A. One-stage repair of blepharophimosis. *Plast Reconstr Surg* 1991; 87(1): 24-31.
13. Mustarde JC. Repair and reconstruction in the orbital region: a practical guide. New York: Churchill Livingstone Inc; 1996: 292-8.