

# Loss of Permanent Central Incisors in a 9 Year-Old Girl Due to Severe Periodontal Damage with an Unusual Etiology: Case Report

## 9 Yaşındaki Bir Çocukta Olağan Dışı Etiyoloji ile Gelişen Ciddi Periodontal Yıkıma Bağlı Daimi Santral Dişlerin Kaybı

Burcu KARADUMAN,<sup>a</sup>  
Ayşen BODUR<sup>b</sup>

<sup>a</sup>Department of Periodontology,  
İstanbul Aydın University  
Faculty of Dentistry, İstanbul,

<sup>b</sup>Department of Periodontology,  
Gazi University Faculty of Dentistry,  
Ankara

Geliş Tarihi/Received: 13.06.2012  
Kabul Tarihi/Accepted: 13.11.2012

*This case report was presented at 37<sup>th</sup> Turkish  
Periodontology Society Scientific Congress,  
23-27 May 2007, Antalya/Turkey*

Yazışma Adresi/Correspondence:  
Burcu KARADUMAN  
İstanbul Aydın University  
Faculty of Dentistry,  
Department of Periodontology, İstanbul,  
TÜRKİYE/TURKEY  
burcukaraduman@aydin.edu.tr

**ABSTRACT** Elastic bands have been widely used to create tooth movement during orthodontic treatment for many years. However, several reports regarding periodontal destruction due to the improper use of elastic bands have been reported in the dental literature. This case report presents the unusual case of severe localized periodontal destruction induced accidentally by an elastic band in a 9-year-old girl who was under antidepressant treatment. The patient had no previous history of any orthodontic treatment. She revealed that she had applied her brother's elastic band to her maxillary central incisors. Given the clinical and radiographic signs, both incisors required extraction. Prosthetic reconstruction was accomplished. Periodontal lesions caused by foreign bodies can be difficult to diagnose, since most plastic foreign bodies are not opaque on radiographs. Therefore dentists should be aware that the presence of a foreign body might be the potential cause of periodontal destruction progressed rapidly in healthy children.

**Key Words:** Orthodontic appliances; alveolar bone loss; foreign bodies; mood disorders; child

**ÖZET** Elastik bandlar diş hareketi yaratmak amacıyla yıllardır yaygın olarak kullanılmaktadır. Bununla birlikte, dental literatürde elastik bandların hatalı kullanımına bağlı oluşan periodontal yıkıma ilişkin birçok vaka bildirilmiştir. Bu vaka raporu, antidepresan ilaç kullanmakta olan 9 yaşındaki bir kız çocuğunda elastik bandın kazara kullanımına bağlı olarak gelişen ciddi lokalize periodontal yıkımı sunmaktadır. Herhangi bir ortodontik tedavi geçmişi olmayan hasta, erkek kardeşinin elastik bandını üst kesici dişlerine yerleştirdiğini ifade etmiştir. Klinik ve radyografik bulguların ışığında her iki maksiller kesici dişin çekimine karar verilmiştir. İyileşmeyi takiben protetik tedavi uygulanmıştır. Yabancı cisimlere bağlı olarak gelişen periodontal lezyonların teşhis edilmesi, özellikle plastik yabancı cisimler radyografılarda opak gözükmedikleri için zor olabilir. Bu yüzden diş hekimleri sağlıklı çocuklarda, yabancı cisim varlığının hızlı gelişen periodontal yıkımın nedenlerinden olabileceğini unutmamalıdır.

**Anahtar Kelimeler:** Ortodontik gereçler; alveolar kemik kaybı; yabancı cisimler; mizaç bozuklukları; çocuk

**Türkiye Klinikleri J Dental Sci 2015;21(2):184-8**

Elastic bands have been widely used in the orthodontic profession to create tooth movement during orthodontic treatment for many years. However, numerous cases of periodontal damage associated with the improper use of elastic bands have been reported in the dental literature.<sup>1-7</sup>

Acting as local irritants, elastic rubber bands placed around teeth tend to move apically along the root destroying both periodontal ligament and

alveolar bone, and hence producing localized periodontitis which consequently lead to luxation and even exfoliation of the involved teeth.<sup>1,2</sup> Various approaches to rehabilitation of the affected teeth have been described depending upon the extent of periodontal attachment loss such as surgical intervention, laser surgery and extraction.<sup>3,6</sup>

The presence of a foreign body might be the potential cause of periodontal destruction progressed rapidly in healthy children. This study reports the unusual case of severe localized periodontitis induced accidentally by elastic bands in a 9-year-old girl suffering from major depressive disorder with no previous history of any orthodontic treatment.

## CASE REPORT

A nine-year-old girl who had localized, rapidly progressive periodontal destruction at the maxillary central incisors was referred to our clinic by her dentist to evaluate the need for periodontal treatment. She had a non-contributory medical history. However, she was under antidepressant treatment with symptoms of a mood disorder. The patient was cooperative with little sign of concentration difficulty.

The gingiva of both maxillary central incisors had erythema and marked edema. Copious purulent bleeding on probing was evident and probing depths up to 10 mm were recorded. There was severe gingival recession of 2 to 5 mm on the labial aspect of both upper central incisors. The interdental papillae were markedly enlarged (Figure 1). Radiographic examination revealed advanced bone loss (Figure 2). The intra-oral examination revealed no acute trauma, deep caries or fractures. No other teeth were affected. The central incisors with grade III vertical mobility were deemed to have a hopeless prognosis. Given the clinical and radiographic signs, both extruded incisors required extraction.

All clinical procedures were fully explained to the parents, who signed an informed consent form, authorizing treatment and publication of the case.

Patient was referred for a complete medical evaluation to rule out any underlying systemic dis-

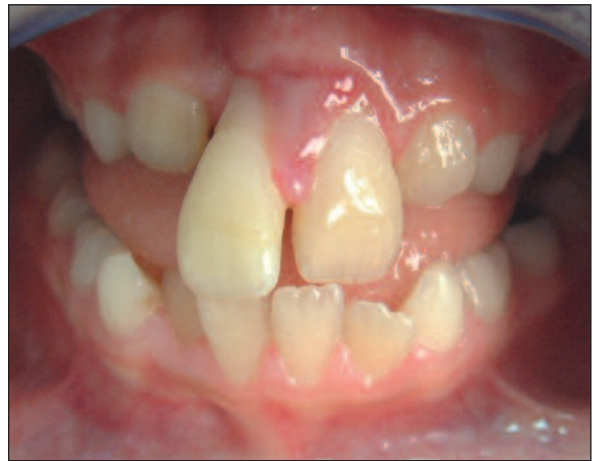

FIGURE 1: Initial intra-oral view of the patient.

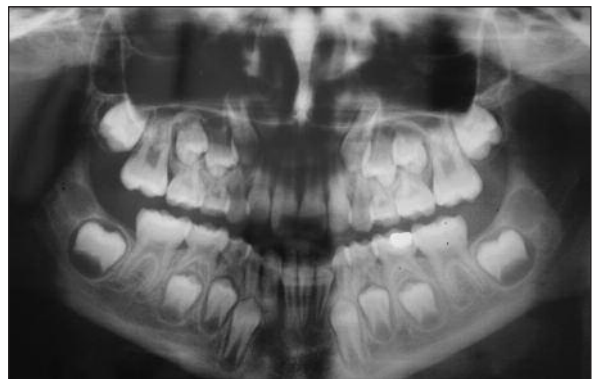

FIGURE 2: Panoramic radiography shows severe bone loss around maxillary incisors.

ease. The results of the medical evaluation, including the laboratory values, were within normal limits for the patient's age. After medical consultation of the patient the affected teeth were extracted. While extraction sites were curetted to remove any granulation tissue, an orthodontic rubber band was found in the extraction socket. Rubber band was removed and the extraction socket was irrigated with sterile saline solution (Figure 3). Following the healing period, prosthetic reconstruction was accomplished (Figure 4-6). A removable space maintainer was chosen for initial treatment as an esthetic and functional temporary management until the definitive treatment could be implemented. Insertion and removal of the retainer were taught to the child and home-care instructions

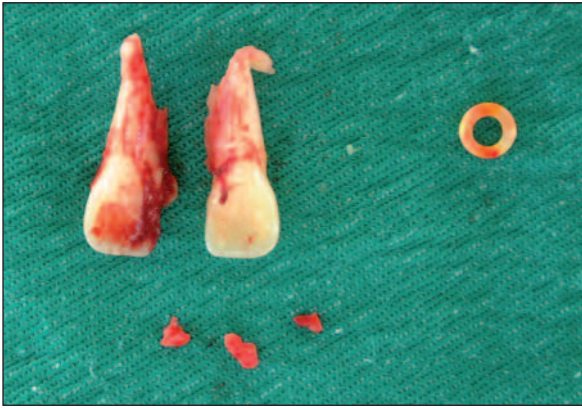


FIGURE 3: Extracted maxillary central incisors.

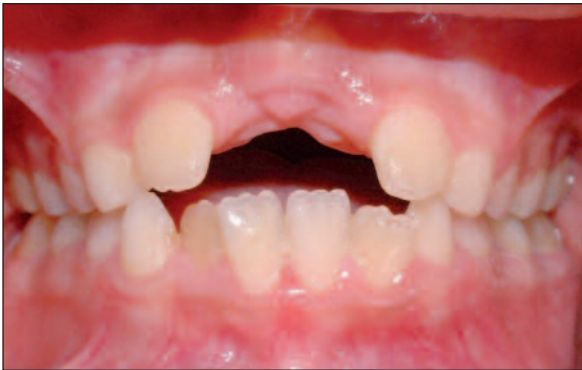

FIGURE 4: Post-treatment clinical view of the patient.

were given. Follow up evaluation was carried out in 6-months recall. Healing was uneventful.

Interestingly patient's history revealed no orthodontic treatment. Patient was asked about the elastic band and she admitted that she had mimicked the behavior of her brother, who was undergoing orthodontic treatment. Therefore, she applied an elastic band to her central incisors without the notice of her parents and kept it there for three weeks until it was found during the curettage.

## DISCUSSION

The correct initial diagnosis of patients presenting with unusual periodontal findings is difficult. The possible presence of foreign bodies should be considered in the differential diagnosis of similar-pre-

senting lesions. Practitioners should be aware of possible unusual etiologies which can be confirmed by a careful assessment of the patient's medical-dental history, clinical appearance of lesion and laboratory investigations. In this report, a case of severe localized bone loss with an unusual etiology is presented.

A number of cases regarding the severe localized bone loss induced by improper use of orthodontic elastic bands have been reported previously.<sup>1-7</sup> The apical movement of elastic bands leads to the progressive destruction of periodontal ligament and alveolar bone. Several reports emphasize that the direct application of elastic bands over the teeth without being stabilized by a proper orthodontic attachment is a completely undesirable technique for closing a midline diastema.<sup>2,5-7</sup> Most reported cases of periodontal tissue destruction re-

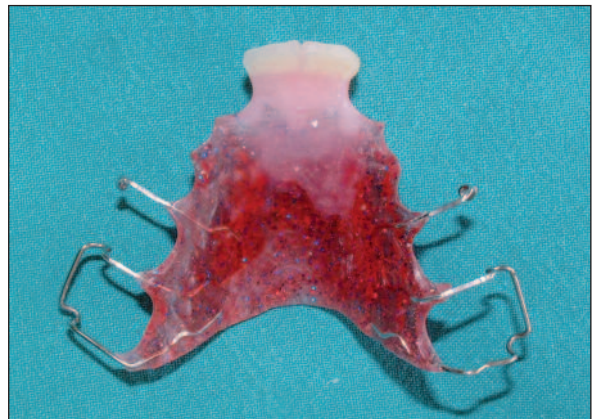

FIGURE 5: The removable partial denture.

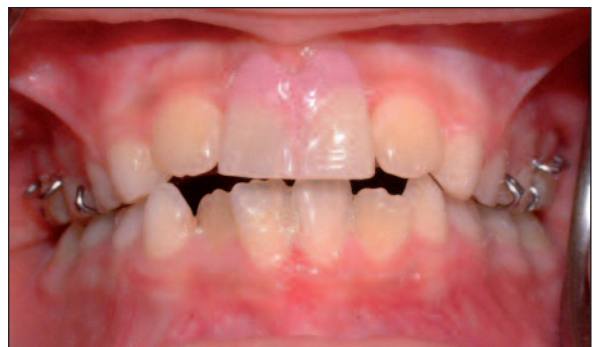

FIGURE 6: Intra-oral view of the patient after prosthetic reconstruction.

sulting from submerged elastic bands, however, occurs through mismanagement by dental clinicians. According to our knowledge, there are only two other cases, similar to our case, occurring in children with no history of orthodontic treatment, that have been documented in the literature.<sup>8,9</sup>

The induction of periodontal disease by ligature placement has been used in animal studies previously.<sup>10,11</sup> Caton and Zander reported the clinical and histological characteristics of experimental periodontal lesions using orthodontic elastics placed at the gingival margin in monkeys.<sup>12</sup> The presence of elastics in gingival and periodontal tissues provokes an immune-inflammatory response that leads to the progressive destruction of the structural components of the periodontium. This condition results in the clinical signs of periodontitis.<sup>13</sup> Elastics act also as a plaque formation-promoting factor, thus increasing the number of bacteria.<sup>14</sup>

The present case was very challenging to manage because of multiple factors contributing to delayed diagnosis of the patient, such as lack of local etiologic factors, poor history and inadequate information given by the patient, and also no prior history of orthodontic treatment. Although the etiology was unclear in this case; considering the clinical and radiographic signs, appropriate management involved extraction of the affected teeth. The diagnosis was established following a confession by the patient.

The most striking feature of our case was the presence of severe bone loss in a localized area with tooth mobility, without a prominent microbial dental plaque and calculus accumulation. The lesion was suspected to be the manifestation of localized aggressive periodontitis (LAP), which was later excluded as other findings of patient did not correspond to this diagnosis. Aggressive periodontitis (AP), previously known as juvenile periodontitis, is one of the rapidly progressive diseases characterized by gingival inflammation, periodontal pocket formation, rapid attachment loss and bone destruction.<sup>15</sup> The main characteristic of aggressive periodontitis is an extremely progressive form of tissue

destruction.<sup>15</sup> This highly destructive form of periodontitis often occurs in clinically healthy patients with little or no accumulation of plaque and/or calculus.<sup>15,16</sup> Aggressive periodontitis is also subcategorized into localized and generalized forms. The localized form of disease usually presents a circum-pubertal onset and characteristically involves first molars and incisors. LAP has interproximal attachment loss on at least two permanent teeth, one of which is a first molar, and involving no more than two teeth other than first molars and incisors.<sup>17</sup> The generalized form of aggressive periodontal disease usually, however, occurs mostly in young adults, although patients may be older. It is characterized by a generalized interproximal attachment loss affecting at least three permanent teeth other than first molars and incisors.<sup>17</sup> In the beginning, we considered aggressive periodontitis as a differential diagnosis, as the above-mentioned findings were present in our case. However, in the present case, progression of attachment loss occurred rapidly over a quite short period of time. Furthermore, the only teeth affected were central incisors and no other destruction in the periodontal tissues of patient was evident.

A general medical evaluation should be considered for children with severe periodontal destruction. Screening for systemic diseases was also required, because severe periodontal destruction in children can be an important warning sign of a significant systemic disease such as one of the hematologic disorders.<sup>18</sup> A hematology consultation was asked before teeth were extracted. The results of laboratory examinations, including hematology and biochemistry, were normal with no evidence of systemic contribution.

The differential diagnosis also included foreign body or trauma. However, in our patient, there was no prior history of orthodontic treatment or trauma. Furthermore, the patient presented in this study did not mention any possibility of any rubber band placement although this was consistent with her disease or her age. Authors have hypothesized that this kind of behavior may be used by some children as a means of gaining attention. Observation of her brother's behavior may have influenced

the patient. A younger child may try to mimic another sibling as a way of seeing attention if he sees those behaviors as more valued. It may also be associated with childhood curiosity. In addition, the role of underlying psychiatric illness should not be overlooked. According to Sandhu et al., gingival lesions may be the result of self-injurious behavior in many psychiatric disorders.<sup>19</sup> Self-inflicted dental injuries are common behavior patterns and range in severity from simple nail-biting to severe forms of mutilation or auto-extraction. In this patient, however, self injurious behavior doesn't seem to have arisen; attention-seeking behavior might have played a role.

In the present report, there were several factors that must have been considered, such as space maintenance, function, psychology, phonetics and esthetic appearance. A prosthetic rehabilitation in the form of a removable acrylic prosthesis was designed as a temporary solution until definitive treatment could be carried out in the future. In this case, this treatment option failed esthetically be-

cause of the lack of sufficient alveolar bone. Therefore, the future further treatments may include bone and/or soft tissue augmentation to improve bone volume and the soft tissue surrounding the extracted tooth. The long-term treatment of the patient may involve multiple care disciplines, i.e. a pediatric dentist, orthodontist, oral surgeon and prosthodontist. The dental team must carefully observe the patient's stage of dental development.

As a result, foreign bodies should be considered in the differential diagnosis when periodontitis seems refractory to treatment. Foreign bodies may easily be overlooked; therefore dental practitioners should have an awareness of diagnostic signs associated with foreign bodies. The early diagnosis of these cases can maintain the health and function of the permanent teeth.

### Acknowledgements

*The authors thank Dr. Nurdan Özmeriç Kurtuluş, Dr. Tunç Büyüktopçu and Dr. Zeynep Turgut for their valuable contributions.*

## REFERENCES

- Olsen CB, Pollard AW. [Severe bone loss caused by orthodontic rubber bands; management and nine-year follow-up: report of case]. ASDC J Dent Child 1998;65(1):25-8.
- Redlich M, Galun EA, Zilberman Y. [Orthodontic-prosthetic treatment to replace maxillary incisors exfoliated because of improper use of orthodontic elastics: a case report]. Quintessence Int 1997;28(4):241-4.
- Finkbeiner RL, Nelson LS, Killebrew J. [Accidental orthodontic elastic band-induced periodontitis: orthodontic and laser treatment]. J Am Dent Assoc 1997;128(11):1565-9.
- Warren K. [An unfortunate case of unsuccessful orthodontic treatment]. Br Dent J 1988; 25;164(12):394-5.
- Sánchez-Pérez A, Moya-Villaescusa MJ, Gambín-Manzano MC, Bravo-González LA. [Loss of a clinical attachment level in a child: differential diagnosis with aggressive periodontitis. Case report]. Br Dent J 2006;201(5):281-2.
- Haralabakis NB, Tsianou A, Nicolopoulos C. [Surgical intervention to prevent exfoliation of central incisors from elastic wear]. J Clin Orthod 2006;40(1):51-4.
- Lim KF. [Latex elastic-induced periodontal damage: a case report on the subsequent orthodontic management]. Quintessence Int 1996;27(10):685-90.
- Arvier J, Tideman H, Vickers P. [Foreign bodies and gingival lesions]. Aust Dent J 1987;32(4): 285-7.
- Marino VA, Fry HR, Behrents RG. [Severe localized destruction of the periodontium secondary to subgingival displacement of an elastic band. Report of a case]. J Periodontol 1988;59(7):472-7.
- Caton JG, Kowalski CJ. [Primate model for testing periodontal treatment procedures: II. Production of contralaterally similar lesions]. J Periodontol. 1976 Sep;47(9):506-10.
- Schroeder HE, Lindhe J. [Conversion of stable established gingivitis in the dog into destructive periodontitis]. Arch Oral Biol. 1975 Dec;20(12): 775-82.
- Caton JG, Zander HA. [Primate model for testing periodontal treatment procedures: I. Histologic investigation of localized periodontal pockets produced by orthodontic elastics]. J Periodontol. 1975 Feb;46(2):71-7.
- Schroeder HE, Lindhe J. [Conditions and pathological features of rapidly destructive, experimental periodontitis in dogs]. J Periodontol. 1980 Jan;51(1):6-19.
- Lindhe J, Ericsson I. [Effect of ligature placement and dental plaque on periodontal tissue breakdown in the dog]. J Periodontol. 1978 Jul;49(7):343-50.
- Armitage GC. [Development of a classification system for periodontal diseases and conditions]. Ann Periodontol 1999;4(1):1-6. Review.
- Arabacı T, Çiçek Y, Albayrak M, Keleş ON. [Ağresif periodontitisli bireylerde nükleer kappa B aktivasyonu immunohistokimyasal olarak incelenmesi: Stereolojik çalışma]. Atatürk Üniv Diş Hek Fak Derg 2010;20(2): 84-91.
- Lang NP, Bartold M, Cullinan M, Jeffcoat M, Mombelli A, Murakami S et al. [Consensus Report: Aggressive Periodontitis]. Ann Periodontol 1999;4(1):53.
- Zaromb A, Chamberlain D, Schoor R, Almas K, Blei F. [Periodontitis as a manifestation of chronic benign neutropenia]. J Periodontol 2006;77(11):1921-6.
- Sandhu HS, Sharma V, Sidhu GS. [Role of psychiatric disorders in self-inflicted periodontal injury: a case report]. J Periodontol. 1997;68(11): 1136-9.