

Penile Mondor's Disease Induced by Vigorous Sexual Activity: Two Cases, Two Different Approaches

Şiddetli Cinsel Aktivitenin Tetiklediği Penil Mondor Hastalığı: İki Olgu, İki Farklı Yaklaşım

Memduh AYDIN,^a
Tuncay TAŞ,^b
Gökhan GÜRSOY,^c
Orhun SİNANOĞLU,^d
Mustafa Bahadır Can BALCI,^a
Aydın İsmet HAZAR,^a
Barış NUHOĞLU^a

^aClinic of Urology,
Taksim Education and Research Hospital,
^bDepartment of Urology,
Maltepe University Faculty of Medicine,
İstanbul

^cClinic of Urology,
İslahiye State Hospital, Gaziantep
^dClinic of Urology,
Urgüp State Hospital, Nevşehir

Geliş Tarihi/Received: 22.03.2011
Kabul Tarihi/Accepted: 02.08.2011

Yazışma Adresi/Correspondence:
Tuncay TAŞ
İslahiye State Hospital,
Clinic of Urology, Gaziantep,
TÜRKİYE/TURKEY
drtastuncay@yahoo.com

ABSTRACT Penile Mondor's disease is a painless superficial induration due to thrombosis of penile superficial dorsal vein. Etiological factors for superficial dorsal penile vein thrombosis include trauma, vigorous sexual activity, pelvic tumors and a distended bladder. Doppler ultrasonographic evidence of thrombotic dorsal penile vein is diagnostic for penile Mondor's disease. Two cases with Mondor's disease of the penis due to brutal sexual intercourse are reported here. The first patient's thrombosis resolved spontaneously whereas in the second one anti-inflammatory and heparinoid agents were applied. The treatment should primarily be based on temporary sexual abstinence, and in case of no response treatment with non-steroid anti-inflammatory agents, local anticoagulants should be administered. Larger series are needed to determine whether initial observation is appropriate for all patients with penile Mondor's disease.

Key Words: Penile diseases; thrombosis

ÖZET Penil Mondor hastalığı, penis yüzeysel dorsal veninin trombozuna bağlı olarak oluşan ağrısız yüzeysel sertleşmedir. Penil yüzeysel dorsal ven trombozunun etiolojisinde travma, şiddetli cinsel aktivite, pelvik tümörler ve genişlemiş mesane bulunmaktadır. Tromboze dorsal venin Doppler ultrasonografiye ait bulgusu, penil Mondor hastalığı için tanısaldır. Çalışmamızda şiddetli cinsel aktiviteye bağlı iki penil Mondor hastalığı olgusu sunulmaktadır. İlk hastanın trombozu kendiliğinden düzelmişken, ikinci hastanın trombozu anti-inflamatuar ve heparinoid uygulamasıyla birlikte düzelmiştir. Tedavi esas olarak geçici olarak cinsel aktivitenin durdurulması, düzelme olmadığı takdirde non-steroid anti-inflamatuar ve lokal antikoagülanlar uygulanmasıdır. Penil Mondor hastalığı olan vakalarda ilk olarak yakın takibin uygun olup olmayacağı konusunda geniş vaka serilerine ihtiyaç vardır.

Anahtar Kelimeler: Penis hastalıkları; tromboz

Türkiye Klinikleri J Med Sci 2012;32(6):1746-9

Penile Mondor's disease is the phlebitis of penile superficial dorsal vein. Etiological factors for superficial dorsal penile vein thrombosis include trauma, vigorous sexual activity, pelvic tumors and a distended bladder.¹ In 1939, Henri Mondor first described the superficial vein thrombosis on the thoracic wall. The thoracoepigastric, lateral thoracic and superior epigastric veins are the most commonly involved vessels.² In 1955, superficial phlebitis of the penis was first reported by Braun-Falco.³ Since 1958, the definition includes the dorsal penile vein as well.^{3,4} The typical presentation is a painless induration on the dorsum of penis and/or painful erections. Herein we report two cases with penile Mondor's disease developed due to vigorous sexual activity.

CASE REPORTS

CASE 1

A 33-year-old man was referred to our clinic because of painful erections and a cord-like tender cutaneous lesion for over 8 days on the dorsum of his penis. Patient's history revealed traumatic vigorous sexual intercourse the day before the appearance of the lesion. He denied any hypercoagulable status, inflammatory process, infection or surgery. Physical examination of the genitourinary system revealed a dorsal cord-like swelling which was palpated superficially on the dorsum of penis and tender on palpation. Examination revealed no signs of lymphadenopathy in the groin region. Laboratory tests including urinalysis, complete blood cell count, erythrocyte sedimentation rate and protein C were yielded normal results. The patient underwent Doppler ultrasonography of the superficial dorsal vein which revealed thrombosis. The diagnosis was superficial dorsal vein thrombophlebitis and the treatment included organo-heparinoid gel, 500 mg oral naproxen (non-steroidal anti-inflammatory- twice a day), acetyl salicylic acid 325 mg (once a day) and oral cefuroxime axetil 250 mg (antibiotic -four times a day) for one week. Sexual activity was forbidden during treatment.

One week later at the follow-up visit there were no pain and sensitivity on palpation. The swelling due to dorsal vein phlebitis decreased. One month later, at the second visit, physical examination did not reveal any pathology. During the following year, no recurrence was observed.

CASE 2

A 46-year-old man was referred to our clinic because of an indurated cord over his penis. Patient's history included only a brutal sexual intercourse 12 hours before the appearance of the lesion. He denied any comorbidity. Physical examination revealed a healthy young man without any distress. There was no sign of lymphadenopathy in the groin region. A ropy cord was superficially palpated on the dorsum of penis (Figure 1)

This indurated cord could be followed superiorly and extended into the pubic hair region. The

cord was tender when palpated, and the overlying skin was completely intact with no erythema of the genitourinary system. Laboratory tests were normal. Doppler ultrasonographic examination confirmed obstruction of the superficial dorsal vein (Figure 2).

The definitive diagnosis was superficial dorsal vein thrombophlebitis. We preferred to observe the patient. The importance of abstinence from sexual intercourse for two weeks was reiterated. One month later, the swelling of dorsal vein phlebitis decreased (Figure 3). The lesion resolved within 6 months.

DISCUSSION

Penile Mondor's disease, also called as superficial thrombophlebitis of the dorsal vein of the penis, is a rare disorder that tends to affect males in the age range of 21-70 years. It presents with a cord-like induration of the vein, associated with mild dis-

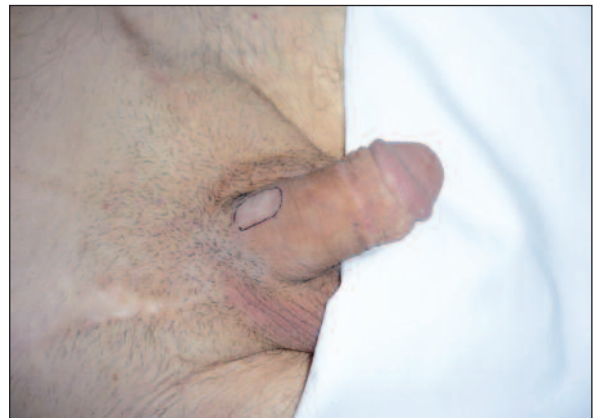

FIGURE 1: Penile Mondor's disease in a 46-year-old man. (See for colored form <http://tipbilimleri.turkiyeklinikleri.com/>)

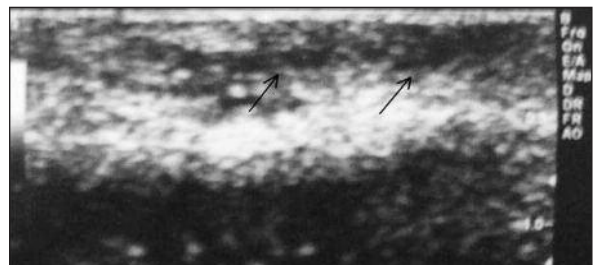


FIGURE 2: Doppler ultrasonographic examination of the superficial dorsal vein thrombosis.

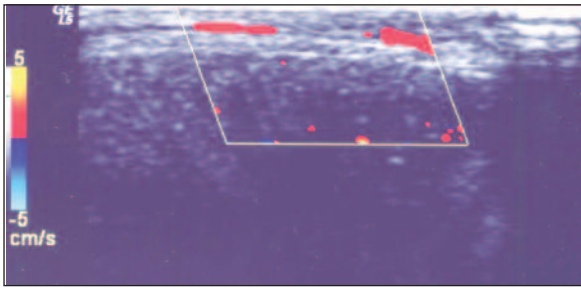


FIGURE 3: Normal blood flow is present after one month.
(See for colored form <http://tipbilimleri.turkiyeklinikleri.com/>)

comfort and inflammation. Most cases were reported to resolve completely, as did ours, with no permanent adverse effects on sexual function. Treatment with anti-inflammatory drugs has been reported to relieve symptoms but not to hasten resolution. The etiology of Mondor's disease is not certain. However, in literature it has been found to be associated with various factors such as considerable trauma, psychological stress, excessive physical activity, vigorous sexual activity, sexual disharmony, inflammatory process, infection, pelvic surgery and malignancy (tumoral mass) and prolonged abstinence from sexual intercourse and contact with menstrual blood which is possibly acting as an irritant.⁴ Superficial dorsal vein thrombophlebitis is easily diagnosed with history and physical examination.⁵ It is generally a benign and self-limited process. Acute, subacute and recanalization stages were described.⁵ The acute stage tends to manifest in 20 - 40 year-old males and typically appears within a 24-hour period following prolonged sexual activity, possibly secondary to vascular endothelial trauma. The histologic changes are limited to a subcutaneous vein showing thrombosis and organisation, in the healing stage, connective tissue proliferation occurs in the vessel, resulting in the formation of a hard cord.^{3,6} Thus the lesion was indistinguishable from the surrounding tissue, although it was palpable. Doppler ultrasonographic evidence of superficial dorsal vein thrombosis is diagnostic for penile Mondor's disease.⁷ Immunohis-

tochemical staining for CD31 and D240 was identified recently as the best method to distinguish small veins from lymphatic vessels; this method is used especially in the differential diagnosis of Mondor's disease to rule out other diseases in which veins or lymphatic vessels are affected.⁸ Although observation and sexual abstinence are sufficient for most cases as in our second patient, several authors recommend anticoagulants, antibiotics and anti-inflammatory agents, local heparinoid ointment in acute and subacute stages, respectively.^{1,4,9} Recanalization process was reported to last approximately 9 weeks. Antibiotic therapy should be administered when cellulitis is suspected and vein stripping may be necessary for severe, persistent cases of Mondor's disease.¹ In our first case, we administered oral and local anti-inflammatory agents as well as cephalosporins. For patients with severe acute pain, one should remember that injection of 0.5% bupivacaine hydrochloride subcutaneously to the region surrounding the affected vein provides relief. However care should be taken to avoid injecting the patients who have signs of infection, as this may exacerbate their condition. Surgical thrombectomy and superficial penile venous resection may also be the treatment options for more resistant cases. Until resolution of the symptoms, restriction of sexual activity and informing the patient are quite important.^{10,11} For detection of a possible relapse, measuring levels of protein S, free protein S, antithrombin III and protein C can be helpful.⁵

In conclusion, treatment of penile Mondor's disease is primarily based on observation or medical treatment with non-steroid anti-inflammatory agents and local anticoagulant ointments in addition to temporary sexual abstinence and as in our cases reported in this article. Larger series are needed to determine whether the initial observation would be appropriate for all patients with penile Mondor's disease. Thrombectomy and venous resection are very rarely indicated in unimproved and persistent cases.

REFERENCES

1. Swierzewski SJ 3rd, Denil J, Ohl DA. The management of penile Mondor's phlebitis: superficial dorsal penile vein thrombosis. *J Urol* 1993;150(1):77-8.
2. Mondor H. [Subacute subcutaneous endophlebitis of anterolateral thoracic wall]. *Mem Acad Chir* 1939;65:1271-8.
3. Braun-Falco O. [Clinical manifestations, histology and pathogenesis of the cordlike superficial phlebitis forms]. *Derm Wochenschr* 1955;132(27): 705-15.
4. Mayor M, Burón I, de Mora JC, Lázaro TE, Hernández-Cano N, Rubio FA, et al. Mondor's disease. *Int J Dermatol* 2000;39(12): 922-5.
5. Day S, Bingham JS. Mondor's disease of the penis following a long-haul flight. *Int J STD AIDS* 2005;16(7):510-1.
6. Al-Mwalad M, Loertzer H, Wicht A, Fornara P. Subcutaneous penile vein thrombosis (Penile Mondor's Disease): pathogenesis, diagnosis, and therapy. *Urology* 2006;67(3):586-8.
7. Ozkara H, Akkuş E, Alici B, Akpınar H, Hattat H. Superficial dorsal penile vein thrombosis (penile Mondor's disease). *Int Urol Nephrol* 1996;28(3):387-91.
8. Alvarez-Garrido H, Garrido-Ríos AA, Sanz-Muñoz C, Miranda-Romero A. Mondor's disease. *Clin Exp Dermatol* 2009;34(7):753-6.
9. Bejanga BI. Mondor's disease: analysis of 30 cases. *J R Coll Surg Edinb* 1992;37(5):322-4.
10. Zor M, Tahmaz L, Başal Ş, İrkılata HC, Dayanç M. [Penile Mondor's disease in a 32-year-old man: case report]. *Türkiye Klinikleri J Med Sci* 2009;29(6):1751-3.
11. Arıdoğan DA, Demir E, Doran S. [Superficial dorsal penile vein thrombosis: Mondor's disease of penis]. *Turkish Journal of Urology* 2004;30(1):120-1.