

# Cervical Necrotizing Fasciitis and Descending Mediastinitis Secondary to Mandibular Fracture: Case Report

## Mandibula Kırığı Sonrası Gelişen Servikal Nekrotizan Fasiit ve Desendan Mediastinit

Nilgün KANLIOĞLU KUMAN,<sup>a</sup>  
Gökhan ERPEK,<sup>b</sup>  
Salih ÇOKPINAR,<sup>a</sup>  
Ertan YAMAN,<sup>a</sup>  
Serdar ŞEN<sup>a</sup>

Departments of  
<sup>a</sup>Thoracic Surgery,  
<sup>b</sup>Otorhinolaryngology-Head and Neck Surgery,  
Adnan Menderes University  
Faculty of Medicine, Aydın

Geliş Tarihi/Received: 26.06.2012  
Kabul Tarihi/Accepted: 04.10.2012

*This case report was presented at 14<sup>th</sup> Annual Congress of Turkish Thoracic Society, 13-17 April 2011, Antalya*

Yazışma Adresi/Correspondence:  
Nilgün KANLIOĞLU KUMAN  
Adnan Menderes University  
Faculty of Medicine,  
Department of Thoracic Surgery, Aydın,  
TÜRKİYE/TURKEY  
nilkanlioglu@gmail.com

**ABSTRACT** Cervical necrotizing fasciitis and descending mediastinitis are aggressive infections with high morbidity and mortality. A 20-year-old man who was admitted to our clinic with painful neck movements and difficulty in swallowing, had tenderness on the neck and the skin of the neck was red and hot on physical examination. He had a chin trauma about 12 days ago in his medical history. A mandibular fracture can be seen on X-ray. Computed tomography scan of his neck and chest showed evidence of cervical necrotizing fasciitis, abscess formation and descending mediastinitis secondary to fracture. Case was treated with broad-spectrum antibiotics and urgent surgical drainage. Following surgical drainage the patient's condition quickly improved. Mandibular stabilization was performed under elective conditions and he was discharged on the 19<sup>th</sup> day of admission.

**Key Words:** Fasciitis, necrotizing; mandibular fractures; mediastinitis

**ÖZET** Servikal nekrotizan fasiit ve desendan mediastinit yüksek morbidite ve mortalite ile seyreden agresif enfeksiyonlardır. Yutmada güçlük ve boyun hareketlerinde ağrı ile kliniğimize başvuran 20 yaşındaki erkek olgunun fizik muayenesinde boyun bölgesinde hassasiyet, kızarıklık ve ısı artışı mevcuttu. Hikayesinde yaklaşık 12 gün önce çeneye alınan bir darbe olan olgunun düz grafilerinde mandibula kırığı, toraks ve boyun bilgisayarlı tomografisinde nekrotizan servikal fasiit ve desendan mediastinit bulguları tespit edildi. Olgu geniş spektrumlu antibiyotik ve acil cerrahi drenaj ile tedavi edildi ve cerrahi drenajı takiben klinik durum hızlı bir şekilde düzelme gösterdi. Olguya elektif şartlarda mandibula stabilizasyonu uygulandı ve başvurusundan 19 gün sonra taburcu edildi.

**Anahtar Kelimeler:** Fasiit, nekrotizan; mandibula kırıkları; mediastinit

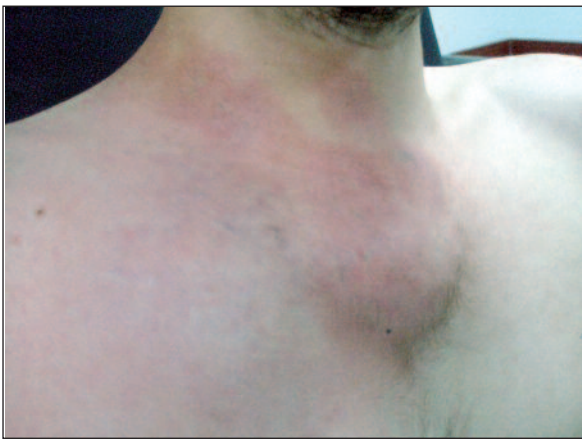**Türkiye Klinikleri Arch Lung 2013;14(1):14-6**

**D**eep neck infections (DNM) characterized by diffuse necrosis of fascial planes and subcutaneous tissues, may result with cervical necrotizing fasciitis and mediastinitis which are rare but vital progressive.<sup>1</sup> Cervical infections can advance in 12 hours to 2 weeks along the carotid sheath to anterior mediastinum and visceral compartment via pretracheal or retrovisceral spaces.<sup>2,3</sup> Preliminary symptom of mediastinitis may be neck abscess without other symptoms of mediastinal involvement.<sup>2,4</sup>

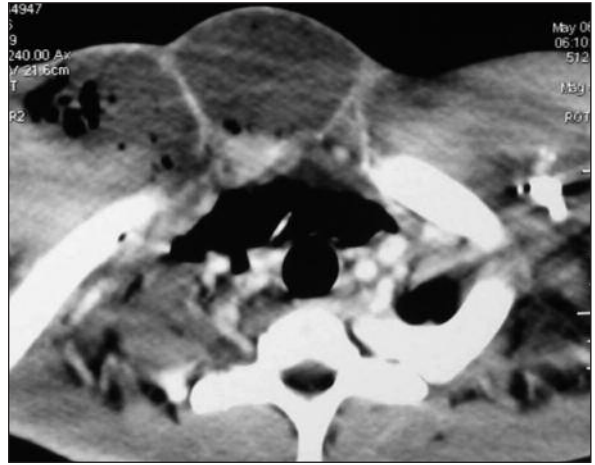
## CASE REPORT

20-year-old male patient was admitted with swallowing difficulty, swelling of the neck and drainage of pus from his mouth which started at third day after he was punched on his left jaw twelve days ago. Physical examination

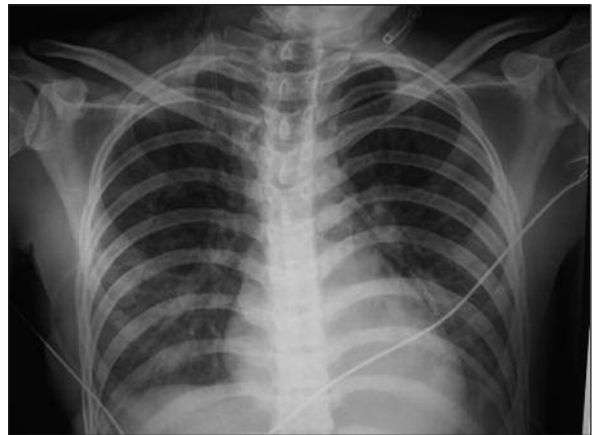revealed abscess formation extending from right upper neck to anterior chest wall of right hemithorax with color changes on skin. Fluctuating subcutaneous fluid was detected on right parasternal area below 3 cm of incisura jugularis (Figure 1). A right mandibular fracture and expansion of the neck was seen in x-ray. Chest computed tomography (CT) showed a consistent image with multilocular abscess formation with the largest diameter of 110x90 mm. Abscess contents were septations and air extending from right side of the neck at level of C3 vertebra to the upper mediastinum (Figure 2). In laboratory tests WBC was 23 400 and CRP was 295.56 mg/dL. Ampicillin/sulbactam 1.5 g 4x1 and metronidazole 500 mg 3x1 were given intravenously as antibiotic treatment. Approximately 1 liter foul-smelling abscess content was drained from the subcutaneous abscess during operation. Abscess had reached to pectoral muscle layer, to upper mediastinum, to the right side of the neck that extends to the back of the scalene muscles. At the same incision debridement of the mediastinum was performed. Three hemovac drains were placed into both sides of the neck and mediastinum (Figure 3) and multiple irrigations and aspirations were performed during postoperative days via drains. Fistulization and skin necrosis in areas of skin discoloration developed on postoperative second day (Figure 4). WBC was 8300 micron/L and CRP was 163 mg/dL on postoperative third day and CRP regressed to 13.47 mg/dL on 14<sup>th</sup> day. Drainage was



**FIGURE 1:** Abscess formation can be seen on anterior chest wall. (See for colored form <http://akcigerarsivi.turkiyeklinikleri.com/>)



**FIGURE 2:** Fluid and air collections were seen on anterior chest wall and pretracheal area in computed tomography.

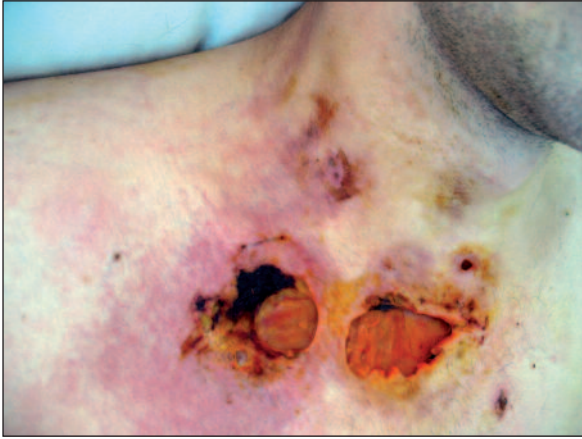

**FIGURE 3:** Three hemovac drains placed into the mediastinum and both sides of the neck can be seen on the postoperative chest X-ray.

terminated in fourth postoperative day. The general condition of the case got better. Control neck and chest CT findings were normal. All fluid collections and free air between fascias described in previous examination were gone and fat tissue of right side of the neck was thinner. Case was discharged on 19<sup>th</sup> day after elective surgery for mandibular fracture.

## DISCUSSION

Early diagnosis of mediastinitis is often difficult due to uncertainty of early symptoms of mediastinal involvement. The time between onset of symptoms and admission was reported to be about 6 days. Symptoms of the patients were neck pain, swelling,



**FIGURE 4:** Skin necrosis can be seen on anterior chest wall and neck after surgical drainage.

(See for colored form <http://akcigerarsivi.turkiyeklinikleri.com/>)

fever, dysphagia and dyspnea on admission in order of frequency.<sup>5</sup>

Diagnosis is made in operation or postmortem examination with the determination of connection between oropharynx and necrotizing mediastinal infection. Death may result from fulminant sepsis, erosion of blood vessels with exanguination, aspiration, and metastatic intracranial infection.<sup>4</sup> Our case presented with fistulization to tongue base and drainage of pus in mouth, neck pain, erythema and swelling on neck, fluctuation on neck and anterior chest wall following mandibular fracture. Abscess formation between the upper mediastinum and tissues of the neck extending toward the bottom of the upper mandible was observed in operation.

Causing agents of DNM were mixed aerobic and anaerobic organisms and they are the reason of

tissue necrosis and some of them produces gas.<sup>2,6</sup> There was no growth in culture in our case.

Estrera et al. reported that adequate drainage can be achieved by transthoracic approach when infection extends below the level of tracheal bifurcation of anterior mediastinum or below the level of T4 posteriorly.<sup>3</sup> In the treatment of mediastinitis accepted procedures are debridement, drainage and irrigation of mediastinal area by thoracotomy.<sup>7</sup> Cervical debridement and drainage can be added to the procedure if necessary. Sole thoracoscopic or percutaneous drainage was not enough because necrotic tissue debridement was required in most cases.<sup>8</sup> In our case upper mediastinum was reached through cervical incision and surgical exploration and debridement of all necrotic tissues, drainage and irrigation was applied properly in correlation with thoracic CT appearances. Inappropriate drainage of abscess or recurrent abscess formation was not observed on chest CT examination in postoperative follow-up period.

Acute pericarditis, esophagitis, tracheitis, tracheobronchitis, hemorrhage, thrombosis of large vessels and empyema may occur as complications of mediastinitis.<sup>9</sup>

Broad spectrum antibiotic therapy, early mediastinal debridement and drainage will be helpful to prevent extension of infection to lower levels of mediastinum. Neck and chest CT scans will help to determine the method of surgical drainage. Leukocyte and erythrocyte counts, sedimentation rate, infection parameters such as CRP and chest CT in follow-up period may give an idea of the adequacy of the surgical procedure.

## REFERENCES

1. Türüt H. [Acute necrotizing mediastinitis.] *Turkiye Klinikleri J Thor Surg-Special Topics* 2012;5(1): 245-9.
2. Nakamori Y, Fujimi S, Ogura H, Kuwagata Y, Tanaka H, Shimazu T, et al. Conventional open surgery versus percutaneous catheter drainage in the treatment of cervical necrotizing fasciitis and descending necrotizing mediastinitis. *AJR Am J Roentgenol* 2004;182(6):1443-9.
3. Estrera AS, Landay MJ, Grisham JM, Sinn DP, Platt MR. Descending necrotizing mediastinitis. *Surg Gynecol Obstet* 1983;157(6):542-52.
4. Liptay MJ, Fry WA, Shields TW. Acute and chronic mediastinal infections. In: Shields TW, Locicero J, Ponn RB, eds. *General Thoracic Surgery*. 5th ed. Philadelphia: Lippincott Williams and Wilkins; 2000. p.2093-104.
5. Ünsal Tuna EE, Özel E, Özbek C, Özdem O. [Deep neck infection: analysis of 63 cases]. *Turk Arch Otolaryngol* 2008;46(2):73-7.
6. Santos GH, Shapiro MB, Komisar A. Role of transoral irrigation in mediastinitis due to hypopharyngeal perforation. *Head Neck Surg* 1986;9(2):116-21.
7. Eren Ş, Avcı A, Şehitoğulları A, Eren C. [Descending necrotizing mediastinitis: case report]. *Klin Den Ar Derg* 2010;1(3):228-31.
8. Papalia E, Rena O, Oliaro A, Cavallo A, Giobbe R, Casadio C et al. Descending necrotizing mediastinitis: surgical management. *Eur J Cardiothorac Surg* 2001;20(4):739-42.
9. Metin M, Küçükyağcı M, Turna A, Sayar A, Alzafer S, Sayan MA. [Descending nekrotizing mediastinitis: as a complication of dental abscess]. *Turkish Thoracic Journal* 2004;5(2):124-6.