






Mirror Image Chorioretinal Colobomas in Identical Twins

Monozigot İkizlerde Ayna-Görüntüsü Koryoretinal Kolobom

-  Zeynep ACAR,^a
 Dilek GÜVEN,^b
 Mehmet DEMİR,^b
 Yekta ŞENDÜL,^b
 Burcu DİRİM^b

^aClinic of Ophthalmology, Haydarpaşa Numune Training and Research Hospital,
^bClinic of Ophthalmology, Şişli Hamidiye Etfal Training and Research Hospital, İstanbul

Received: 23.03.2016
 Received in revised form: 20.09.2016
 Accepted: 08.10.2016
 Available online: 22.02.2018

Correspondence:
 Zeynep ACAR
 Haydarpaşa Numune Training and Research Hospital,
 Clinic of Ophthalmology, İstanbul,
 TÜRKİYE/TURKEY
 zeynep_akyuz@hotmail.com

This case report was presented as a poster at TOD 49th Congress, 4-8 November 2015, İstanbul, Turkey.

ABSTRACT To describe two monozygotic twin sisters with unilateral chorioretinal coloboma (CRC) involving the optic disc was aimed. Monozygotic twin sisters with unilateral chorioretinal coloboma with healthy fellow eyes were diagnosed with Familial Mediterranean Fever (FMF), receiving colchicine therapy. Twin No1 was affected on the left eye and the Twin No 2 on the right eye. Optical coherence tomography showed that the foveal architecture was preserved in both patients. We report the first identical twins presenting with mirror image CRC.

Keywords: Twins, monozygotic; coloboma; optic disk; retina

ÖZET Monozigot ikiz kızkardeşlerde görülen tek taraflı optik diski kapsayan koryoretinal kolobom olgusunu sunmak amaçlandı. Optik diski de etkileyen tek taraflı koryoretinal kolobom ile başvuran monozigot ikiz kız çocuklarda herhangi bir ek patoloji mevcut değildi. Her ikisi de Ailevi Akdeniz Ateşi (AAA) nedeniyle kolşisin tedavisi almaktaydı. 1 numaralı ikizde sol göz etkilenmişken 2 numaralı ikizde sağ göz etkilenmişti. Optik koherens tomografik incelemede her iki çocukta foveal yapının korunduğu gösterildi. Literatürde monozigot ikizlerde bildirilen ilk ayna-hayali koryoretinal kolobom olgusunu sunuyoruz.

Anahtar Kelimeler: İkizler, tek yumurta; kolobom; optik disk; retina

In monozygotic twins, the splitting of the zygote occurs between the 8 and 16-cell stages of embryonic development. The mirror-image phenomenon (i.e. expression of features or anomalies on opposite sides) may occur in case of a possible delay in this process.¹ This phenomenon may result from genetic or environmental factors that occur before the split into two monozygotic embryos.² The mirror-image phenomenon is observed only in identical twins, and in approximately 25% of monozygotic twins.³ The mirror-image phenomenon rarely affects ophthalmic features.¹ To the best of our knowledge, there have been no reported cases of chorioretinal coloboma in monozygotic twins.

CASE REPORT

Five-year-old monozygotic twins were brought to our clinic with the complaint of abnormal appearing left eye with reduced vision in twin No1 and reduced vision in right eye of twin No 2. Their past medical history was

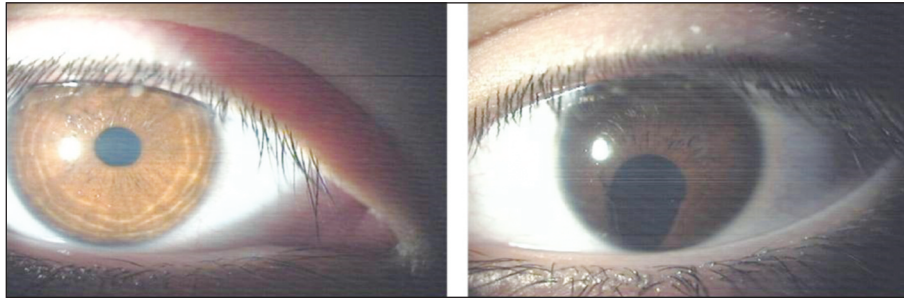


FIGURE 1: Biomicroscopic view of Case 1, iris coloboma on the left.

normal with term delivery and normal birth weight. Their motor and language development was normal for their age and they were recently diagnosed with Familial Mediterranean Fever (FMF) receiving long term colchicine therapy.

On ophthalmic examination of twin No1, the best-corrected visual acuity in his right eye was 1.0 with $-1.25\text{ D} \times 140^\circ$, and 0.6 with $+1.25\text{ D} +1.50\text{ D} \times 95^\circ$ in his left eye. The prism cover test demonstrated orthophoria. Slit-lamp examination was normal on the right and showed inferior iris coloboma on the left (Figure 1). Fundoscopy of the left eye showed a large inferior chorioretinal coloboma (CRC) involving the optic disc (Figure 2) and the right eye was normal. Optical coherence tomography (OCT) showed that the foveal architecture was preserved in both eyes.

On examination of twin No2, the best-corrected visual acuity on the right eye was 0.7 with $+3.00 -3.25\text{ D} \times 180^\circ$, and 1.0 with $-0.75\text{ D} \times 10^\circ$ on the left. The prism cover test demonstrated orthophoria. Slit-lamp examination was normal on both eyes (Figure 3). Fundoscopy of the right eye showed an inferior CRC involving the optic disc

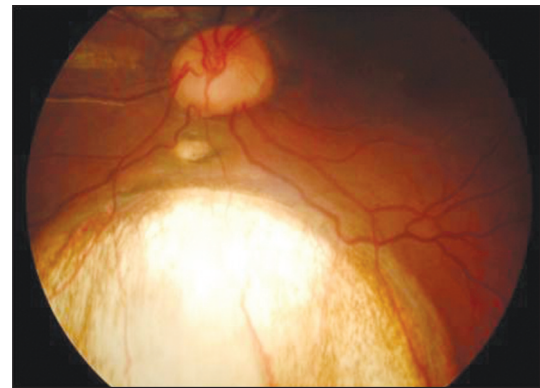


FIGURE 2: Fundus view of Case 1, large chorioretinal coloboma on the left.

(Figure 4) and the left eye was normal. OCT showed that the foveal architecture was preserved in both eyes.

They were put on occlusion therapy on the sound eyes and have been checked periodically for the change in visual acuity and any sign of risk of retinal detachment on the border of the colobomas. At the end of the five year follow up, visual acuity in twin No1 was 0.7 on the left and fundoscopic findings remained stable. In twin No2 visual acuity

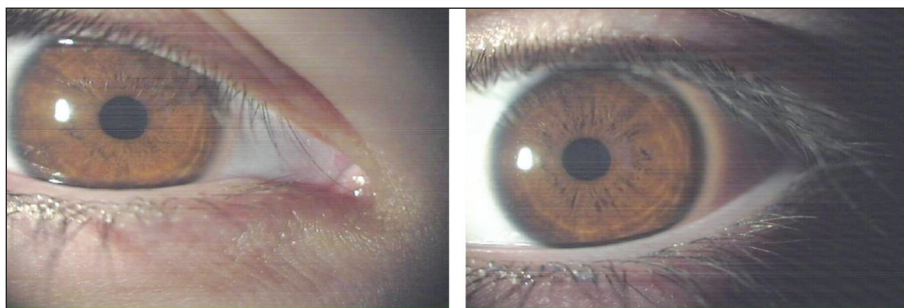


FIGURE 3: Normal biomicroscopic view of Case 2.

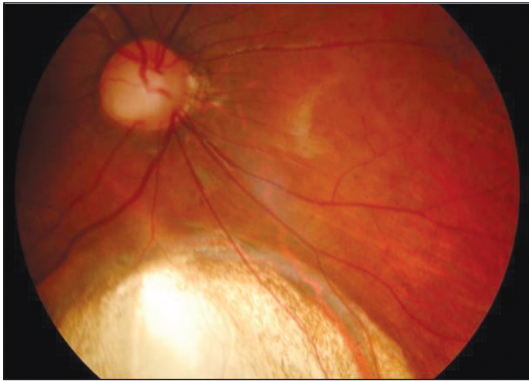


FIGURE 4: Fundus view of Case 2, right chorioretinal coloboma.

on the right eye reached as high as 0.8 and fundoscopic findings remained also stable.

DISCUSSION

Ocular coloboma as an isolated anomaly is commonly inherited in an autosomal dominant manner with variable expressivity and incomplete penetrance.⁴ It can also be a part of a single gene disorder with multisystem involvement, owing to chromosomal abnormalities, or a part of multisystem disorders of unknown etiology. The severity of coloboma is based on the involvement of disc and/or macula and also on any associated microphthalmia. Both of our cases had involvement of the optic disc but healthy macular structure and amblyopia treatment gave satisfactory results.

Recent reports described cases of mirror image myopic anisometropia in a brother and sister

pair and mirror image exotropia and abnormal head position with nystagmus in two identical twin pairs.^{5,6} A pair of monozygotic twins diagnosed with LEOPARD syndrome and bilateral chorioretinal coloboma has also been reported but we believe that our case is the first report of mirror image chorioretinal coloboma in otherwise healthy identical twins.⁷

Source of Finance

During this study, no financial or spiritual support was received neither from any pharmaceutical company that has a direct connection with the research subject, nor from a company that provides or produces medical instruments and materials which may negatively affect the evaluation process of this study.

Conflict of Interest

No conflicts of interest between the authors and / or family members of the scientific and medical committee members or members of the potential conflicts of interest, counseling, expertise, working conditions, share holding and similar situations in any firm.

Authorship Contributions

Idea/Concept: Dilek Güven, Zeynep Acar; **Design:** Zeynep Acar, Mehmet Demir; **Control/Supervision:** Dilek Güven; **Data Collection and/or Processing:** Burcu Dirim, Zeynep Acar, Yekta Şendül; **Analysis and/or Interpretation:** Zeynep Acar, Mehmet Demir; **Literature Review:** Zeynep Acar, Burcu Dirim, Yekta Şendül; **Writing the Article:** Zeynep Acar; **Critical Review:** Dilek Güven, Mehmet Demir; **References and Findings:** Zeynep Acar, Dilek Güven; **Materials:** Yekta Şendül.

REFERENCES

1. Dirani M, Chamberlain M, Garoufalos P, Chen CY, Guymer RH, Baird PN. Mirror-image congenital esotropia in monozygotic twins. *J Pediatr Ophthalmol Strabismus* 2006;43(3):170-1.
2. Akin C, Allart JF, Rouland JF. [Unilateral keratoconus and mirror image in a pair of monozygotic twins]. *J Fr Ophtalmol* 2007; 30(9):899-902.
3. Gedda L, Brenci G, Franceschetti A, Talone C, Ziparo R. Study of mirror imaging in twins. *Prog Clin Biol Res* 1981;69A:167-8.
4. Onwochei BC, Simon JW, Bateman JB, Couture KC, Mir E. Ocular colobomata. *Surv Ophthalmol* 2000;45(3):175-94.
5. Park SJ, Kim JY, Baek SH, Kim ES, Kim US. One sister and brother with mirror image myopic anisometropia. *Korean J Ophthalmol* 2010;24(1):62-4.
6. Kim WK, Chung SA, Lee JB. Two cases of mirror-image eye anomalies in monozygotic twins. *Korean J Ophthalmol* 2010;24(5):314-7.
7. Rudolph G, Haritoglou C, Kalpadakis P, Boergen KP, Meitinger T. [LEOPARD syndrome with iris-retina-choroid coloboma. Discordant findings in monozygotic twins (MIM # 151100)]. *Ophthalmologe* 2001;98(11):1101-3.