

Sclerosing Epithelioid Fibrosarcoma of the Paratesticular Region: From Non-specific Clinical and Pathological Features to Diagnosis: Case Report

Paratestiküler Bölgenin Skleroze Epiteloid Fibrosarkomu: Nonspesifik Klinik ve Patolojik Bulgulardan Tanıya

Emrah KUMCU,^a
Hatice ÜNVERDİ,^b
Onur ORAL,^c
Duygu TÜRKBEY^d

Clinics of Pathology,
^aBingöl State Hospital,
Bingöl

^bGaziantep Ersin Arslan State Hospital,
Gaziantep

^cViranşehir State Hospital,
Şanlıurfa

^dDepartment of Pathology,
Başkent University Faculty of Medicine,
Ankara

Geliş Tarihi/Received: 28.02.2017

Kabul Tarihi/Accepted: 26.07.2017

Yazışma Adresi/Correspondence:

Emrah KUMCU
Bingöl State Hospital,
Clinic of Pathology, Bingöl,
TURKEY/TÜRKİYE
emrahkumcu85@hotmail.com

ABSTRACT Sclerosing epithelioid fibrosarcoma (SEF) is a rare fibroblastic neoplasm, can be confused with benign soft tissue tumors histologically. SEF can be seen any age and affect both gender equally. It often localized in deep soft tissues of both extremities, trunk and head and neck area. We present a case, which a 85 year old man with a mass in inguinal region, thought as an incarcerated inguinal hernia. In biopsy specimen there was quite hypocellular areas and singly arranged atypical cells in sclerotic and collagenous stroma which was confused with benign tumors and reactive process. Some of tumor cells had epithelioid appearance and showed atypia. With the histomorphology and ancillary studies we give the diagnosis of SEF. SEF is a rare soft tissue tumor, which needs to be differentiated from a wide variety of benign or malignant tumors because of its non-specific clinical and pathological properties.

Keywords: Soft tissue neoplasms; fibrosarcoma; immunohistochemistry

ÖZET Skleroze epiteloid fibrosarkom (SEF) histolojik olarak benign yumuşak doku tümörleri ile karışabilen nadir bir fibroblastik neoplazidir. SEF her yaşta ve her iki cinsiyette eşit oranda görülür. SEF'ler genellikle her iki ekstremitede, gövdede ve baş-boyun bölgesinde, derin yerleşimli olarak izlenirler. Bu yazıda, inkarsere herni olarak düşünülen inguinal kitle ile gelen 85 yaşında erkek hasta takdim edilmektedir. Biyopsi spesmeninde benign tümörler ve reaktif süreçler ile karışabilecek sklerotik ve kollajenöz stromaya sahip hiposellüler lezyon izlenmiştir. Tek tek dizgilenen tümör hücrelerinin bir kısmında epiteloid görünüm ve atipi dikkati çekmiştir. Histomorfoloji ve yardımcı tekniklerle vakaya SEF tanısı verilmiştir. SEF non-spesifik klinik ve patolojik özelliklere sahip nadir bir yumuşak doku tümürüdür ve bu sebeple çok sayıda benign ve malign tümörle ayırıcı tanıya girilmektedir.

Anahtar Kelimeler: Yumuşak doku neoplazileri; fibrosarkom; immünohistokimya

Sclerosing epithelioid fibrosarcoma (SEF) is a rare fibroblastic neoplasm, can be confused with benign soft tissue tumors histologically. SEF is first described by Meis-Kindblom in 1995.¹ SEF can be seen any age and affect both gender equally. It often localized in deep soft tissues of both extremities, limb girdles, trunk and the head and neck area.¹ It has a relatively low-grade appearance in hematoxyline-eosine (H&E) sections, however local recurrence and distant metastases have been reported and it is not rare the death from tumor.^{2,3} Because of the rarity and the potential for

misdiagnosis for another neoplasms, we present a case of SEF with literature knowledge.

CASE REPORT

A 85 year old man applied to our emergency service with a painful, slowly growing mass in inguinal region. Ultrasonographic imaging showed that there was an irregular mass, probable herniated intestinal segments, across through from inguinal channel to left scrotum. With these symptoms and imaging inputs, the case had been firstly thought as an incarcerated inguinal hernia. Afterwards, computed tomography imaging demonstrated a 13x8x5 cm large, ill-defined mass arising symphysis pubis and involving the scrotal region via inguinal channel. Biopsy and resection was performed. In biopsy specimen there were quite hypocellular areas and singly arranged atypical cells in sclerotic and collagenous stroma which was confused with benign tumors and reactive process (Figure 1). In resection material, the tumor cells were small to medium size and had round, spindle and polygonal shape. Their cytoplasm was clear and pale eosinophilic.

The cells were arranged in cords, strands and surrounded by a dense collagenous stroma with areas of hyalinization (Figure 2). Some of tumor cells have epithelioid appearance and showed atypia and pleomorphism in focal areas of the tumor (Figure 3). Mitotic figures were infrequent

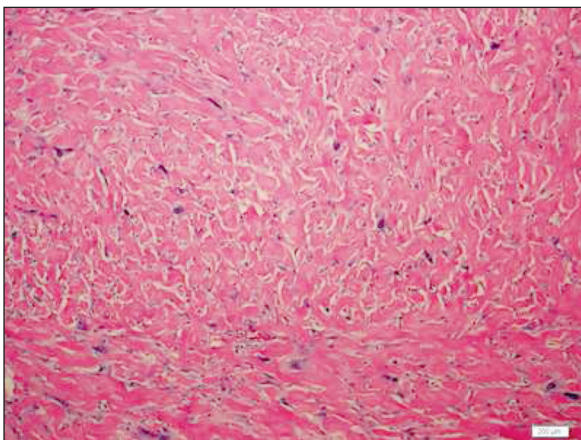


FIGURE 1: Hypocellular areas with dense sclerotic stroma (H&E x200).

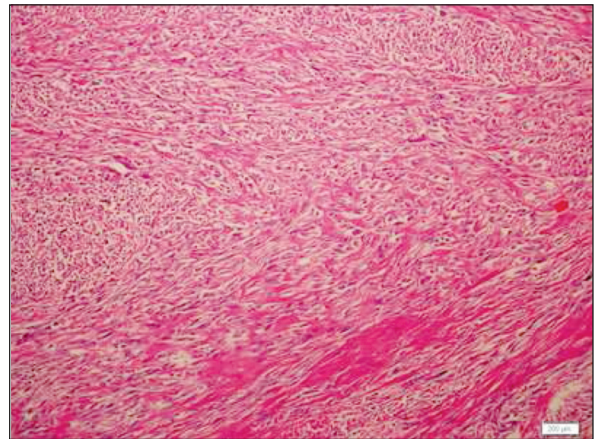


FIGURE 2: More cellular, mild pleomorphic tumor cells (H&E x100).

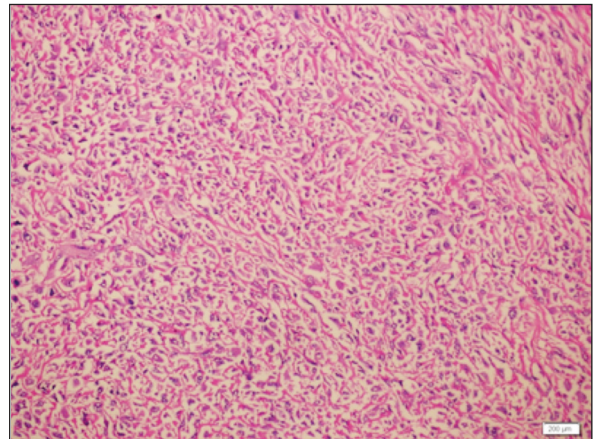


FIGURE 3: Epithelioid areas (H&E x200).

and necrosis was seen focally. We thought the diagnosis of metastatic carcinoma morphologically and sclerosing rhabdomyosarcoma and sclerosing liposarcoma as primary tumor in that location in differential diagnosis. Immunohistochemically, the tumor cells showed strong and diffuse positive staining for vimentin (Figure 4). PanCK, EMA, Beta Katenin, S-100, CD34. After the exclusion of the lesions in differential diagnosis and re-evaluation of the morphological and immunohistochemical properties of the lesion, we concluded the diagnosis of SEF.

DISCUSSION

SEF, is an unusual but distinctive variant of malignant fibroblastic tumors, often localized in deep

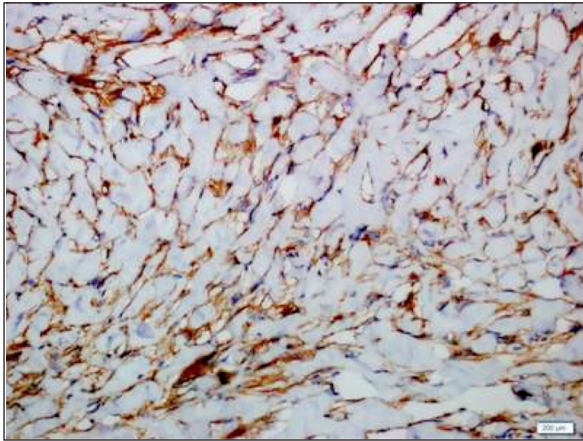


FIGURE 4: Strong and diffuse vimentin positivity (IHC X200).

soft tissues of both extremities, limb girdles, trunk and the head and neck area. The other reported localizations are oral cavity, cecum, pubic bone, lung, sacrum and pituitary gland. SEF also rarely can be localized inguinal region and behaved like inguinal hernia clinically due to the extension of tumor through inguinal channel like our case. SEF occurs primarily in middle aged and elderly patients. There is no clear difference in incidence between males and females. SEF is firstly described as a rare distinct fibrosarcoma variant that mimics infiltrating carcinoma because of epithelioid morphology.¹ According to recent World Health Organization (WHO) classification of soft tissue neoplasms, this neoplasm characterized by epithelioid tumor cells embedded within a sclerotic collagenous matrix and arranged in nests and cords.⁴ Also, some authors believe that a subset of SEF is related to low grade fibromyxoid sarcoma (LGFMS) morphologically, immunohistochemically and genetically because of SEF and LGFMS togetherness. In our case there were no myxoid areas like LGFMS, so we think that our case is not so-called hybrid form

SEF, it is a pure form of SEF morphologically. Hypocellular areas, mild pleomorphism and sclerotic hyaline matrix of SEF suggest a benign clinical behavior and cell morphology allows for the wide differential diagnosis of benign, pseudosarcomatous and malignant lesions. However, long term survival rate of first described case series and recurrence, metastasis and mortality rate of the other case series shows us SEF is not quite as innocent as its morphologic features.¹⁻³ Lack of prominent pleomorphism and infiltrative growth pattern, focal or no necrosis, low mitotic rate and absence of any positive immunohistochemical stain other than vimentin is helpful features for differential diagnosis of SEF. SEF is found to be highly positive for MUC4 in recent studies.⁵ A new osteogenic marker, SATB2 is found to be useful in differential diagnosis. In contrast to osteosarcoma, SEF with bone metastasis show no expression of SATB2.⁶ It should also kept in mind that in case series, some SEFs rarely shows variable PanCK and EMA positivity, so Eyden et al. propose that the diagnosis of SEF should be based on distinct morphologic features with consistent vimentin staining. In summary, despite the relatively bland appearance and low mitotic activity, this rare variant of fibrosarcoma is capable of local recurrence and distant metastasis.^{1,7} SEF needs to be differentiated from a variety of benign or malignant tumors exhibiting epithelioid features and sclerotic stromal response by defining distinct morphologic criteria and using the advantage of ancillary studies.

Conflict of Interest

Authors declared no conflict of interest or financial support.

Authorship Contributions

All authors contributed equally to this study.

REFERENCES

1. Meis-Kindblom JM, Kindblom LG, Enzinger FM. Sclerosing epithelioid fibrosarcoma: a variant of fibrosarcoma simulating a carcinoma. *Am J Surg Pathol* 1995;19(9):979-93.
2. Antonescu CR, Rosenblum MK, Pereira P, Nascimento AG, Woodruff JM. Sclerosing epithelioid fibrosarcoma: a study of 16 cases and confirmation of a clinicopathologically distinct tumor. *Am J Surg Pathol* 2001;25(6):699-709.
3. Hu WW, Lai RQ, Wang J, Feng XD, Li GM. [Sclerosing epithelioid fibrosarcoma: a clinicopathologic study of eight cases]. *Zhonghua Bing Li Xue Za Zhi* 2004;33(4):337-41.
4. Kindblom LG, Mertens F, Coindre JM, Hornick JL, Meis JM. Sclerosing epithelioid fibrosarcoma. In: Fletcher CDM, Bridge JA, Hogendoorn PCW, Mertens F, eds. *World Health Organization Classification of Tumours of Soft Tissue and Bone*. 4th ed. Lyon: IARC Press; 2013. p.97-8.
5. Doyle LA, Wang WL, Dal Cin P, Lopez-Terrada D, Mertens F, Lazar AJ, et al. MUC4 is a sensitive and extremely useful marker for sclerosing epithelioid fibrosarcoma: association with FUS gene rearrangement. *Am J Surg Pathol* 2012;36(10):1444-51.
6. Righi A, Gambarotti M, Manfrini M, Benini S, Gamberi G, Cocchi S, et al. Sclerosing epithelioid fibrosarcoma of the thigh: report of two cases with synchronous bone metastases. *Virchows Arch* 2015;467(3):339-44.
7. Eyden BP, Manson C, Banerjee SS, Roberts IS, Harris M. Sclerosing epithelioid fibrosarcoma: a study of five cases emphasizing diagnostic criteria. *Histopathology* 1998;33(4):354-60.