

## CASE REPORT

DOI: 10.5336/caserep.2019-70978

## Bilateral Optic Neuropathy in a Patient with Imatinib Usage

Raziye DÖNMEZ GÜN<sup>a</sup>, Alev KOÇKAR<sup>b</sup>, Burcu ALTUNRENDE<sup>c</sup>, Elvan ALPER ŞENGÜL<sup>c</sup>

<sup>a</sup>Kartal Dr. Lütfi Kırdar Training and Research Hospital, Department of Ophthalmology, İstanbul, TURKEY

<sup>b</sup>İstanbul Ümraniye Training and Research Hospital, Department of Ophthalmology, İstanbul, TURKEY

<sup>c</sup>İstanbul Bilim University Faculty of Medicine, Department of Neurology, İstanbul, TURKEY

This study was presented as a poster at 52<sup>nd</sup> Turkey Ophthalmology Association National Congress, 13-18 November 2018, Antalya, Turkey.

**ABSTRACT** A 59-year-old woman presented with a painless vision loss in her left eye for five days. The nasal side of the right optic nerve head was mildly oedematous and hyperaemic, and the left optic nerve head was oedematous and hyperaemic. She was diagnosed as bilateral optic neuropathy. Imatinib was stopped, intravenous methylprednisolone was given for a week. The vision and fundus findings recovered in a few days. After 2 months imatinib was restarted, there was no ocular side effects until now. Imatinib is an important drug in the treatment of chronic myeloid leukemia, but bilateral optic neuropathy, which is a serious ocular side effect, may be seen related to imatinib mesylate usage.

**Keywords:** Optic neuropathy; imatinib mesylate; chronic myeloid leukemia; side effect

Imatinib mesylate is a drug which is indicated for the treatment of chronic myeloid leukemia (CML) and inhibits BCR-ABL kinase.<sup>1</sup> However, this drug is associated with a number of known ocular side effects.<sup>2</sup> Periorbital edema and epiphora are the most frequent side effects that may be seen related to imatinib usage.<sup>3</sup> Sight-threatening side effects that affect the optic nerve, macula, and retina are uncommon but do occur.<sup>3</sup>

Herein, we describe a patient with CML who developed bilateral optic neuropathy (BON) during treatment with imatinib mesylate.

### CASE REPORT

The patient signed an informed consent granting the use of data for scientific purposes. There is no conflicts of interest. A 59-year-old woman presented with painless vision loss in her left eye for 5 days. She did not report any other symptoms such as headache, nau-

sea, or vomiting. She reported that she had been diagnosed with CML in April 2013 and has been taking imatinib mesylate (400 mg/day) for the past 2 years. She had complete remission with imatinib. She had not been taking any concomitant drug therapy and did not report any other comorbidity. Her visual acuity was 20/20 in the right eye and 20/400 in the left eye. In the left eye, relative afferent pupillary defect was positive. Colour vision of the right eye was normal at 7/11, and colour vision of the left eye was 1/11. Anterior segment evaluation was bilateral normal. Intraocular pressure was 13 mmHg for the right eye and 15 mmHg for the left eye. On fundoscopic examination, the nasal side of the right optic nerve head was mildly oedematous and hyperaemic, and the left optic nerve head was oedematous and hyperaemic (Figure 1A,B). Blood tests and chest x-ray were normal. In cerebral magnetic resonance imaging there was no evidence of leukemic infiltration in the central nervous

**Correspondence:** Raziye DÖNMEZ GÜN

Kartal Dr. Lütfi Kırdar Training and Research Hospital, Department of Ophthalmology, İstanbul, TURKEY

**E-mail:** rdmstf84@gmail.com



Peer review under responsibility of Türkiye Klinikleri Journal of Case Reports.

**Received:** 02 Sep 2019

**Received in revised form:** 31 Oct 2019

**Accepted:** 20 Nov 2019

**Available online:** 28 Nov 2019

2147-9291 / Copyright © 2020 by Türkiye Klinikleri. This is an open access article under the CC BY-NC-ND license (<http://creativecommons.org/licenses/by-nc-nd/4.0/>).

system. The cerebral venous structures were normal in contrast-enhanced magnetic resonance imaging and demyelination was not detected. In orbital magnetic resonance imaging, there was contrast uptake in a contrast-enhanced T1 sequence at the intraocular segment of the left optic nerve. Neurological examination was unremarkable other than the findings in the left eye. Workup for other etiological agents; history of drug intake, viral markers, autoantibodies for vasculitis, paraneoplastic autoantibody, neuromyelitis optica-IgG, and myelin oligodendrocyte glycoprotein antibody was negative.

Lumbar puncture was normal. Visual evoked potential test (VEP) showed prolongation of P100 latency (144 ms) and amplitude reduction in the left eye. In retinal nerve fiber layer (RNFL) evaluation, average RNFL thickness was 106.97  $\mu\text{m}$  and 159.45  $\mu\text{m}$  in the right eye and left eye respectively (Figure 2). With the help of these findings, we diagnosed our patient as having BON.

On the seventh day of the patient's complaints, imatinib was stopped and intravenous methylprednisolone therapy (1000 mg/day) was started for 7 days. On the third day of therapy, her vision was 20/20 in both eyes. On fundoscopic examination, both optic discs were normal on the fifth day. During follow up, we examined that both optic discs were mildly pale (Figure 3A,B). Average RNFL thickness was 89.67  $\mu\text{m}$  in the right eye and 82.43  $\mu\text{m}$  in the left eye at 3 months after initial (Figure 4). The patient restarted imatinib treatment after 2 months. No ocular side effects have been noted so far.

## DISCUSSION

Mild side effects may occur frequently with the usage of imatinib and it's a well tolerated drug.<sup>1</sup> But in the present study, we describe a case of BON, a more serious side effect that may be related to imatinib usage.

Most complications of imatinib are related to fluid retention in the connective tissue and extracellular matrix, and associated with inhibition of the platelet-derived growth factor receptor.<sup>4</sup> In our case fluid retention may be the possible mechanism of optic disc oedema.

According to the literature, adverse effects such as retinal oedema and optic disc oedema usually occur in the initial phases of imatinib therapy.<sup>4-6</sup> More serious ocular side effects usually occur 1-3 months after starting imatinib.<sup>4,5,7</sup> However, Napolitano et al. diagnosed a patient who was taking imatinib for 9 years with retinal oedema.<sup>8</sup> In their case, retinal oedema promptly resolved after drug suspension without any specific treatment. In our case, we diagnosed a patient with BON after using imatinib for 2 years. This is a late onset compared with most related studies but similar to Napolitano et al.'s case.<sup>8</sup> Our patient's findings improved by stopping imatinib and starting treatment with methylprednisolone.

Kwon et al. reported a case about bilateral optic disc oedema associated with imatinib usage, they showed slight prolongation of P100 latency in their patient's VEP test. Similar to Kwon et al.'s case, our patient's VEP test showed prolongation of P100 latency and amplitude reduction in the left eye.<sup>4</sup> In our

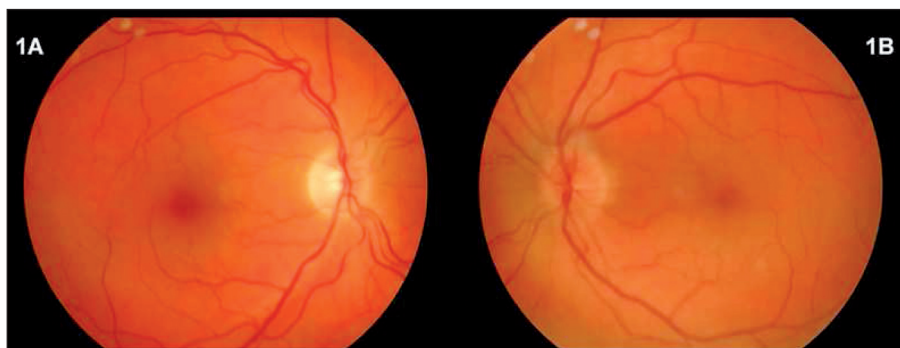

FIGURE 1: A-B: Nasal side of right optic nerve head is mildly oedematous and hyperemic (A), left optic nerve head is oedematous and hyperemic (B).

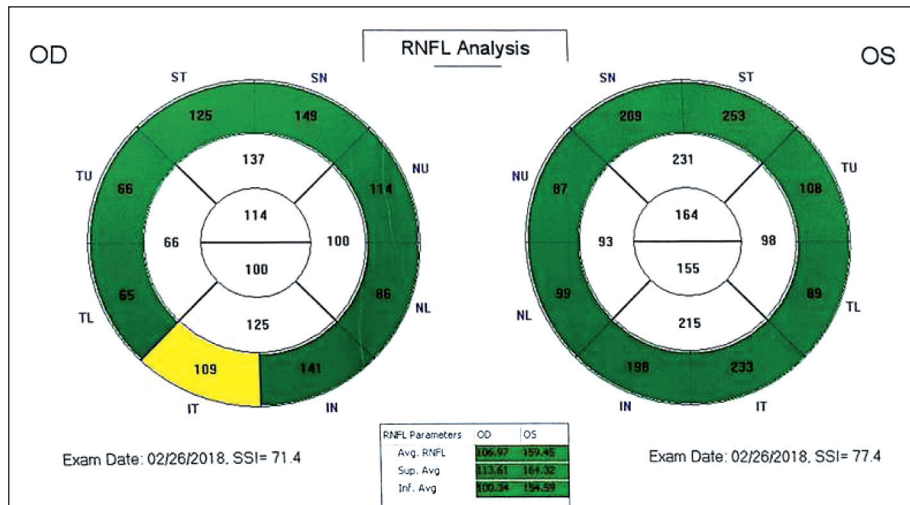


FIGURE 2: Average RNFL thickness is 106.97 µm in right eye and 159.45 µm in left eye.

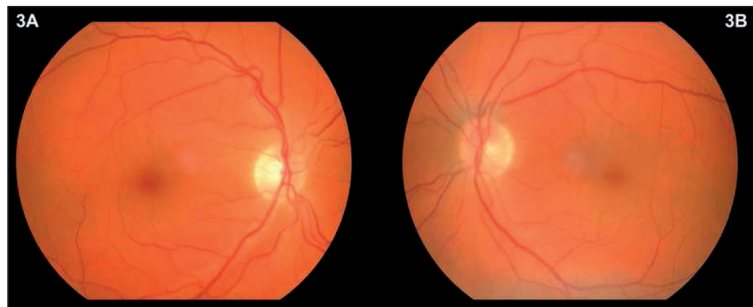


FIGURE 3: A-B: Post treatment fundus photos. Both optic discs are mildly pale.

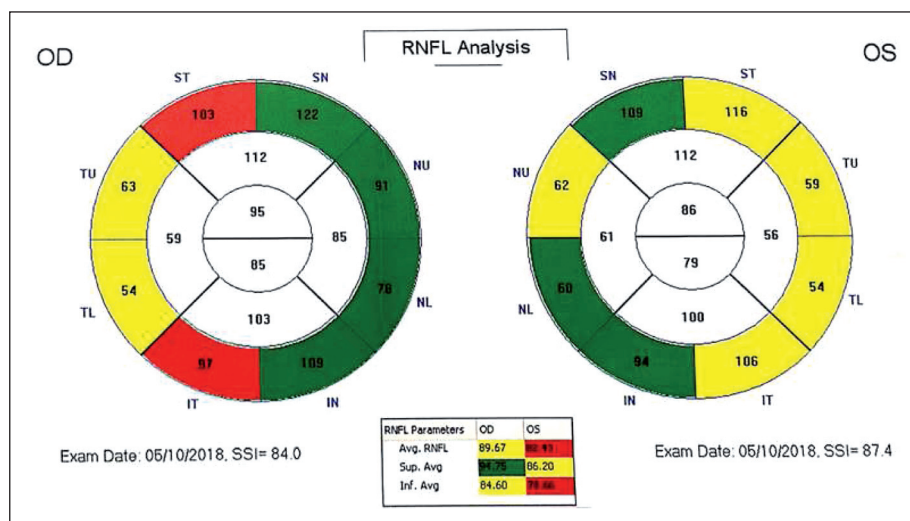


FIGURE 4: Average RNFL thickness is 89.67 µm in right eye and 82.43 µm in left eye.

case there was contrast uptake at the intraocular segment of the left optic nerve in orbital magnetic resonance imaging, but no findings in the right eye with VEP test and orbital magnetic resonance imaging. We considered that slight optic disc oedema in the right eye may have been caused by an earlier phase of optic neuropathy in that eye. The methylprednisolone treatment was started immediately, and the patient's findings improved quickly. Therefore, we determined that bilateral oedematous optic nerve head may be related to imatinib usage in our patient.

In conclusion, imatinib is an important drug for treatment of CML, but it may cause BON, which is a very serious ocular side effect.<sup>1</sup> We want to emphasize the importance of systemic medication review of the patients for early diagnosis, correct and rapid management of the diseases.

#### Acknowledgement

We would like to thank Ece Akçeylan for editing the English language.

#### Source of Finance

During this study, no financial or spiritual support was received neither from any pharmaceutical company that has a direct connection with the research subject, nor from a company that provides or produces medical instruments and materials which may negatively affect the evaluation process of this study.

#### Conflict of Interest

No conflicts of interest between the authors and / or family members of the scientific and medical committee members or members of the potential conflicts of interest, counseling, expertise, working conditions, share holding and similar situations in any firm.

#### Authorship Contributions

**Idea/Concept:** Raziye Dönmez Gün, Alev Koçkar; **Design:** Raziye Dönmez Gün; **Control/Supervision:** Elvan Alper Şengül; **Data Collection and/or Processing:** Alev Koçkar, Burcu Altunrende; **Analysis and/or Interpretation:** Alev Koçkar, Burcu Altunrende, Elvan Alper Şengül; **Literature Review:** Raziye Dönmez Gün, Alev Koçkar; **Writing the Article:** Raziye Dönmez Gün, Alev Koçkar; **Critical Review:** Elvan Alper Şengül, Burcu Altunrende.

## REFERENCES

1. Druker BJ, Sawyers CL, Kantarjian H, Resta DJ, Reese SF, Ford JM, et al. Activity of a specific inhibitor of the BCR-ABL tyrosine kinase in the blast crisis of chronic myeloid leukemia and acute lymphoblastic leukemia with Philadelphia chromosome. *N Engl J Med.* 2001;344(14):1038-42. [[Crossref](#)] [[PubMed](#)]
2. Ho WL, Wong H, Yau T. The ophthalmological complications of targeted agents in cancer therapy: what do we need to know as ophthalmologists? *Acta Ophthalmologica.* 2012;91(7):604-9. [[Crossref](#)] [[PubMed](#)]
3. Fraunfelder FW, Solomon J, Druker BJ, Esmaeli B, Kuyul J. Ocular side effects associated with imatinib mesylate (Gleevec). *J Ocul Pharmacol Ther.* 2003;19(4):371-5. [[Crossref](#)] [[PubMed](#)]
4. Kwon SI, Lee DH, Kim YJ. Optic disc edema as a possible complication of imatinib mesylate (Gleevec). *Jpn J Ophthalmol.* 2008;52(4):331-3. [[Crossref](#)] [[PubMed](#)]
5. Kusumi E, Arakawa A, Kami M, Kato D, Yuji K, Murashige N, et al. Visual disturbance due to retinal edema as a complication of imatinib. *Leukemia.* 2004;18(6):1138-9. [[Crossref](#)] [[PubMed](#)]
6. DeLuca C, Shenouda-Awad N, Haskes C, Wrzesinski S. Imatinib mesylate (Gleevec) induced unilateral optic disc edema. *Optom Vis Sci.* 2012;89(10):e16-22. [[Crossref](#)] [[PubMed](#)]
7. Govind Babu K, Attili VS, Bapsy PP, Anupama G. Imatinib induced optic neuritis in a patient of chronic myeloid leukemia. *Int Ophthalmol.* 2007;27(1):43-4. [[Crossref](#)] [[PubMed](#)]
8. Napolitano M, Santoro M, Mancuso S, Carlisi M, Raso S, Tarantino G, et al. Late onset of unilateral optic disc edema secondary to treatment with imatinib mesylate. *Clin Case Rep.* 2017;5(10):1573-5. [[Crossref](#)] [[PubMed](#)] [[PMC](#)]