

Atypical Radiological Appearances of Diverticula in the Gastrointestinal Tract

GASTROİNTESTİNAL SİSTEMDE ATİPİK GÖRÜNÜMLÜ DİVERTİKÜLLER

Yücel ÜSTÜNDAĞ*, Çağlar BAYSAL*, Sedat BOYACIOĞLU*, İclal İŞIKLAR**, Rabia KÖKSAL*

* Dept. of Gastroenterology, Medical School of Baskent University,

** Dept. of Radiology, Medical School of Baskent University, Ankara/TURKEY

Summary

Other than the colon, diverticular disease in the GI tract may affect small intestine and esophagus. Each localization has a unique pathogenesis, clinical manifestations and morphologic appearances as well. We describe two unusual morphologies of diverticular disease affecting duodenum and esophagus. In one case we observed a large extraluminal duodenal diverticulum from which many small diverticula arose. The other was a case of esophageal diverticulosis which was an incidental finding in a patient with chronic renal failure. The detailed discussion deals with radiologic appearances and pathogenesis.

Key Words: Diverticular disease, Duodenum, Esophagus

T Klin J Gastroenterohepatol 2001, 12:44-48

Özet

Divertiküler hastalık kolon dışında, ince barsak ve ösafagusda da görülebilmektedir. Divertiküllerin gastrointestinal sistemin farklı yerleşim kesimlerinde klinik ve morfolojik görünümdeki farklılıkları kadar, patofizyolojik farklılıklar da dikkati çekmektedir. Bu yayında, divertiküler hastalığın duodenum ve ösafagusda daha önce bildirilmemiş iki farklı görünümünü rapor etmekteyiz. İlk olguda zemininde bir çok mini divertiküller olan, geniş ağızlı bir duodenal divertikül gösterilmiştir. Kronik böbrek yetmezliği tanılı diğer olguda ise ösafagusa ait atipik bir pseudodivertiküloz saptanmıştır. Her iki olguda radyolojik görünümler ve olası patogenezin detaylı tartışması yapılmıştır.

Anahtar Kelimeler: Divertiküler hastalık, Duodenum, Ösafagus

T Klin Gastroenterohepatol 2001, 12:44-48

Diverticular disease was used to indicate the occurrence of diverticula in the large bowel. However, it can affect the rest of the gastrointestinal (GI) tract such as the small intestine and the esophagus (1-3). The small intestinal and esophageal diverticular formations are interesting with regard to their etiopathogenesis, clinical complications and morphologic appearances as well (1-4).

We report and discuss the pathophysiology of two cases that involved unusual presentations of extra-colonic diverticular disease in the GI tract. In one case, we observed a large extraluminal duodenal diverticulum from which many small diverticuli arose. The condition caused severe upper gastrointestinal (GI) bleeding. The other was a case of esophageal diverticulosis, which was an incidental finding in a patient with chronic renal failure.

Case 1

A 60-year-old woman was admitted to our emergency department with severe hematemesis. She had undergone a coronary bypass operation 3 months earlier, and was receiving warfarin therapy

Geliş Tarihi: 18.10.2000

Yazışma Adresi: Dr.Yücel ÜSTÜNDAĞ
Bağcılar 5. Sok 7/4 Ceren Apt.
Gaziosmanpaşa, 06700,
Ankara/TURKEY

for femoral artery thrombosis that developed after the surgery. An emergency upper endoscopy revealed blood oozing from a wide-mouthed diverticulum in the distal duodenum. An adherent clot was covering the base of the diverticulum. There was no blood coming through ampulla of Vater, and the mucosa of the distal duodenum was normal in appearance. After 3 to 5 minutes of water irrigation and observation, the clot remained in place and the bleeding stopped. Three days later, a repeat endoscopy using a side-viewing endoscope revealed a large duodenal diverticulum arising from the third part. We observed that the base of diverticulum was actually composed of many small diverticula of various sizes. An upper GI barium study demonstrated the presence of two diverticula: one with a wide orifice, and a small distal diverticulum with a narrow neck. The diverticula were located in the medial walls of the third and fourth sections of the duodenum. The proximal one was clearly seen to contain multiple small out-pouchings (Figure 1).

Case 2

A 29-year-old man was referred to our clinic for routine preoperative evaluation for renal transplantation. He had been on regular hemodialysis for 3 years due to chronic renal failure. The patient's primary renal pathology was chronic pyelonephritis. His physical examination was unremarkable. He had undergone upper GI endoscopy approximately 2 years earlier to investigate dyspepsia, and was diagnosed with mild esophagitis and antral gastritis. After two months course of omeprazole treatment, control endoscopy revealed regression of inflammation findings in the lower esophagus and gastric antrum. When he had the upper endoscopy for the third time, multiple esophageal diverticular outpouchings were noted all along the esophagus wall. The rest of the endoscopic examination was normal. A subsequent upper GI Barium series showed multiple flask-shaped diverticular sacculations along the length of the esophagus (Figure 2). There was no evidence of esophagitis, esophageal stricture or mass lesion, on endoscopy or barium esophagogram. We collected random endoscopic biopsies from normal appearing mucosa

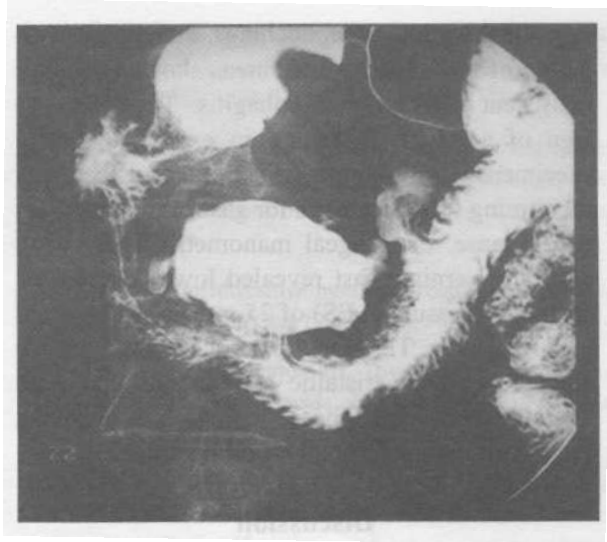


Figure 1. The barium radiology of upper GI tract revealed many small diverticula in a large diverticuli resembling those of a bovine udder, which we named 'intradiverticular diverticulosis'. Distally, a smaller diverticulum is seen also.

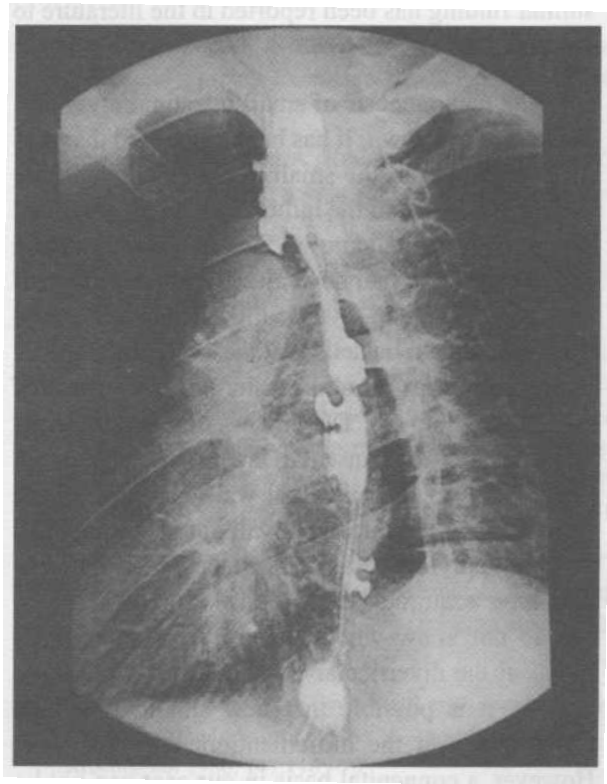


Figure 2. An esophageal barium study demonstrates many small and large diverticular formations all along the path of esophagus.

near the diverticular outpouchings. Pathologic evaluation of these biopsy specimens showed changes consistent with reflux esophagitis. There was no sign of amyloid deposition in examined biopsy specimens. A 24-hour session of esophageal pH monitoring was diagnostic for gastroesophageal reflux disease. Esophageal manometric study done after an overnight fast revealed lower esophageal sphincter pressure (LES) of 25 mmHg, and normal LES relaxation. Through the esophageal corpus, we noted repetitive peristaltic contractions that were longer than normal. These findings were assessed as nonspecific esophageal motor disorder.

Discussion

The first case represents a very extraordinary example of an extraluminal duodenal diverticulum in which multiple small outpouchings arose from a large diverticular sac. The radiologic views resembled those of a bovine udder. This was an exceptional finding and we named the phenomenon intradiverticular diverticulosis. To our knowledge, no similar finding has been reported in the literature to date.

The pathogenesis of small intestinal diverticula remains unknown. It has been suggested that motor dysfunction of the small intestine, the pressure differential between the lumen and the extraluminal cavity, and other unknown factors may play roles (2,5) Diverticula that have already formed may enlarge as a sequela of diverticulitis. This is explained by a ball-valve mechanism at the neck of diverticulum, which traps air and results in enlargement of the diverticulum (6). The process of mucosal herniation through the muscular layer also depends on the strength of the intestinal wall. However, there are defects in the intestinal wall along the pathway of the supplying vessels, through which the pulsion-type acquired outpouchings can occur (2,7). We do not know whether there are similar weak points at the diverticular base, and but if these are present, it is possible that new small diverticula could form via the aforementioned mechanisms. However, a congenital basis in our case can not be excluded completely. In any case, intradiverticular diverticulosis should not be regarded as a mere

anatomic variant with no clinical relevance. We believe that some of the risks associated with duodenal diverticula, such as perforation and bleeding may be more likely in cases of intradiverticular diverticulosis.

A classic example of diverticulosis in the esophagus is intramural esophageal diverticulosis (8). This is a rare condition in which innumerable, flask-shaped outpouchings are evenly distributed along the entire length of the esophageal mucosal glands (9,10). These diverticula represent the dilated excretory ducts of esophageal mucosal glands, and their radiological appearance is similar to that of sinuses of Rokkitansky-Asckhoff in the gall bladder. Since such outpouchings are not true diverticula, this condition has been called esophageal intramural pseudodiverticulosis (EIPD) (10). EIPD has been reported in association with diabetes mellitus, esophageal cancer, esophageal candidiasis, and gastroesophageal reflux, esophagitis (11-15). The pathogenesis is not completely understood, but inflammation and the increased intraluminal pressure are presumed to be essential features of the mechanism behind EIPD (12-15). Clearly, inflammation rarely result in EIPD (15). Authors suggest that certain individual must be susceptible, such as those with congenital neurovascular gaps in their muscular mucosa, or those with submucosal glands that enlarge under the effects of inflammation (16).

Our second case we presented differs from the usual form of EIPD in the following ways; 1) fewer diverticula compared to the numbers of outpouchings typical in EIPD. 2) endoscopy clearly showed diverticula with wide-mouthed orifices. The orifices of the diverticula in typical EIPD are so that they are difficult to see and, reliance on endoscopy can result in a missed diagnosis (15) 3) EIPD patients usually present with dysphagia, whereas our patient was asymptomatic (17); 4) our patient's condition was not associated with peptic stricture, esophageal cancer, diabetes mellitus or esophageal candidiasis; only with chronic renal failure and reflux esophagitis.

We consider our patient's esophageal diverticulosis to be an acquired condition, since diverticula were not seen on any previous endoscopic examination. The mechanism of diverticuli formation in this case is still unclear, however. The objective findings in hand are the presence of esophageal diverticulosis, reflux esophagitis, esophageal motility changes and chronic renal failure. Reflux esophagitis is important with regard to EIPD in two ways. First mucosal inflammation in the esophagus blocks intramural ducts with plugs of viscous mucus and desquamated cells, and this leads to their dilatation (17);. Second, chronic inflammation leads to dysmotility in the esophageal corpus (18,19). The first mechanism produces the characteristic EIPD findings we see in susceptible individuals. We suggest that our patient's condition was affected by the motility changes in esophagus in association with reflux esophagitis and possibly with chronic renal failure as well. It has been reported that prolonged and high- amplitude esophageal contractions like those our patient demonstrated on esophageal manometric study, can lead to mucosal herniations through gaps in the muscular layer. The herniations ultimately result from increased intraluminal pressure in the esophagus. It has also been demonstrated that chronic renal failure patients can develop nonspecific esophageal motility changes such as prolonged high amplitude contractions (20). Esophageal motility changes in the setting of reflux esophagitis and chronic renal failure may be principally responsible for the formation of esophageal diverticula in our case.

This report describes extraordinary views of GI diverticula formation. We believe that the clinicians and radiologists should be aware of these kind of endoscopic and radiological appearances of diverticular disease in the GI tract.

REFERENCES

1. Afridi SA, Fichtenbaum CJ, Taubin H. Review of duodenal diverticula. *Am J Gastroenterol* 1991; 86:935-8.
2. Krishnamurthy S, Kelly MM, Rohrmann CA, Schuffler MD. Jejunal diverticulosis. *Gastroenterology* 1983; 85:538-47.
3. Hammon JW, Rice RP, Postlethwait RW, Young WG. Esophageal intramural diverticulosis. *The Annals of Thoracic Surg* 1974; 17:260-7.
4. Harford WV. Diverticula of the hypopharynx and esophagus, stomach, and small bowel. In Schlesinger MH, Fordtran JS. *Textbook of Gastroenterology*. WB Saunders, 1998: 309-16.
5. Eggert A. Interdigestive motility in duodenal diverticula. *Langenbecks Arch Chir* 1988; 373: 97-103.
6. Dietzen CD, Pemberton JH. Diverticulitis. *Textbook of Gastroenterology*. Yamada T. Philadelphia: Lippincott, 1991: 1734-48.
7. Gore RM, Ghahremani GG, Kirsch MD, Nemcek AA, Karoll MP. Diverticulitis of the duodenum: Clinical and radiological manifestations of seven cases. *Am J Gastroenterol* 1991; 86:981-5.
8. Mendle K, McKay JM, Tanner CH. Intramural diverticulosis of the esophagus and Rokitansky-Aschoff sinuses of the gall bladder. *Br J Radiol* 1960; 33:496-501.
9. Lupovitch A, Tippins R. Esophageal intramural pseudodiverticulosis: A disease of adnexal glands. *Diagnostic Radiol* 1974; 47:496-8.
10. Boyd RM, Bogoch A, Greig JH, Trites EW. Esophageal intramural pseudodiverticulosis. *Radiology* 1974; 113:271-2.
11. Castillo S, Aburashed A, Kimmelman J, Alexander LC. Diffuse intramural esophageal pseudodiverticulosis. *Gastroenterology* 1977; 72:541-5.
12. Troupin RH. Intramural esophageal diverticulosis and moniliasis. *Am J Roentgenol* 1968; 104:613-6.
13. Plavsic BM, Chen MY, Gelfand DW, Drnovsek VH, Williams JP 3rd, Kogutt MS, Terry JA, Plenkovich D. Intramural pseudodiverticulosis of the esophagus detected on barium esophagograms: Increased prevalence in patients with esophageal carcinoma. *Am J Roentgenol* 1995; 165:1381-85.
14. Stephens WP, Mossman A, Ratcliffe JF, Gould DA, Oleesky S. Intramural pseudodiverticulosis: An unusual cause of benign esophageal stricture. *Postgrad Med J* 1986; 62:201-4.
15. Levine MS, Moolten DN, Herlinger H et al. Esophageal intramural pseudodiverticulosis: A reevaluation. *Am J Roentgenol* 1986; 147:1165-70.
16. Troupin RH. Intramural esophageal diverticulosis and moniliasis. *Am J Roentgenol* 1968; 104:613-6.

17. Bruhlmann WF, Zollikofer CL, Maranta E, Hefti ML, Bivetti J, Giger M, Wellauer J, Blum AL. Intramural pseudodiverticulosis of the esophagus: report of seven cases and literature review. *Gastrointest Radiol* 1981; 6:199-208.
18. Cho S, Sanders MM, Turner MA, Liu C, Kipreos BE. Esophageal intramural pseudodiverticulosis. *Gastrointest Radiol* 1981; 6:9-16.
19. Murney RG, Linne JH, Curtis J. High amplitude peristaltic contractions in a patient with esophageal intramural pseudodiverticulosis. *Dig Dis Sci* 1983; 28:843-7.
20. Dogan I, Unal S, Sindel S, Tuncer C, Arinsoy T, Bali M, Kandilci U, Hasanoglu E. Esophageal motor function in chronic renal failure. *Nephron* 1996; 72:346-7.