

Multiple Milia and Comedones Secondary to Radiotherapy: Case Report

Radyoterapiye İkincil Gelişen Multipl Milyum Kistleri ve Komedonlar

Duru TABANLIOĞLU ONAN, MD, Msc,^a
Nuran ALLI, MD, Assoc.Prof.^a

^aClinic of Dermatology,
Numune Training and
Research Hospital, Ankara

Geliş Tarihi/Received: 25.03.2010
Kabul Tarihi/Accepted: 03.11.2010

Yazışma Adresi/Correspondence:
Duru TABANLIOĞLU ONAN, MD, Msc
Numune Training and Research Hospital,
Clinic of Dermatology, Ankara,
TÜRKİYE/TURKEY
t_duru@hotmail.com

ABSTRACT The commonly known cutaneous side effects of radiotherapy are acute-chronic radiodermatitis and subsequent development of neoplasia in the radiation-damaged skin. However there are some additional rare cutaneous sequelae of radiotherapy including milia, comedones, Favre-Racouchot-like disease, multiple small digitate keratoses and lichen sclerosus et atrophicus. In this report, we present a patient who developed multiple milia and comedones on his right preauricular-postauricular regions and cheek after local radiotherapy for his salivary duct carcinoma. As the lesions were confined to the area of irradiation, we accepted the development of milia and comedones as a sequela of radiotherapy. The aim of our report is to draw attention to these unusual cutaneous side effects of radiotherapy and discuss their possible pathogenesis.

Key Words: Radiotherapy; skin; adverse effects

ÖZET Radyoterapinin yaygın olarak karşılaşılan kutanöz yan etkileri akut-kronik radyodermatit ve radyasyon hasarına uğramış deride neoplazi gelişimidir. Buna ek olarak nadir görülen bazı radyoterapi sekelleri arasında milyum kistleri, komedonlar, Favre-Racouchot benzeri hastalık, multipl küçük dijital keratozlar ve liken sklerotrofik sayılabilir. Burada tükürük bezi karsinomuna yönelik verilen lokal radyoterapi sonrasında sağ preaurikuler-postaurikuler bölgeler ve yanakta multipl milyum kistleri ve komedonlar gelişen bir olguyu sunmaktayız. Lezyonlar radyasyon uygulanan alanlara sınırlı olduğundan milyum kistleri ve komedonlar radyoterapi sekeli olarak kabul edilmiştir. Bu olguyu sunmaktaki amacımız radyoterapinin sık görülmeyen bu yan etkilerine dikkat çekmek ve patogenezi tartışmaktır.

Anahtar Kelimeler: Radyoterapi; cilt; istenmeyen etkiler

Türkiye Klinikleri J Med Sci 2012;32(4):1114-7

Acute and chronic radiodermatitis and the risk of subsequent development of neoplasia in radiation-damaged skin are the known side effects of radiotherapy. However some additional cutaneous sequelae of radiotherapy have been reported in the literature including milia, comedones, Favre-Racouchot-like disease, multiple small digitate keratoses and lichen sclerosus et atrophicus.¹⁻⁶ Herein, we report a case who developed multiple milia and comedones in the area of local radiotherapy.

CASE REPORT

A 64-year-old male patient presented with an induration on his right cheek. Magnetic resonance imaging (MRI) revealed a mass and the histopatholog-

ical examination of this mass revealed a high grade salivary duct tumor that showed invasion to fat and muscle. The patient had radiotherapy to the right side of the right maxillary sinus after this diagnosis. One year later a biopsy taken from the subconjunctival mass which was detected in the temporal region of the right lower eyelid which showed an infiltration of the salivary duct carcinoma. He had a second radiotherapy for this infiltration.

One year before he was consulted at our clinic; the patient had recognized an asymptomatic eruption on his right postauricular area that spread to his neck and preauricular areas. On dermatological examination of the right preauricular and postauricular regions, plaques composed of multiple, grouped, pearly papules were observed on an erythematous base (Figures 1, 2). Some of the papules were extending from the preauricular region to the cheek in a linear form. Additionally, there were multiple comedones spreading among the papules and around the plaques (Figure 3). The patient had no subjective complaints.

DISCUSSION

Milia and comedones are among the rare cutaneous sequela of radiotherapy. Milia are superficial epidermoid cysts that are observed as white to yellow, milimetric, scattered papules. Comedones are formed by the impaction and distension of the follicles with a keratinous plug.

Primary milia arise spontaneously on the face in predisposed individuals without a known trigger and represent a keratinizing type of benign tumor derived from the lowest portion of the infundibulum of vellus hair follicles approximately at the level of the sebaceous duct. In contrast, secondary milia represent retention cysts caused by proliferative tendencies of the epithelial structures such as eccrine sweat ducts, sebaceous ducts, hair follicles or aberrant epidermis after injury.⁷ Secondary milia may occur following diseases such as epidermolysis bullosa, porphyria cutanea tarda, bullous pemphigoid, bullous lupus erythematosus, Sweet's syndrome, herpes zoster, lichen planus;

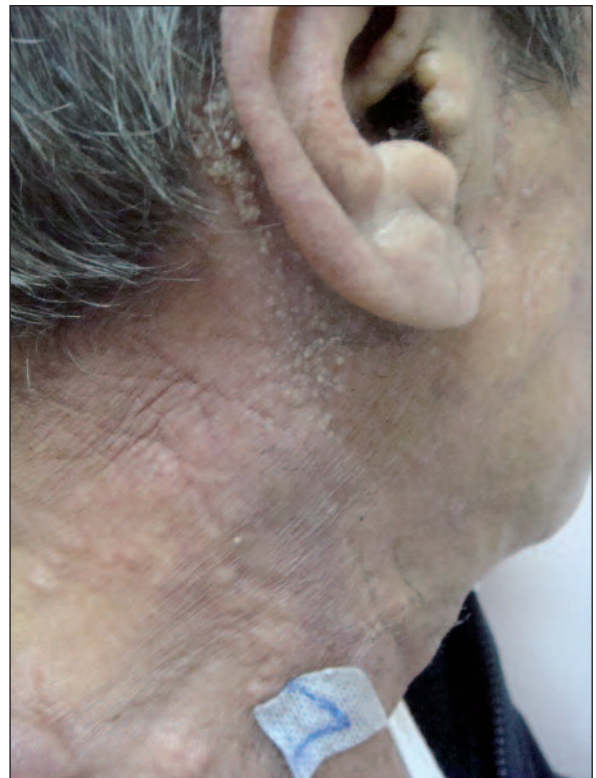
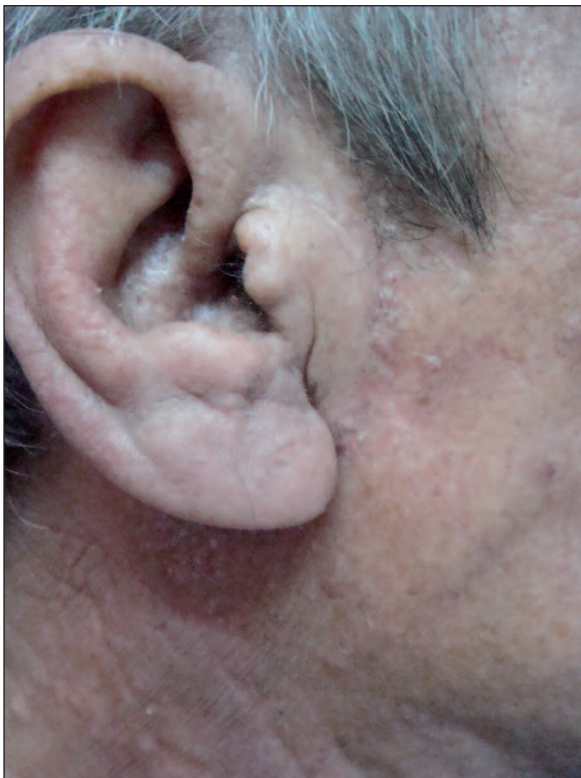

FIGURE 1, 2: Multiple, pearly papules in groups, on an erythematous base forming plaques on the right preauricular and postauricular regions. (See for colored from <http://tipbilimleri.turkiyeklinikleri.com/>)

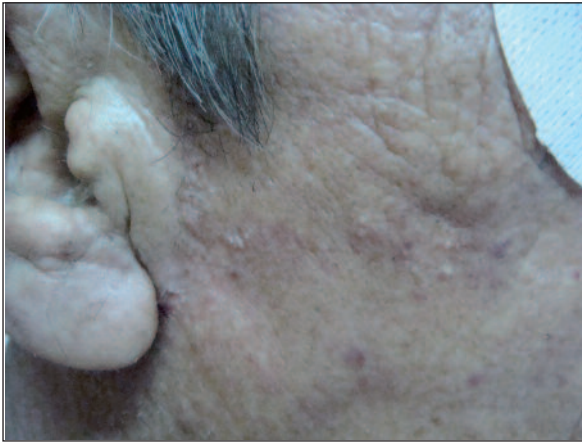

FIGURE 3: Multiple comedones spreading among the papules and around the plaques.

(See for colored from <http://tipbilimleri.turkiyeklinikleri.com/>)

they may be associated with some medications such as benoxaprofen, topical steroids, 5-fluorouracil, cyclosporine, penicillamine; or due to a traumatic stimulus such as radiotherapy, dermabrasion, second-degree burns, chemical peels, skin grafts and ablative laser therapy.⁸

Milia secondary to radiotherapy has been reported only in two cases in the literature.^{1,4} In one of these cases, radiotherapy was applied for a basal cell epithelioma on the face, and just like in our case, both milia and comedones were observed on the normal skin in the vicinity of the radiotherapy area.¹ In the other case, multiple milia developed in the area of radiotherapy given for breast cancer, and exposure to radium for a strawberry nevus. The patient also had multiple chest X-rays in her childhood for screening tuberculosis.⁴

The reaction to radiation is determined according to cell type in a normal tissue. Epidermis, hair follicles and glandular cells (e.g., sweat or salivary glands) manifest acute reactions due to their rapid mitotic rate.⁹ There is a continuum of change of the tissues from the acute to the chronic period after irradiation.¹⁰ The late effects of treatment with radiation are scarring and fibrosis.⁹ A gradual increase in the amount of fibrous tissue is observed in the irradiated tissues and organs; for example,

acini depleted in the acute period do not regenerate but are replaced by fibrous tissue in case of heavily irradiated salivary glands.¹⁰

Development of milia in the area of irradiation is probably due to the effect of radiotherapy on epidermis, hair follicles and sweat glands from where secondary milia are known to originate. Secondary milia are accepted as the retention cysts formed by proliferative tendencies of the epithelium after injury.⁷ The mechanism of formation of milia due to trauma is not certain yet, but it may be through epidermal implantation or by providing a stimulus for undifferentiated pilosebaceous cells to proliferate.⁸ Radiotherapy may be the traumatic stimulus that causes the proliferation of epithelium in the formation of milia.

Pathogenesis of comedone production is accepted to be related to over-proliferation of sebaceous ducts, retention of hyper-proliferating ductal keratinocytes in these ducts and formation of a keratin plug. For the radiation-induced comedones, this ductal hyperproliferation is likely to be stimulated by changes in the lipid composition of sebum as a result of irradiation.² Another factor that may contribute to formation of comedones after radiotherapy may be the change in the structure of the pilosebaceous apparatus in the form of a blockade of the outlets of the sebaceous glands due to a cicatricial stricture formation.¹ This mechanism may also have a role in the formation of milia. As the late effects of radiation are scarring and fibrosis; obliteration of eccrine sweat ducts, sebaceous ducts and hair follicles with this process may be another factor in the etiology of milia formation.

Our case developed multiple milia and comedones on his right preauricular-postauricular regions and cheek after local radiotherapy performed for his salivary duct carcinoma. As the milia and comedones were limited to the area of treatment, we accepted them as consequences of radiotherapy. In this report, our aim was to point out the two rare cutaneous side effects of radiotherapy, milia and comedones, and discuss the possible pathogenesis of their formation.

REFERENCES

1. Ronchese F. Cicatricial comedos and milia. *Arch Derm Syphilol* 1950;61(3):498-500.
2. Lee A, Griffiths WA. Multiple milia due to radiotherapy. *J Dermatolog Treat* 2002;13(3):147-9.
3. Martin WM, Bardsley AF. The comedo skin reaction to radiotherapy. *Br J Radiol* 2002;75(893):478-81.
4. Breit S, Flaig MJ, Wolff H, Plewig G. Favre-Racouchot-like disease after radiation therapy. *J Am Acad Dermatol* 2003;49(1):117-9.
5. Burns DA. Post-irradiation digitate keratoses. *Clin Exp Dermatol* 1986;11(6):646-9.
6. Yates VM, King CM, Dave VK. Lichen sclerosus et atrophicus following radiation therapy. *Arch Dermatol* 1985;121(8):1044-7.
7. Kirkham N. Tumors and cysts of the epidermis. In: Elder DE, Elenitsas R, Johnson BL, Murphy GF, eds. *Lever's Histopathology of the Skin*. 9th ed. Philadelphia: Lippincott Williams and Wilkins; 2005. p.805-66.
8. Berk DR, Bayliss SJ. Milia: a review and classification. *J Am Acad Dermatol* 2008;59(6):1050-63.
9. Porock D, Nikolett S, Kristjanson L. Management of radiation skin reactions: literature review and clinical application. *Plast Surg Nurs* 1999;19(4):185-92, 223.
10. Moore MJ. The effect of radiation on connective tissue. *Otolaryngol Clin North Am* 1984;17(2):389-99.