

Appendiceal Neuroendocrine Tumor and Colonic Angiodysplasia Association in a Sixteen-Year-Old Girl

Halil İbrahim TANRIVERDİ^a,
 Halis Can DEMİRTÜRK^a,
 Semir AYHAN^b,
 Aydın ŞENCAN^a,
 Cüneyt GÜNŞAR^a

Departments of
^aPediatric Surgery,
^bPathology,
 Manisa Celal Bayar University
 Faculty of Medicine,
 Manisa, TURKEY

Received: 31.05.2018

Accepted: 29.06.2018

Available online: 05.03.2019

Correspondence:

Halil İbrahim TANRIVERDİ
 Manisa Celal Bayar University
 Faculty of Medicine,
 Department of Pediatric Surgery,
 Manisa, TURKEY
 halilibrahimtanriverdi@gmail.com

This work was presented as a poster at the
 35th National Congress of Pediatric Surgery
 (25-30 October 2017, Edirne).

ABSTRACT Neuroendocrine tumors (NETs) arise from neural crest cells and are mostly seen in the gastrointestinal system (GIS) and most commonly in the appendix. They are rare in children. They are diagnosed incidentally in the pathologic examination in patients who are usually operated on for appendicitis. Colonic angiodysplasia is often seen over the age of 60 years and is an important cause of lower GIS bleedings. It is quite rare in children and there isn't enough experience about its management. In this study, a 16-year-old girl with appendiceal NET and angiodysplasia in the ascending colon is presented. Two different pathologies, each of is rare in children, were detected together. The association of these two pathologies has not been found in the literature.

Keywords: Neuroendocrine tumor; appendix; angiodysplasia; child

Carcinoid or neuroendocrine tumors (NETs) are originated from neural crest cells. They are commonly seen in gastrointestinal system (GIS) and are most commonly seen in the appendix. Appendiceal NET is quite rare in children.¹ These tumors are usually incidentally diagnosed during pathological examination of the appendix in children who underwent appendectomy due to appendicitis.^{2,3} It is seen with the ratio of 0.1% in children who goes to appendectomy.

Colonic angiodysplasia is often seen over the age of 60 years and is an important cause of lower GIS bleeding. It is very rare and there isn't enough experience about it in children. Few cases have been reported.⁴⁻⁶

We report a 16-year-old girl who hemicolectomy was performed because of appendiceal NET and angiodysplasia in the hepatic flexura of colon.

CASE REPORT

A 16-year-old girl was referred with vomiting and abdominal pain starting in the periumbilical region and located in the right lower quadrant thereafter. There wasn't any characteristic in her medical background and family history. In the physical examination, there was sensitivity and defense in the lower right quadrant. In laboratory tests were normal except leukocytosis (16200/mm³). Aperistaltic, incompressible tubular structure with 10 mm diameter in the right lower quadrant of the abdomen was determined at ultrasonography. The wall of the tubular structure and peripheral mesen-

teric fatty tissues were inflamed. Patient was operated with an initial diagnosis of appendicitis. A retroceally-located, approximately 12 cm in length, hyperemic, edematous appendix was determined. There wasn't any mass in the appendix or ileocecal region. Appendectomy was performed and the patient was discharged on the second day postoperatively.

At the pathological examination, 1 cm in diameter, a well-differentiated NET was detected in proximal appendix along with the acute appendicitis (Figure 1). Angioinvasion was not determined in the tumor but there was tumoral tissue on the surgical margin. So, thoracic computerized tomography (CT), abdominal CT and positron emission tomography (PET) were performed. In abdominal CT, a solid mass with dot-style calcifications in the size of approximately 4x5 cm was determined between the liver and the right kidney in hepatic flexure of the colon (Figure 2). Metastatic tissue was not observed in PET. Second operation was performed because of the mass and the tumor tissue at the surgical margin. A dark red mass located in the colonic wall, approximately 3x3.5 cm in size on the hepatic flexion, was evaluated as an arteriovenous malformation. So, right hemicolectomy was performed including ileocecal region, hepatic flexure and the mass totally (Figure 3). The mass was evaluated as angiodysplasia at pathological examination, and also no other tumor tissue was observed. The patient is in the second year of follow-up and there isn't any problem.

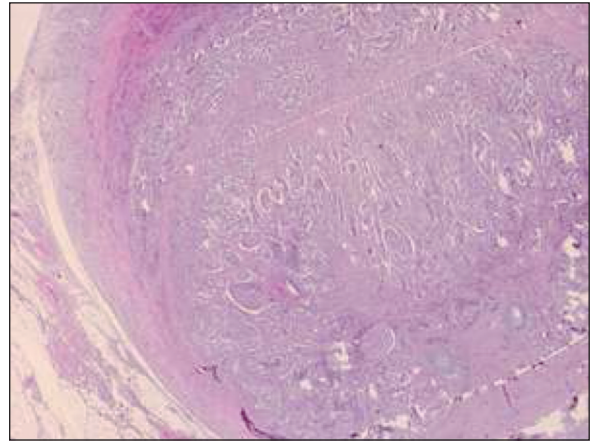


FIGURE 1: In the pathological examination of the appendix, well-differentiated neuroendocrine cells reach the subareolar area.

DISCUSSION

NETs are usually incidentally diagnosed during pathological examination of the appendix in children who underwent appendectomy due to appendicitis. In the present case, the patient was admitted with an acute abdomen pattern classically. Appendectomy was performed and NET was found incidentally during pathological examination. In two thirds of the cases, tumors are located at the distal end of appendix.⁷ Tumors are less than 1 cm in size at the large proportion of cases in children. NETs in children are mostly well differentiated. There is no standard for diagnosis and treatment in children because of the rare occurrence of these tumors.^{2,3} Findings of high risk in adults are described as follows: presence of tumor at the base of the appendix (at the surgical margin), tumor size greater than 2

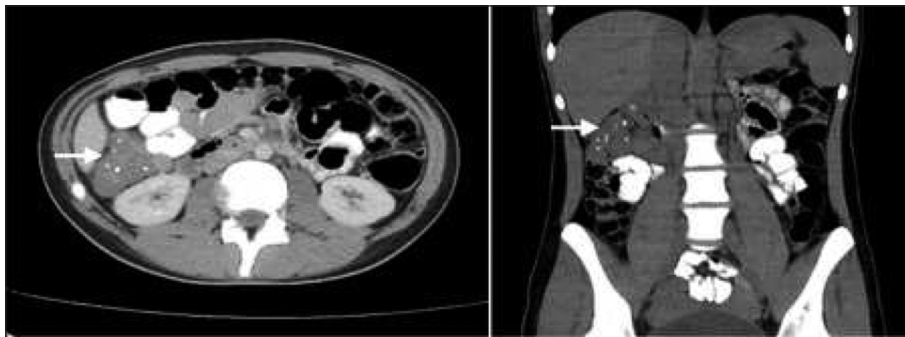


FIGURE 2: In abdominal CT, a solid mass 4x5 cm in size with dot-style calcifications, which is located between liver and right kidney on hepatic flexura (arrow).

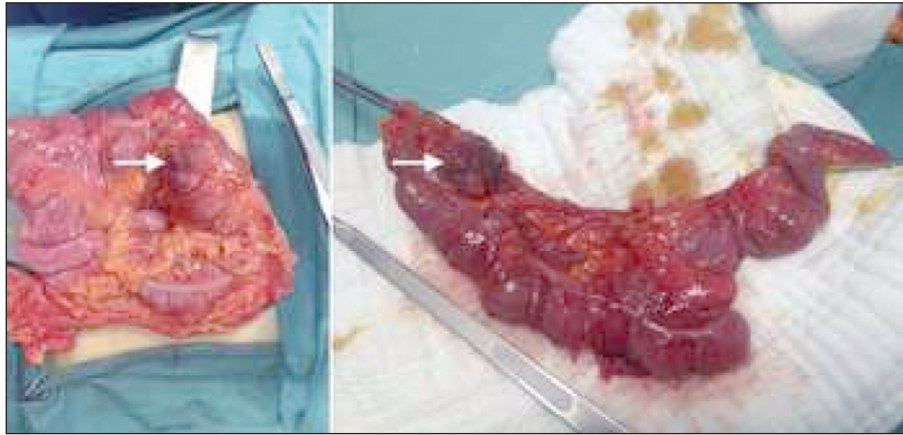


FIGURE 3: A dark red mass 3x3.5 cm in size located in the colonic wall, on hepatic flexura (arrow). Right hemicolectomy including the mass was performed.

cm, mesoappendix involvement, involvement of lymphovascular ducts and detection of adenocarcinoma cells.⁸ In the presence of these risk factors, advanced surgery involving hemicolectomy is recommended in adults.⁸ In our case, the pathologic examination of the appendix revealed a well-differentiated, 1 cm in diameter NET in the appendix together with the pathology of acute appendicitis. Angioinvasion was not determined in the tumor. However, tumoral continuity was determined in the surgical margin.

Hemicolectomy is prevented in recent years due to the fact that the survival rates are close to 100% and the risk factors are low in childhood studies.^{9,10} Ileocecal resection is sufficient in risky cases. Many studies have indicated that only appendectomy is sufficient for risk free cases.^{9,10} We decided hemicolectomy on the presence of a tumor to the surgical margin and the detection of a solid mass in the hepatic flexure in the ascending colon on CT. Hemicolectomy was performed including the ileocecal region, ascending colon and hepatic flexure with the total excision of the mass.

Postoperative follow-up is usually unnecessary in small NETs.^{8,10} There isn't any consensus on the follow-up of large tumors. In our case, no NET tissue was found at pathologic examination after hemicolectomy, and the colonic mass detected on tomography was evaluated as angiodysplasia.

Angiodysplasias are small benign vascular malformations located in the intestinal mucosa or sub-

mucosa. Angiodysplasia is the cause of 40% of the lower GIS bleedings in adults. It is especially seen in older ages and is commonly located in the cecum and right hemicolon. The reason of right location is due to the high pressure on the wall of the cecum and right hemicolon. It is very rare in children. Few cases have been reported.^{4,6} The largest series were published by Mondragon et al with 9 cases and by Chuang et al with 18 cases.^{4,5} In children, as in adults, they usually present with GIS bleeding.^{4,5} They can rarely cause obstruction or perforation, and might be confronted with acute abdomen findings.⁶ In some studies in children, unlike in adults, they were mostly found in the left hemicolon and unlike adults, lesions in children are thought to be congenital.⁴ However, in the study performed by Chuang et al. lesions were mostly found on the right.⁵ In our case, the lesion was incidentally detected in the right hepatic flexure as a mass in CT and evaluated as an arteriovenous malformation during the operation. It was diagnosed by pathological examination. Unlike relevant literature, there wasn't GIS bleeding or anemia in our case.

CT-angiography is used for the diagnosis of angiodysplasia and has an accuracy of 66%.⁵ GIS endoscopy must be performed to confirm the diagnosis. Treatment is provided according to the severity and repetition of the bleeding. The cases in which the hemorrhage is not excessive and repetitive can be managed conservatively, but sur-

gical treatment is performed in severe and recurrent cases. The intestinal segment including the lesion is resected. In Mondragon's series, 6 of 9 cases were surgically treated, whereas in Chuang et al.'s series, 6 of 18 cases required surgical treatment.^{4,5} In our patient, hemicolectomy was performed for the mass at the hepatic flexura and was performed for NET which was determined at the surgical margin of appendectomy.

Appendectomy only is enough for well-differentiated and distally located NET's treatment. Ileocecal resection is sufficient in cases proximally located and continuing in the surgical margin. However, in our case, hemicolectomy was performed because of the continuation of NET in the surgical margin and because of the detection of mass in right hepatic flexura. Two different pathologies, each of which is rare in children, were detected together in our case. The association of these two pathologies has not been found in the literature yet.

Informed Consent

Informed consent was taken from the parents.

Source of Finance

During this study, no financial or spiritual support was received neither from any pharmaceutical company that has a direct connection with the research subject, nor from a company that provides or produces medical instruments and materials which may negatively affect the evaluation process of this study.

Conflict of Interest

No conflicts of interest between the authors and / or family members of the scientific and medical committee members or members of the potential conflicts of interest, counseling, expertise, working conditions, share holding and similar situations in any firm.

Authorship Contributions

FikirKavram: Cüneyt Günşar; **Tasarım:** Halil İbrahim Tanrıverdi; **Denetleme/Danışmanlık:** Cüneyt Günşar; **Veri Toplama ve/veya İşleme:** Halis Can Demir; **Analiz ve/veya Yorum:** Semin Ayhan; **Kaynak Taraması:** Halil İbrahim Tanrıverdi; **Makalenin Yazımı:** Halil İbrahim Tanrıverdi; **Eleştirel İnceleme:** Aydın Şencan.

REFERENCES

1. Pelizzo G, La Riccia A, Bouvier R, Chappuis JP, Franchella A. Carcinoid tumors of the appendix in children. *Paediatr Surg Int.* 2001;17(5-6):399-402. [Crossref] [PubMed]
2. Doede T, Foss HD, Waldschmidt J. Carcinoid tumors of the appendix in children-epidemiology, clinical aspects and procedure. *Eur J Pediatr Surg.* 2000;10(6):372-7. [Crossref] [PubMed]
3. Kulkarni KP, Sergi C. Appendix carcinoids in childhood: long-term experience at a single institution in Western Canada and systematic review. *Pediatr Int.* 2013;55(2):157-62. [Crossref] [PubMed]
4. de la Torre Mondragón L, Vargas Gómez MA, Mora Tiscarreño MA, Ramírez Mayans J. Angiodysplasia of the colon in children. *J Pediatr Surg.* 1995;30(1):72-5. [Crossref]
5. Chuang FJ, Lin JS, Yeung CY, Chan WT, Jiang CB, Lee HC. Intestinal angiodysplasia: an uncommon cause of gastrointestinal bleeding in children. *Pediatr Neonatol.* 2011;52(4):214-8. [Crossref] [PubMed]
6. Yannam GR, Yu DC, Kelly DR, Chen MK, Beierle EA. Angiodysplasia (vascular malformations) of the colon presenting as an acute abdomen. *J Pediatr Surg.* 2012;47(10):e37-40. [Crossref] [PubMed]
7. Mullen JT, Savarese DM. Carcinoid tumors of the appendix: a population-based study. *J Surg Oncol.* 2011;104(1):41-4. [Crossref] [PubMed]
8. Boudreaux JP, Klimstra DS, Hassan MM, Woltering EA, Jensen RT, Goldsmith SJ, et al. The NANETS consensus guideline for the diagnosis and management of neuroendocrine tumors: well-differentiated neuroendocrine tumors of the jejunum, ileum, appendix, and cecum. *Pancreas.* 2010;39(6):753-66. [Crossref] [PubMed]
9. Virgone C, Cecchetto G, Alaggio R, Ferrari A, Bisogno G, Conte M, et al. Appendiceal neuroendocrine tumours in childhood: Italian TREP project. *J Pediatr Gastroenterol Nutr.* 2014;58(3):333-8. [Crossref] [PubMed]
10. Boxberger N, Redlich A, Böger C, Leuschner I, von Schweinitz D, Dralle H, et al. Neuroendocrine tumors of the appendix in children and adolescents. *Pediatr Blood Cancer.* 2013;60(1):65-70. [Crossref] [PubMed]