










Cutaneous Leishmaniasis: Evaluation of 117 Syrian Immigrants

Kutanöz Layşmanyazis: 117 Suriye'li Hastanın Değerlendirilmesi

 Nermin KARAOSMANOĞLU^a,
 Muzaffer ŞAHİN^a,
 Güler VAHABOĞLU^a,
 Gülfer AKBAY^a,
 Emine YALÇIN EDGÜER^a,
 Tijen ŞAHİN^a,
 Fatma Efsun TANAÇAN^a,
 Hatice Meral EKŞİOĞLU^a,
 Ali Kudret ADİLOĞLU^b

Clinics of
^aDermatology,
^bMicrobiology,
 Ankara Training and Research Hospital,
 Ankara, TURKEY

Received: 09.10.2018
 Received in revised form: 02.12.2018
 Accepted: 11.12.2018
 Available online: 02.01.2019

Correspondence:
 Nermin KARAOSMANOĞLU
 Ankara Training and Research Hospital,
 Clinic of Dermatology, Ankara,
 TURKEY/TÜRKİYE
 nermin_kara@yahoo.com

ABSTRACT Objective: Cutaneous leishmaniasis (CL), which presents with nodulo-ulcerative lesions in the skin, is an endemic disease in Syria and in some of the regions of Turkey. The aim of this study was to evaluate the demographic and clinical characteristics, type of treatment and treatment responses of 117 CL patients. **Material and Methods:** In this study, 117 Syrian CL patients, who applied to the outpatient clinic were presented. **Results:** Sixty two of the patients were female (53%) and 55 (% 47) were male. The mean age of the patients was 16±1,4. Fifty two point one percent of the patients had one, 38.5% had two or three and 9.4% had more than three lesions. The mean duration of the lesions was 7 months, while the average duration of residence time in Turkey was 6 months. Ninety six point six percent of the lesions had a diameter less than 5 cm and the rest had larger lesions. Most of the lesions were localized on the face (43.1%) and extremities (42.8%). The majority of the lesions on the face were at the cheeks (53.8%), one of them was on the eyelid, 2 on the lip, 4 on the ear and 9 on the nose. The patients were treated with intralesional antimony compounds or cryotherapy. Lesions of the patients, who were treated with the antimony compounds recovered faster and with superior cosmetic results. **Conclusion:** Intralesional antimony therapy is an effective and cosmetically successful treatment option without any significant side effects for CL.

Keywords: Leishmaniasis, cutaneous; cryotherapy; injections, intralesional

ÖZET Amaç: Kutanöz layşmanyazis (KL), deride nodulo-ülseratif lezyonlarla seyreden bir hastalıktır. Hastalık, Türkiye'nin bazı bölgeleri ile Suriye'de endemiktir. Bu çalışmanın amacı; kliniğimize başvuran 117 kutanöz layşmanyazis tanılı hastanın demografik ve klinik özelliklerinin, bu hastalara uygulanan tedavi seçeneklerinin ve tedaviye olan yanıtlarının değerlendirilmesidir. **Gereç ve Yöntemler:** Bu çalışmada, dermatoloji polikliniğine başvuran 117 Suriye'li kutanöz layşmanyazis tanılı hasta değerlendirilmiştir. **Bulgular:** Çalışmaya dahil edilen hastaların 62'si kadın (%53), 55'i (%47) erkekti. Hastaların yaş ortalaması 16±1,4 yıl idi. Yüzde 52,1 hastanın tek, %38,5'inin 2 veya 3, %9,4'ünün ise üçten fazla lezyonu vardı. Lezyonların klinik olarak var olma süresi ortalama 7 ay iken, hastaların Türkiye'de ikamet etme sürelerinin ortalama 6 ay olduğu tespit edildi. Lezyon çapının çoğunlukla (%96,6) 5 cm'nin altında olduğu görüldü. Lezyonların çoğunluğu yüz (%43,1) ve ekstremitelerde (%42,8) yerleşmişti. Yüzdeki lezyonların çoğunluğu yanak yerleşimli iken (%53,8), kalan lezyonların bir tanesi göz kapağı, 2 tanesi dudak, 4'ü kulak ve 9 tanesi ise burun yerleşmişti. Hastalar intralezyonel (İL) antimon bileşikleri veya kriyoterapi ile tedavi edildi. İL antimon bileşikleri ile tedavi edilen hastaların daha hızlı ve daha iyi kozmetik sonuçlarla iyileştiği görüldü. **Sonuç:** Kutanöz layşmanyazis'te İL antimon tedavisi önemli yan etkileri olmayan, kozmetik olarak başarılı ve etkili bir tedavi yöntemidir.

Anahtar Kelimeler: Leşmanyazis, kutanöz; kriyoterapi; enjeksiyonlar, intralezyoner

Cutaneous leishmaniasis (CL) is a skin disease which is caused by the protozoan parasites of the genus *Leishmania*. It causes lesions mostly in the skin and sometimes in the mucosa and heals leaving atrophic scars.¹

As it is known, a civil war started in Syria in 2011 which caused migration of a huge amount of people to neighboring countries. Approximately 3 million of these immigrants migrated to Turkey.²

After this intensive wave of immigration, in several studies, it is reported that CL cases were increased in both endemic and non-endemic regions of Turkey.³⁻⁸

An outpatient department specific for Syrian leishmaniasis patients was opened in our clinic in parallel with the increased number of immigrants in Ankara.

In this study, the demographic and clinical characteristics, type of treatment and treatment responses of 117 CL patients were evaluated.

MATERIAL AND METHODS

One hundred and seventeen CL patients, who applied to the outpatient department were included in the study. The data was gathered by evaluating the records of the patients retrospectively. An approval from the local ethics committee was obtained for the study (05.04.2017, 3/34). The study was planned according to the Helsinki Declaration principles. All of the patients were informed about their treatments and a patient consent form was filled for each patient. The patients were evaluated in terms of age, sex, number of lesions, lesion duration, diameter of lesions, duration of residence in Turkey, previous treatments, treatments applied in our clinic and their results.

Statistical analyses were carried out using SPSS 15.0, the statistical software package for Windows (SPSS Inc., Chicago, IL, USA). The normal distribution of the data was assessed using the Kolmogorov-Smirnov test. Continuous and normally distributed variables were presented as means \pm standard deviations and intra-group differences were investigated using the Student's t-test. Continuous variables with non-normal distribution were expressed as medians (minimum-maximum), and differences between variables were analyzed using the Mann-Whitney U test. Categorical variables were expressed in percentages.

RESULTS

Out of 117 patients enrolled in the study, 62 were female (%53) and 55 (%47) were male. The mean age of the patients was $16 \pm 1,4$ (2-67 years). Fifty

two point one percent of the patients had one, 38.5 % had two or three, 9.4% had more than three lesions. The mean duration of the lesions was 7 months, while the average duration of residence time in Turkey was 6 months. Ninety six point six percent of the lesions had a diameter less than 5 cm and the rest had larger lesions. Most of the lesions were located on the face (43.1%) and extremities (42.8%). The majority of the lesions on the face were at the cheeks (53.8%), one of them was on the eyelid, 2 on the lip, 4 on the ear and 9 on the nose. Most of the lesions were in form of papules and plaques. Some of the lesions were encrusted. Seven patients had nodular and 20 patients had ulcerated lesions.

Giemsa-stained smears were evaluated from all of the patients, but only 60 of them (51,2%) had a positive smear. As all patients were migrated from the endemic regions and had typical lesions and clinical findings, a topical treatment was initiated to all of the suitable patients without taking into consideration of the smear results.

Forty nine point six percent of the applicants were previously unsuccessfully treated in Syria and 50.4% of them had received no treatment. In Syria 83.6% of them received topical and 16.4% received systemic treatment with systemic antimone compounds.

We carried out only intralesional (IL) treatment in 52 patients, only cryotherapy in 60 patients and combination therapy (cryotherapy plus IL treatment) in 5 patients in regard to the localization and number of the lesions. Intralesional treatment was carried out twice a week with 5-6 injections in total in each course. The drug was given until the lesions got completely whitened in order to reach an efficient dosage. Cryotherapy was carried out once in every 3 weeks. Thirty eight of the 57 patients who received IL treatment, were cured by 1 course, 15 by 2 and 4 by 3 courses of treatment. Three of the 65 patients; who received cryotherapy, were cured by 1 course, 59 by 2-3 courses and the remaining patients by 4, 5 or 6 courses. Lesions of all patients were completely cured.

DISCUSSION

Cutaneous leishmaniasis is an infectious disease which is transmitted to humans and other mammals by the infected sandflies.² The disease is hyperendemic in some regions. Syria is one of the hyperendemic countries for CL in the world.⁹

In this study, 117 CL patients who applied to the outpatient clinic were evaluated.

In the studies conducted in Turkey after the beginning of the civil war, it was found out that more than 50 % of the patients were younger than 20 years.^{4-6,8} Consistent with the literature, most of the patients in this study were children and young adults. This finding suggests inadequate hygiene practices among these age groups especially due to the war conditions, higher exposure to the sandfly bites due to their higher stay in rural areas and spending more time outdoors and low immunity due to lack of exposure with the cause of the disease.

Similar with recent studies, the ratio of the female patients were higher than the male patients in this study.^{4-6,8} The reason for this result might be the relatively higher loss of the males under the war conditions, and the remaining staying of the males in their home country as fighters.

The mean duration of the lesions was 7 months while the duration of patients' residence in Turkey was 6 months. This finding, as it was in line with the incubation time of the *L major* (2-8 months), which was the most frequent causative agent of CL in Syria, enabled us to diagnose the disease relatively easier and was considered as a proof that the transmission occurred in Syria.¹⁰

In a recent study, it was found that the average number of the lesions were 2 in Turkish patients and 3 in Syrian patients. They suggested that the higher number of lesions in Syrian patients depends on multiple bites by sandfly vector due to unprotected tent camps.⁸ In the studies focused on a large number of CL patients from Syria and the world before the start of the war, one or two lesions per patients were usually reported.¹¹⁻¹³ In the

present study, the reasons for the high number of the patients with multiple lesions might be the unfavorable living conditions of the immigrants and difficulties to access to essential therapy.

The head and neck region and also the upper extremities were determined to be the most frequent areas of the lesions in the previous studies.³⁻⁸ Consistent with these findings, the majority of the lesions were located on the face and extremities in our patients. This finding was not a surprise, as the sandfly could easily bite the uncovered areas of the body at nighttime. In the previous studies, it was reported that the number of the ulcerated lesions were higher especially in the Syrian patients.^{8,10-14} In contrary to this data, most of the lesions in this study were papules and plaques.

The pentavalent antimony compounds are the first choice of treatment in the world and also in our country (meglumine antimoniate-Glucantime®; sodium stibogluconate-Pentostam®). Other and less preferred treatment alternatives for the disease are amphotericin B, pentamidine, allopurinol, dapsone, itraconazole, ketoconazole and terbinafine.⁹ Meglumine antimoniate is available in our country and it is provided free of charge by the local health authority for all reported patients. Intralesional antimony therapy is a treatment option which enables good cosmetic results without any significant side effect and with low risk of relapse.^{15,16} Besides these, there are also other several physical treatments among the local treatment options of which the most common one is cryotherapy.^{9,16}

We used either IL antimony compounds or cryotherapy in our patients. The lesions of the patients, treated with the IL injections, recovered faster, with fewer treatment courses and better cosmetic results when compared with the cryotherapy group. We believed that the reasons for the treatment failure in patients, who were previously treated with IL or cryotherapy, were the inadequate dose and duration of the treatment due to the war conditions, difficulty of application to a health center and difficulties to access the medication and poor hygiene.

We found out that the lesions located in the eyelid, nose, ear and lips, which are usually treated with systemic medication, did not recover in 16 patients, although they were previously treated in Syria with systemic antimony compounds. World Health Organization recommends the intramuscular antimony treatment (20mg/kg/day for 20 days) in patients, having more than 5 lesions and in lesions localized in the cartilage and mucosa.¹⁵ In a few studies, it was reported that IL treatment with antimony compounds provided good clinical results without side effects in CL patients with lesions localized on eyelids and lips.^{15,17,18} Several studies showed that IL treatment had many advantages such as avoidance from the systemic side effects, achievement of high concentrations of the medication in the lesions, fast and good response to the treatment, cost-effectiveness and achievement of better cosmetic results.¹⁵ Yaghoobi et al. conducted a study with 9 CL patients, with lesions in the eyelids, and they reported that injections could be easily administered due to the thin skin in this area. They concluded that excellent cosmetic results and recovery without complications could be achieved with IL treatment.¹⁸ Durdu et al. presented the results of 59 CL patients, who had periocular lesions. They reported that 50 of these patients received IL treatment, 2 of them cryotherapy, 2 patients a combination of IL and cryotherapy, and 5 patients received systemic antimony treatment. Four patients, who underwent cryotherapy, had initially a fast recovery. But as early relapse was observed, the treatment was switched to IL treatment. They concluded that although the rates of efficacy were comparable, IL treatment had less side effects than the systemic treatment.¹⁹ In this study, we decided to apply IL treatment in 16 patients, depending on the good results in the previous studies, who had lesions localized on the eyelid, mucosa and cartilage and did not respond to the previous systemic treatment. All of the patients were cured in a short time with excellent cosmetic results and without any side effect or complication. None of the patients relapsed (Figures 1, 2). The patients benefited from the IL treatment, although they were previously treated with systemic treatment. We consid-

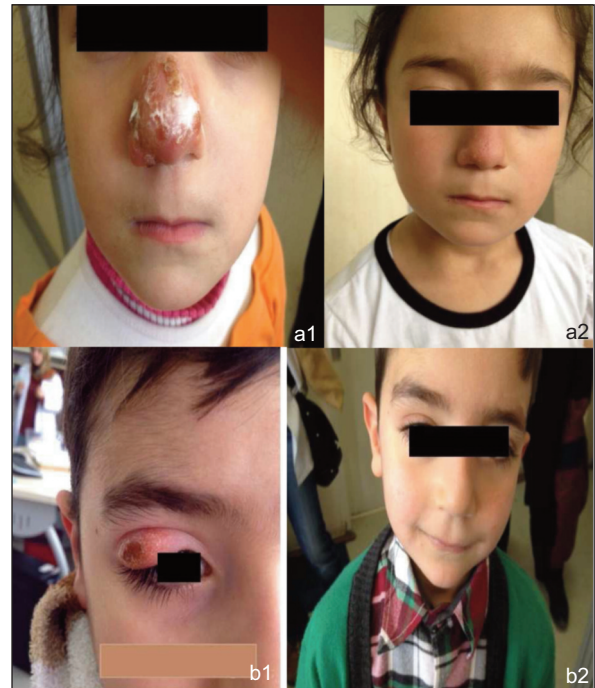

FIGURE 1-2: The images of the patients before (a) and after (b) the intraleSIONal treatment.

ered this as a significant and remarkable finding. We believed that the reasons for the treatment failure in patients, who were previously treated with systemic treatment, were the inadequate dose and treatment duration due to the war conditions, or the possible resistance to the antimony compounds.

CONCLUSION

The successful treatment results detected in the present study supports that IL treatment is a good and confidential choice in the management of the lesions localized on the eyelid, nose, ears and lips, which are usually recommended to be treated with systemic agents. This finding was in consistent with the results of the limited number of studies in the literature.^{15,17,18}

In this study, we found out that IL treatment was superior to the cryotherapy in CL. It was confirmed once more that IL treatment should be the first choice among the topical treatments. We recommend IL treatment as the first choice treatment option particularly on the face lesions in favor of good cosmetic results and fast response to the treatment.

Acknowledgements

There was no funding sources that supported the work.

Source of Finance

During this study, no financial or spiritual support was received neither from any pharmaceutical company that has a direct connection with the research subject, nor from a company that provides or produces medical instruments and materials which may negatively affect the evaluation process of this study.

Conflict of Interest

No conflicts of interest between the authors and / or family members of the scientific and medical committee members or members of the potential conflicts of interest, counseling, expertise, working conditions, share holding and similar situations in any firm.

Authorship Contributions

Idea/Concept: Nermin Karaosmanoğlu, Muzaffer Şahin, Güler Vahaboğlu, Gülfer Akbay, Emine Yalçın Edgüer, Tijen Şahin, Fatma Efsun Tanaçan, Hatice Meral Ekşioğlu, Ali Kudret Adiloğlu; **Design:** Nermin Karaosmanoğlu, Muzaffer Şahin, Güler Vahaboğlu, Gülfer Akbay, Emine Yalçın Edgüer, Tijen Şahin, Fatma Efsun Tanaçan, Hatice Meral Ekşioğlu, Ali Kudret Adiloğlu; **Control/Supervision:** Nermin Karaosmanoğlu, Muzaffer Şahin, Güler Vahaboğlu, Gülfer Akbay, Emine Yalçın Edgüer, Tijen Şahin, Fatma Efsun Tanaçan, Hatice Meral Ekşioğlu; **Data Collection and/or Processing:** Nermin Karaosmanoğlu, Muzaffer Şahin, Güler Vahaboğlu, Gülfer Akbay, Emine Yalçın Edgüer, Tijen Şahin, Fatma Efsun Tanaçan, Hatice Meral Ekşioğlu; **Analysis and/or Interpretation:** Nermin Karaosmanoğlu, Muzaffer Şahin, Güler Vahaboğlu, Gülfer Akbay, Emine Yalçın Edgüer, Tijen Şahin, Fatma Efsun Tanaçan, Hatice Meral Ekşioğlu, Ali Kudret Adiloğlu; **Literature Review:** Nermin Karaosmanoğlu, Muzaffer Şahin, Güler Vahaboğlu, Gülfer Akbay, Emine Yalçın Edgüer, Tijen Şahin, Fatma Efsun Tanaçan, Hatice Meral Ekşioğlu; **Writing the Article:** Nermin Karaosmanoğlu, Ali Kudret Adiloğlu, Hatice Meral Ekşioğlu; **Critical Review:** Nermin Karaosmanoğlu, Muzaffer Şahin, Güler Vahaboğlu, Gülfer Akbay, Emine Yalçın Edgüer, Tijen Şahin, Fatma Efsun Tanaçan, Hatice Meral Ekşioğlu, Ali Kudret Adiloğlu; **References and Fundings:** Nermin Karaosmanoğlu, Muzaffer Şahin, Güler Vahaboğlu, Gülfer Akbay, Emine Yalçın Edgüer, Tijen Şahin, Fatma Efsun Tanaçan, Hatice Meral Ekşioğlu, Ali Kudret Adiloğlu; **Materials:** Nermin Karaosmanoğlu, Muzaffer Şahin, Güler Vahaboğlu, Gülfer Akbay, Emine Yalçın Edgüer, Tijen Şahin, Fatma Efsun Tanaçan, Hatice Meral Ekşioğlu, Ali Kudret Adiloğlu.

REFERENCES

- Çulha C, Akçalı C. [Detection of Cutaneous Leishmaniasis Cases in Hatay and Surrounding Areas]. *Acta Parasitologica Turcica*. 2006;30(4):268-71.
- Mockenhaupt FP, Barbre KA, Jensenius M, Larsen CS, Barnett ED, Stauffer W, et al. Profile of illness in Syrian refugees: a geosentinel analysis, 2013 to 2015. *Euro Surveill*. 2016;21(10):30160. [Crossref] [PubMed]
- Özkeklikçi A, Karakuş M, Özbel Y, Töz S. The new situation of cutaneous leishmaniasis after Syrian civil war in Gaziantep city, southeastern region of Turkey. *Acta Trop*. 2017;166:35-8. [Crossref] [PubMed]
- Inci R, Öztürk P, Mulaşım MK, Özyurt K, Alatas ET, İnci MF. Effect of the Syrian civil war on prevalence of cutaneous leishmaniasis in southeastern Anatolia, Turkey. *Med Sci Monit*. 2015;21:2100-4. [Crossref] [PubMed] [PMC]
- Salman IS, Vural A, Ünver A, Saçar S. [Cutaneous leishmaniasis cases in Nizip, Turkey after the Syrian civil war]. *Mikrobiyol Bul*. 2014;48(1):106-13.
- Korkmaz S, Özgöztaşı O, Kayıran N. [The assessment of cutaneous leishmaniasis patients admitting to Gaziantep University of Medicine Faculty diagnosis and treatment center]. *Türkiye Parazitol Derg*. 2015;39(1):13-6. [Crossref] [PubMed]
- Turhanoglu M, Alp Erdal S, Bayındır Bilman F. [A nine-year evaluation of cutaneous leishmaniasis patients in Diyarbakır Training and Research Hospital, Turkey]. *Mikrobiyol Bul*. 2014;48(2):335-40. [Crossref] [PubMed]
- Turan E, Yeşilova Y, Sürücü HA, Ardic N, Doni N, Aksoy M, et al. A comparison of demographic and clinic characteristics of Syrian and Turkish patients with cutaneous leishmaniasis. *Am J Trop Med Hyg*. 2015;93(3):559-63. [Crossref] [PubMed] [PMC]
- Uzun S. [Leishmaniasis]. Tüzün Y, Güner MA, Serdaroğlu S, Oğuz O, Aksungur VL, editörler. *Dermatoloji*. 3. Baskı. İstanbul: Nobel Tıp Kitabevleri; 2008. p.659-82.
- World Health Organization (WHO). Control of leishmaniasis. Report of a meeting of the WHO Expert Committee on the control of leishmaniasis. Geneva: WHO Press; 2010. p.185. Series, 949. Available at: [Link]
- Al-Tawfiq JA, AbuKhamis A. Cutaneous leishmaniasis: a 46-year study of the epidemiology and clinical features in Saudi Arabia (1956-2002). *Int J Infect Dis*. 2004;8(4):244-50. [Crossref] [PubMed]
- Zaraa I, Ishak F, Kort R, El Euch D, Mokni M, Chaker E, et al. Childhood and adult cutaneous leishmaniasis in Tunisia. *Int J Dermatol*. 2010;49(7):790-3. [Crossref] [PubMed]
- Douba M, Mowakeh A, Wali A. Current status of cutaneous leishmaniasis in Aleppo, Syrian Arab Republic. *Bull World Health Organ*. 1997;75(3):253-9.
- Yemisen M, Ulas Y, Celik H, Aksoy N. Epidemiological and clinical characteristics of 7172 patients with cutaneous leishmaniasis in Sanliurfa, between 2001 and 2008. *Int J Dermatol*. 2012;51(3):300-4. [Crossref] [PubMed]
- Uzun S, Durdu M, Culha G, Allahverdiyev AM, Memisoglu HR. Clinical features, epidemiology, and efficacy and safety of intralesional antimony treatment of cutaneous leishmaniasis: recent experience in Turkey. *J Parasitol*. 2004;90(4):853-9. [Crossref] [PubMed]
- Uzun S, Gürel MS, Durdu M, Akyol M, Fettahloğlu Karaman B, Aksoy M, et al. Clinical practice guidelines for the diagnosis and treatment of cutaneous leishmaniasis in Turkey. *Int J Dermatol*. 2018;57(8):973-82. [Crossref] [PubMed]
- Zaraa I, Karoui S, Osman AB. Effectiveness of intralesional meglumine antimoniate in the treatment of mucosal leishmaniasis of the old world. *J Dermatol*. 2012;39(2):201-3. [Crossref] [PubMed]
- Yaghoobi R, Maraghi S, Bagherani N, Rafiei A. Cutaneous leishmaniasis of the lid: a report of nine cases. *Korean J Ophthalmol*. 2010;24(1):40-3. [Crossref] [PubMed] [PMC]
- Durdu M, Gökçe S, Bagirova M, Yalaz M, Allahverdiyev AM, Uzun S. Periocular involvement in cutaneous leishmaniasis. *J Eur Acad Dermatol Venereol*. 2007;21(2):214-8. [Crossref] [PubMed]