





# Coexistence of Central Serous Chorioretinopathy with Sjögren's Syndrome

## Sjögren Sendromu ile Santral Seröz Koryoretinopati Birlikteliği

 Sabit KİMYON,<sup>a</sup>  
 Alper METE,<sup>a</sup>  
 Kıvanç GÜNGÖR,<sup>a</sup>  
 Seda ÇERİ,<sup>a</sup>  
 İffet YARIMAĞAÇ KAÇARLAR<sup>a</sup>

<sup>a</sup>Department of Ophthalmology,  
Gaziantep University Faculty of Medicine,  
Gaziantep

Received: 13.07.2016  
 Received in revised form: 22.11.2016  
 Accepted: 08.12.2016  
 Available online: 24.04.2018

Correspondence:  
 Sabit KİMYON  
 Gaziantep University Faculty of Medicine,  
 Department of Ophthalmology, Gaziantep,  
 TURKEY/TÜRKİYE  
 sabitkimyon@gmail.com

**ABSTRACT** We report a case of central serous chorioretinopathy (CSC) as a presenting pathology in a patient with undiagnosed Sjögren's syndrome (SS). A 46 years-old man admitted to the ophthalmology department with a history of decreased vision in his left eye for a month. Slit-lamp examination revealed punctate epitheliopathy and mucus plaques in both eyes. Fundus examination showed macular edema in the left eye. Fundus fluorescein angiography and optical coherence tomography showed characteristic leakage in the macular area which confirmed the diagnosis of CSC. Patient was consulted to rheumatology department because of the dry eye symptoms. The patient was diagnosed with SS. Autoimmune diseases were reported as risk factors for CSC but to best of our knowledge this is the first case which reported CSC as the presenting pathology of SS. CSC should be added to the list of manifestations of SS.

**Keywords:** Central serous chorioretinopathy; Sjogren's syndrome; autoimmune diseases

**ÖZET** Amacımız santral seröz koryoretinopati (SSK) ile başvuran, daha önce tanı almamış Sjögren sendromlu (SS) olguyu sunmaktır. 46 yaşında erkek hasta son bir aydır sol gözünde görme azlığı şikayeti ile göz hastalıkları bölümüne başvurdu. Biyomikroskopik incelemede her 2 gözde punktat epitelyopati ve mukus plakları saptandı. Fundus muayenesinde sol gözde makula ödemi olduğu görüldü. Fundus florescein anjiyografisi ve optik koherens tomografide SSK tanısını doğrulayan makula bölgesinde karakteristik sızıntı görüldü. Hasta kuru göz semptomları açısından romatoloji bölümüne danışıldı. Hastaya SS tanısı konuldu. Otoimmün hastalıkların SSK için risk faktörü olduğu daha önce bildirilmiştir fakat bizim bildiğimiz kadarıyla bu olgu, SSK'nin SS tanısında ilk bulgu olarak ortaya çıktığı ilk olgudur. SSK, SS bulguları listesine eklenmelidir.

**Anahtar Kelimeler:** Santral seröz koryoretinopati; Sjögren sendromu; otoimmün hastalıklar

Central serous chorioretinopathy (CSC) is characterized by an exudative neurosensory retinal detachment with or without an associated detachment of the retinal pigment epithelium (RPE). It typically affects adult men (20-50y).<sup>1</sup> CSC is associated with type A personalities, psychosocial stress, pregnancy (usually third trimester), Cushing's disease and numerous drugs (especially corticosteroids). There are different theories about the pathophysiology of CSC. Experimental studies have shown serous retinal detachment may be secondary to alteration of choroidal vascular permeability.<sup>2</sup> Another study suggests that ischemia

at the level of the choroid may cause capillary and venous congestion with increased fluid transudation.<sup>1</sup>

Sjogren's syndrome (SS) is a multisystem autoimmune disease characterized by lymphocytic infiltration of exocrine glands and other organs. Many ocular findings of SS were reported in literature but relationship between CSC and SS wasn't enlightened enough yet.

## CASE REPORT

A 46 years-old caucasian man applied to the ophthalmology department of Gaziantep University with a history of decreased vision in his left eye and burning sensation in both eyes for a month. He didn't have another systemic disease and any history of drug use. His best corrected visual acuities (BCVA) were 10/10 and 3/10 in OD and OS, respectively. His intraocular pressures (IOP) were 11 mmHg in the right and 17 mmHg in the left eye. Slit-lamp examination revealed punctate epitheliopathy and mucus plaques in both eyes. Tear film break up times were 6 and 5 seconds, schirmer test results with topical anaesthetic were 4 and 3 mm in the right and left eyes respectively. Fundus examination showed swelling in macula of the left eye and pigmentary changes in the right eye (Figure 1). Optical coherence tomography (OCT) revealed

subretinal fluid in the left eye (Figure 2A). Fundus fluorescein angiography (FFA) showed characteristic leakage in the macular area which confirmed the diagnosis of CSC.

The patient didn't have any known systemic diseases, risk factors like type A personality, psychosocial stress or any history of drug use that may be related to CSC. Patient was consulted to rheumatology department because of the dry eye symptoms. The patient was diagnosed with SS. Rheumatology department started 1 mg colchicine and 10 mg prednisolone treatment. We started artificial tears drops 8 times a day for the dry eye syndrome.

We followed the patient monthly and subretinal fluid gradually decreased at every follow-up (Figure 2). At 10th month visit; his BVCA was 7/10 in the left eye, fundus examination revealed retina pigment epithel atrophy around macula which was consistent with chronic CSC. Subretinal fluid was reduced in OCT, the leakage in the macular area was disappeared in FFA (Figure 3). An informed consent was obtained from the patient for reporting his medical data.

## DISCUSSION

Central serous retinopathy (CSC) is an exudative chorioretinopathy characterized by an exudative

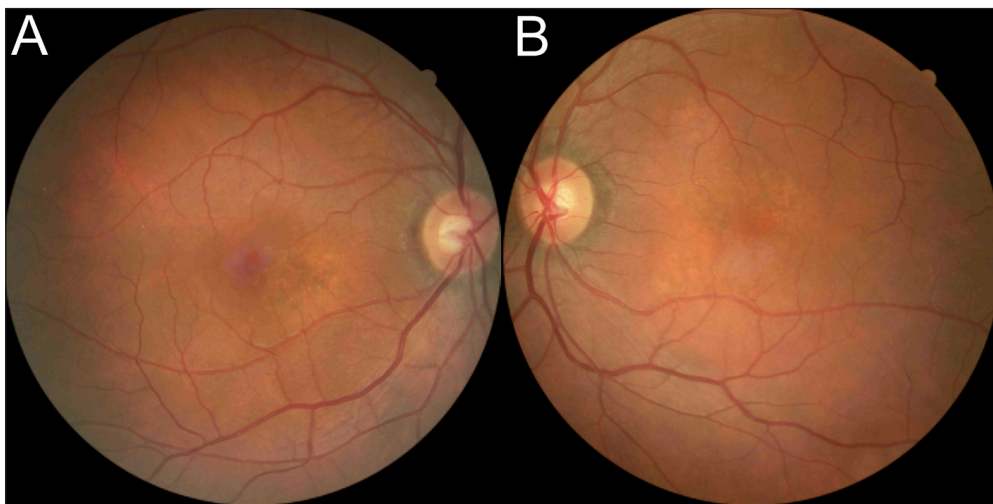
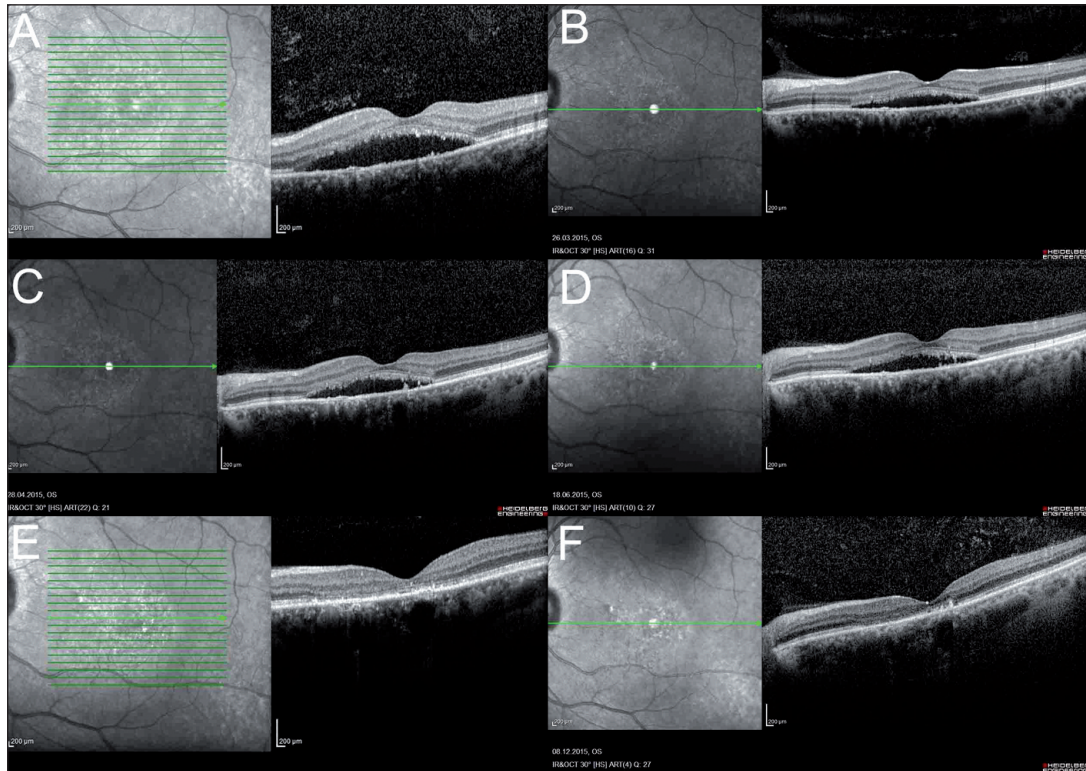
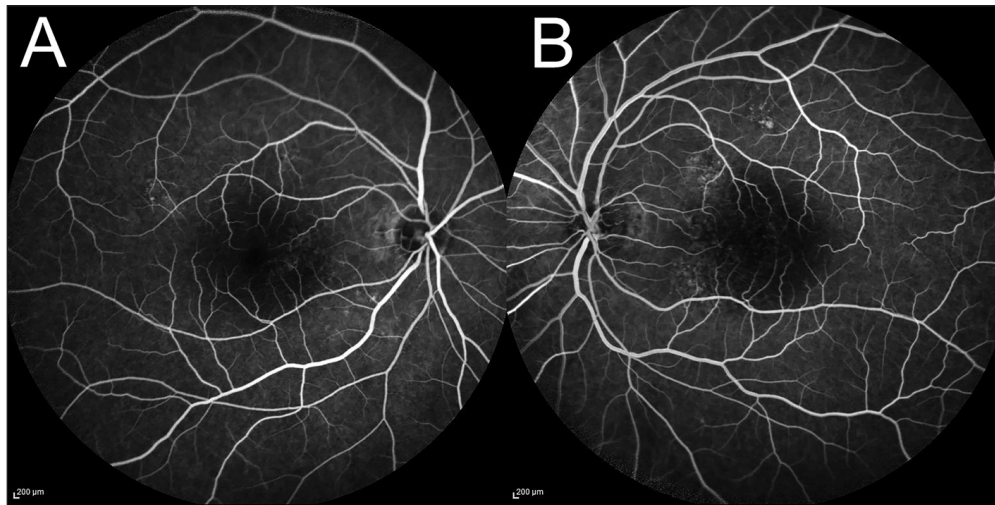


FIGURE 1: Fundus images of right A) and left B) eye.



**FIGURE 2:** Macular optic coherence tomography images of the left eye. **A)** At presentation, **B)** First month follow-up, **C)** Second month follow-up, **D)** Fourth month follow-up, **E-F)** 10<sup>th</sup> month follow-up.



**FIGURE 3:** Fundus fluorescein angiography of right **A)** and left **B)** eyes at 10<sup>th</sup> month follow-up.

neurosensory retinal detachment with or without an associated detachment of the RPE.

CSC is associated with diabetes, allergic respiratory distress, type A personality, psy-

chosocial stress, pregnancy, Cushing's disease, corticosteroid use, antihistamine use, smoking and alcohol use.<sup>2,3</sup> Other studies reported that hypertension, *Helicobacter pylori* infection, sleep-

ing disturbance, psychopharmacologic medication use, gastroesophageal reflux disease, peptic ulcer, antacids, antireflux agents and autoimmune diseases are risk factors for CSC.<sup>4</sup> Patients with autoimmune diseases usually use corticosteroid treatments so it is hard to tell if the CSC is resulted from the disease itself or the treatment. Our patient was diagnosed after he presented with CSC and he wasn't using any medication which strengthens the possible relation of CSC with SS.

Sjögren's syndrome is a multisystem autoimmune disease characterized by lymphocytic infiltration of exocrine glands and other organs. Lacrimal and salivary gland involvement results in dry eye and dry mouth which are hallmark features of the disease.<sup>5</sup>

Extraglandular ocular manifestations, such as sterile corneal necrosis, uveitis and scleritis<sup>9</sup> have been reported to occur in SS particularly as a presenting symptom in previously undiagnosed SS patients but there isn't any information in the literature about CSC.<sup>6-8</sup> To our knowledge this is the first case which reports CSC as a presenting symptom of SS. Vision-threatening ocular manifestations of primary Sjögren's syndrome have been reported and these manifestations are; corneal haze, sterile corneal ulcer or infiltration, corneal melt or perforation, papillary conjunctivitis, follicular conjunctivitis, cicatrizing conjunctivitis, uveitis, episcleritis, scleritis, optic neuropathy or neuritis, orbital inflammation and retinal vasculitis.<sup>9</sup>

In literature there are studies about ocular findings in SS but there isn't any information about CSC.<sup>10</sup> Autoimmune diseases were reported as risk factors for CSC but to our knowledge this is the first case which reported coexistence of CSC with SS. In some cases, CSC could be a presenting finding of SS, more cases are needed to support this theory.

#### **Acknowledgements**

*We do not have someone to acknowledge.*

#### **Source of Finance**

*During this study, no financial or spiritual support was received neither from any pharmaceutical company that has a direct connection with the research subject, nor from a company that provides or produces medical instruments and materials which may negatively affect the evaluation process of this study.*

#### **Conflict of Interest**

*No conflicts of interest between the authors and / or family members of the scientific and medical committee members or members of the potential conflicts of interest, counseling, expertise, working conditions, share holding and similar situations in any firm.*

#### **Authorship Contributions**

**Idea/Concept:** Sabit Kimyon, Alper Mete, Kıvanç Güngör; **Design:** Sabit Kimyon, Alper Mete, Kıvanç Güngör; **Control/Supervision:** Kıvanç Güngör; **Data Collection and/or Processing:** Seda Çeri, İffet Yarınmağa Kaçarlar; **Analysis and/or Interpretation:** Sabit Kimyon, Alper Mete, Kıvanç Güngör; **Literature Review:** Sabit Kimyon, Alper Mete; **Writing the Article:** Sabit Kimyon, Alper Mete; **Critical Review:** Kıvanç Güngör.

## REFERENCES

1. Haimovici R, Koh S, Gagnon DR, Lehrfeld T, Wellik S; Central Serous Chorioretinopathy Case-Control Study Group. Risk factors for central serous chorioretinopathy: a case-control study. *Ophthalmology* 2004;111(2):244-9.
2. Islam QU, Hanif MK, Tareen S. Frequency of Systemic Risk Factors in Central Serous Chorioretinopathy. *J Coll Physicians Surg Pak* 2016;26(8):692-5.
3. Chon CH, Yao XY, Dalal R, Takeuchi A, Kim RY, Marmor MF. An experimental model of retinal pigment epithelial and neurosensory serous detachment. *Retina* 1996;16(2):139-44.
4. Liu B, Deng T, Zhang J. Risk factors for central serous chorioretinopathy: a systematic review and meta-analysis. *Retina* 2016;36(1):9-19.
5. Prünke C, Flammer J. Choroidal capillary and venous congestion in central serous chorioretinopathy. *Am J Ophthalmol* 1996;121(1):26-34.
6. Shan SJ, Wu EI, Akpek EK. Sterile corneal melt after descemet stripping endothelial keratoplasty in patients with previously undiagnosed Sjogren syndrome. *Arch Ophthalmol* 2009;127(2):219-20.
7. Ou JI, Manche EE. Corneal perforation after conductive keratoplasty in a patient with previously undiagnosed Sjögren syndrome. *Arch Ophthalmol* 2007;125(8):1131-2.
8. Bridges AJ, Burns RP. Acute iritis associated with primary Sjögren's syndrome and high-titer anti-SS-A/Ro and anti-SS-B/La antibodies. Treatment with combination immunosuppressive therapy. *Arthritis Rheum* 1992;35(5):560-3.
9. Choi W, Lee SS, Park YG, Yoon KC. A case of necrotizing keratoscleritis in primary Sjogren's syndrome. *Korean J Ophthalmol* 2011;25(4):275-7.
10. Akpek EK, Mathews P, Hahn S, Hessen M, Kim J, Grader-Beck T, et al. Ocular and systemic morbidity in a longitudinal cohort of Sjögren's syndrome. *Ophthalmology* 2015;122(1):56-61.