

A Fatal Case of Pyoderma Gangrenosum with Multiple Organ System Involvement: Unexpected Progression: Case Report

Çoklu Organ Tutulumu ile Seyreden Ölümcül Bir Piyoderma Gangrenosum Olgusu: Beklenmeyen Bir Seyir

Suzan D. PEKTAŞ,^a
Neriman D. ALTINTAŞ,^b
Seval İZDEŞ,^c
Sibel YÜCEL,^d
Hayriye T. DOĞAN^e

^aClinic of Dermatology,
Aydın State Hospital, Aydın
^bUnit of Medical Intensive Care,
Ankara University Faculty of Medicine,
^cDepartment of Anesthesiology and
Reanimation,
Yıldırım Beyazıt University
Faculty of Medicine,
Clinics of
^dAnesthesiology and Reanimation,
^ePathology,
Ankara Atatürk Training and
Research Hospital, Ankara

Geliş Tarihi/Received: 17.10.2014
Kabul Tarihi/Accepted: 02.04.2015

*This case report was presented as a poster at
Congress of 16. National Intensive Care,
25-29 April 2012, Antalya, Turkey,*

Yazışma Adresi/Correspondence:
Seval İZDEŞ
Yıldırım Beyazıt University
Faculty of Medicine,
Department of Anesthesiology and
Reanimation, Ankara,
TÜRKİYE/TURKEY
sevalizdes@yahoo.com

doi: 10.5336/dermato.2014-42106

Copyright © 2015 by Türkiye Klinikleri

ABSTRACT Pyoderma gangrenosum (PG) is a neutrophilic dermatosis characterized by skin lesions that begin as nodules and rapidly progress to necrotic ulcers. In some patients PG can exhibit extracutaneous organ involvement. Herein we present a 54-year-old male patient who presented with aphasia and headache. Computed tomography documented cerebellar abscess, which was subsequently drained and shown to be sterile. He was being followed with PG and this was accepted as cerebellar involvement. His case demonstrated a very extensive involvement of PG including the central nervous system, lungs, liver, and spleen. PG in this rare case of multiple organ system involvement had a very aggressive course, despite resection of an in-situ colonic adenocarcinoma.

Key Words: Skin diseases, eczematous; brain abscess; medical oncology

ÖZET Piyoderma gangrenosum (PG), nodüllerle başlayıp hızla nekrotik ülserlere dötüşen cilt lezyonları ile karakterize, nötrofilik bir dermatozdur. Bazı PG'li hastalarda, cilt dışındaki diğer organlarda da tutulum görülebilir. Bu yazıda baş ağrısı ve afazi ile başvuran 54 yaşındaki bir erkek hasta sunulmaktadır. Bilgisayarlı tomografide serebellar abse saptanmış olup, drene edilmiş ve steril olduğu gösterilmiştir. Hasta PG tanısı ile izlenmekte olup, bu tablo serebellar tutulum olarak kabul edilmiştir. Hastamız, santral sinir sistemi, akciğerler, karaciğer ve dalak tutulumu ile seyreden oldukça yaygın bir PG olgusudur. Nadir görülen bu çoklu organ tutulumu tablosunda in-situ kolon adenokarsinom rezeksiyonuna rağmen, PG oldukça agresif seyretmiş ve hasta kaybedilmiştir.

Anahtar Kelimeler: Deri hastalıkları, ekzematöz; beyin apsesi; tıbbi onkoloji

Türkiye Klinikleri J Dermatol 2015;25(2):67-70

Poderma gangrenosum (PG) is a neutrophilic dermatosis of unknown etiology characterized by recurrent ulcers.^{1,2} In rare cases extracutaneous organ involvement occurs.³⁻⁵ Herein we report a case of PG with a higher than usual number of involved organ systems that died due to central nervous system (CNS) involvement.

CASE REPORT

A 54-year-old male patient, with a diagnosis of PG with systemic involvement for the last 2 years, presented with aphasia and headache. He had been diagnosed with PG upon presentation with typical lesions and subsequent skin biopsy. At the time of diagnosis, search for an underlying malignancy had revealed lung, liver, and splenic nodules upon imaging via computed to-

mography (CT) (Figure 1a and 1b). Biopsy of the liver nodules had showed granulomatous inflammation (Figure 1c). Microbiological studies and studies for collagen vascular diseases and vasculitis were negative. Work-up for an underlying malignancy showed that the patient had 2 colonic polyps, which were removed and reported as carcinoma in situ. The patient had been using prednisolone $1 \text{ mg}\cdot\text{kg}^{-1}\cdot\text{d}^{-1}$ for PG during the previous year and the dose had gradually been decreased during the last months.

On physical examination, multiple hypopigmented patchy lesions (5-10 cm) were observed and skin biopsy findings were compatible with postinflammatory hypopigmentation. Active skin lesions, organomegaly, and lymphadenopathy were not observed. Mild leukocytosis, anemia, and an elevated erythrocyte sedimentation rate and C-reactive protein level were noted. Cranial CT showed a

lesion compatible with an abscess in the right cerebellar hemisphere. Metronidazole and ceftriaxone for a possible infection and dexamethasone 4 mg qid for brain edema were administered. Abscess drainage was performed and the culture was negative for bacterial growth. On 25th day of admission, a cranial MRI was performed because of deterioration of neurological findings and it revealed persistent abscess (Figure 1d).

The patient underwent a second surgery for abscess drainage, and histopathological examination of the material revealed necrotizing granulomatous inflammation (Figure 1e). Steroid doses were decreased with the possibility of an undiagnosed atypical infection, since the lesions were progressing under steroid therapy. The patient improved after 6 weeks of antibiotherapy. However two months later, the patient presented with fever and seizures. Microbiological studies were

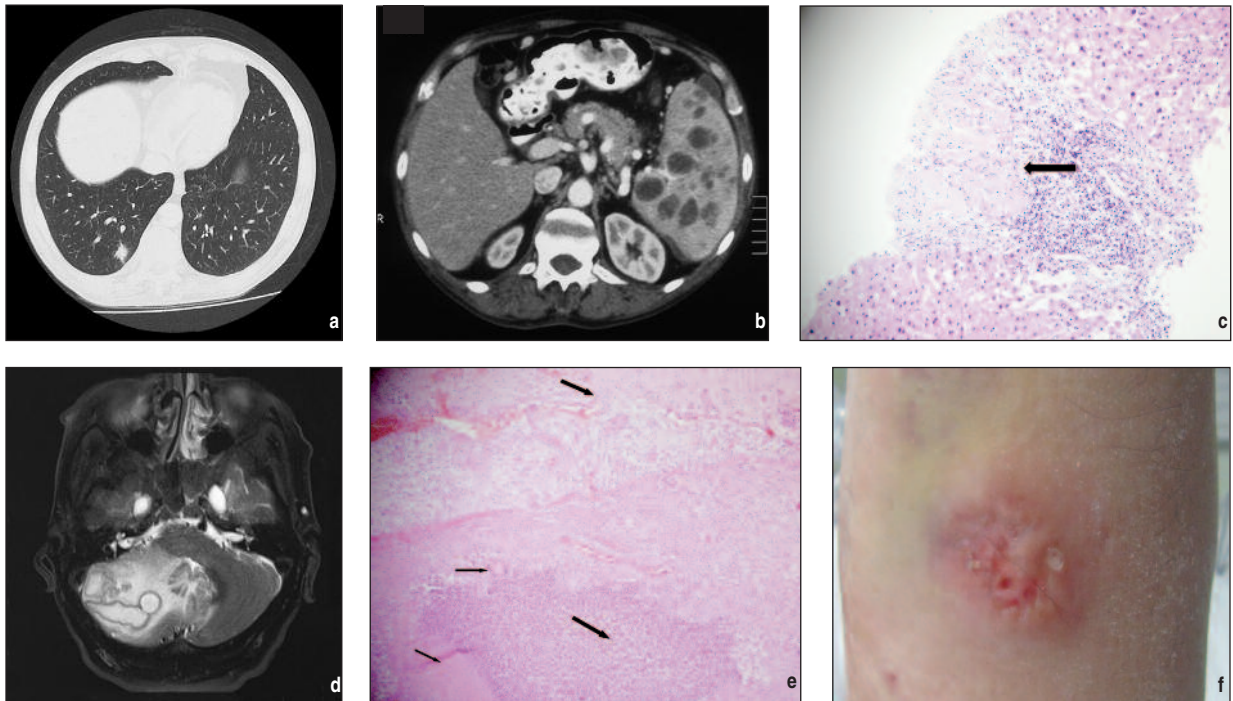


FIGURE 1a: Thoracic CT shows multiple millimetric nodules in the lungs, some of which are cavitating, and multiple enlarged lymph nodes (maximum: 18x13 mm). The largest nodule was 1.5 cm in diameter and surrounded by ground glass density at the posterobasal of the lower lobe of the right lung. **b.** Abdominal CT shows liver nodules (maximum: 27x22 mm) and multiple hypodense splenic parenchymal nodules with peripheral contrast enhancement (maximum: 6x4 cm). **c.** Liver biopsy shows granulomatous inflammation (H&E, 10x). **d.** Cranial MRI shows right cerebellar abscess (37 mmx23mm). **e.** Cerebellar biopsy shows granuloma (left upper narrow arrow) formation with necrosis (left lower narrow arrow) in the abscess region (right lower thick arrow) and glial tissue (right upper thick arrow) (H&E, 10x). **f.** A new ulcerating skin lesion on the forearm with undermined borders and a peripheral erythematous zone.

(See color figure at <http://www.turkiyeklinikleri.com/journal/dermatoloji-dergisi/1300-0330/>)

unrevealing. Serum IgA, IgM, IgG levels, ANA, C3, C4, rheumatoid factor, anti-neutrophilic cytoplasmic antibodies (p-ANCA, c-ANCA), antiphospholipid antibodies, cryoglobulin, levels were negative. On the third week of admission, the patient was intubated due to acute respiratory failure related to worsening of neurological condition. Subsequently, new skin lesions were observed in the antecubital areas, wrists and dorsums of the hands of the patient where injections were made by a 22 gauge needle (pathergy positivity) (Figure 1f). The lesions on skin began as papules, and gradually progressed first to fluctuating, pink to violet lesions than to ulcerovegetative lesions with hemorrhagic crusts. Histopathological examination of these lesions, to confirm diagnosis, showed neutrophilic infiltration compatible with PG. High dose steroids were started. Follow-up CT revealed acute hydrocephalus; an external drainage system was put in place, but the patient died 1 week later. Informed consent to present this case was obtained from the patient's relatives.

DISCUSSION

In the presented case PG involved multiple organ systems and had an extremely aggressive course which led to death of the patient despite resection of the tumor and steroid treatment. This case is unique in that he exhibits one of the widest range of organ systems involved among the reported cases of PG.

PG is diagnosed based on the presence of characteristic skin lesions that begin as nodules or pustules and rapidly ulcerate. Histopathological examination shows non-specific, neutrophilic infiltration involving the epidermis, dermis, and subcutaneous tissue.^{1,2} It should be documented that these abscesses are sterile. Almost 50% of all PG patients have an underlying disease, the activity of which may affect the severity of PG.^{1,2,6,7} PG is expected to improve once anti-inflammatory treatment is initiated along with treatment of any underlying disease if present.^{8,9} Some studies report rapid remission of PG in response to treatment

with steroids, and immunosuppressive treatment is suggested for refractory cases.^{1,8,9}

Although rare, systemic involvement of PG has been reported.^{1,2,4,5,8} PG has been reported with CNS involvement as aseptic meningitis, brain abscess, and hypophyseal involvement, with respiratory system involvement as cavitating nodules, and in association with hepatic and splenic sterile abscesses, osteomyelitis, and peripheral ulcerative keratitis. Extracutaneous involvement may be present at the onset of skin lesions or may precede or follow.^{9,10} In fact, Brown et al have recommended that PG should be regarded as a systemic disease that may involve the skin.⁹ Extracutaneous involvement is commonly associated with underlying illnesses. Importantly lung involvement has been reported to be associated with hematological malignancies in the literature whereas none could be demonstrated in our patient.¹⁰

Mortality due to PG is rare and is generally due to an underlying disease or the side-effects of immunosuppressive drugs.² Urano et al. reported that a patient with meningitis due to PG was cured with steroid therapy.⁸ On admission to the intensive care unite (ICU) our patient was pathergy positive, which is noted in about 30% of patients with PG and this was considered to be indicative of disease activity.^{1,2} The deterioration of his condition was thought to be because of cerebellar abscess and respiratory failure due to PG involvement, despite steroid therapy.

The presented case of PG is notable because of the higher than usual number of extracutaneous organ systems involved. The patient had cerebellar abscess, and cavitating nodules in the lungs, liver, and spleen, in addition to skin ulcers. Although polyps were resected upon diagnosis and steroid treatment was initiated, the patient's condition did not improve. Based on the present case, we think immunosuppressive treatment should be considered early in PG patients with multiple organ involvement in anticipation of an aggressive disease course.

REFERENCES

1. Ruocco E, Sangiuliano S, Gravina AG, Miranda A, Nicoletti G. Pyoderma gangrenosum: an updated review. *J Eur Acad Dermatol Venereol* 2009;23(9):1008-17.
2. Bonamigo RR, Razera F, Olm GS. Neutrophilic dermatoses: part I. *An Bras Dermatol* 2011;86(1):11-25.
3. Cailhol J, Viard JP, Dupont B, Aaron L. [Cutaneous and extracutaneous pyoderma gangrenosum associated with sigmoid adenocarcinoma]. *Gastroenterol Clin Biol* 2003;27(10):955-7.
4. Ahmadi S, Powell FC. Pyoderma gangrenosum: uncommon presentations. *Clin Dermatol* 2005;23(6):612-20.
5. Vignon-Pennamen MD. The extracutaneous involvement in the neutrophilic dermatoses. *Clin Dermatol* 2000;18(3):339-47.
6. França AE, Salvino LK, Leite SH, Ferraz JG, Rocha TD, Cintra ML, et al. Pyoderma gangrenosum as first clinical manifestation of gastric adenocarcinoma. *J Eur Acad Dermatol Venereol* 2006;20(4):440-1.
7. Abdelrazeq AS, Lund JN, Leveson SH. Pouchitis-associated pyoderma gangrenosum following restorative proctocolectomy for ulcerative colitis. *Eur J Gastroenterol Hepatol* 2004;16(10):1057-8.
8. Urano S, Kodama H, Kato K, Nogura K. Pyoderma gangrenosum with systemic involvement. *J Dermatol* 1995;22(7):515-9.
9. Brown TS, Marshall GS, Callen JP. Cavitating pulmonary infiltrate in an adolescent with pyoderma gangrenosum: a rarely recognized extracutaneous manifestation of a neutrophilic dermatosis. *J Am Acad Dermatol* 2000;43(1Pt 1):108-12.
10. Batalla A, Pérez-Pedrosa A, García-Doval I, González-Barcala FJ, Rosón E, de la Torre C. Lung involvement in pyoderma gangrenosum: a case report and review of the literature. *Actas Dermosifiliogr* 2011;102(5):373-7.