

# Multiple Symmetrical Lipomatosis: Co-Morbidity, or Cause?: Case Report

## Multipl Simetrik Lipomatozis: Ko-Morbidite mi Yoksa Sebep midir?

Aylin BİCAN, MD, Msc,<sup>a</sup>  
Gültekin Ozan KÜÇÜK, MD, Msc,<sup>b</sup>  
Akgül ARICI, MD, Msc<sup>c</sup>

Clinics of

<sup>a</sup>Neurology

<sup>b</sup>General Surgery,

Vezirköprü Government Hospital,

Samsun

<sup>c</sup>Department of Pathology,

Uludağ University Faculty of Medicine,  
Bursa

Geliş Tarihi/Received: 12.05.2011

Kabul Tarihi/Accepted: 07.01.2012

Yazışma Adresi/Correspondence:

Aylin BİCAN, MD, Msc

Vezirköprü Government Hospital,

Clinic of Neurology, Samsun,

TÜRKİYE/TURKEY

aylinbican@mynet.com

**ABSTRACT** Multiple symmetric lipomatosis (also known as Madelung's disease, Launois-Bensaude syndrome, MSL) is a rare disease, the etiology of which is unknown. It is generally seen in middle-aged males with a history of alcohol dependence. Disease is characterized by multiple symmetric accumulations of nonencapsulated adipose tissue on the face, neck, upper trunk and other body regions, which are(/is) unrelated to obesity. MSL is frequently accompanied by diabetes, liver diseases, hypothyroidism and polyneuropathy of unknown origin, there are also published reports about central neurological diseases in patients with MSL. We describe two unusual cases (32 and 41-year-old) of MSL who presented with cerebral palsy because of hyperbilirubinemia. Paused lipolysis, a lipid metabolism disorder triggered by catecholamines and functional denervation of adipose tissue are thought to be the etiologic reasons. There are also a number of unresolved issues regarding the neurobiology of MSL and clinical definition together with the cases as noted in this paper. The unknown underlying mechanism could be more clear in the future with the accumulation of data, in the literature.

**Key Words:** Lipomatosis, multiple symmetrical; cerebral palsy

**ÖZET** Multipl simetrik lipomatozis (Madelung ya da Launois-Bensaude hastalığı, MSL olarak da bilinir) oldukça nadir görülen kesin etyopatogenezi bilinmeyen bir hastalıktır. Genellikle hastalar orta yaşlı, alkol bağımlılığı öyküsü olan erkek olgulardır. Hastalık obeziteyle ilişkisiz kapsülsüz yağ dokusunun çok sayıda simetrik, yüz, baş, boyun bölgesi ile gövdenin üst kısmında ve diğer bölgelerde birikimiyle karakterizedir. Diyabet, hipotiroidi, karaciğer bozuklukları, kökeni bilinmeyen polinöropati gibi yandaş hastalıklar gözlenmekte olup MSL'ye eşlik eden santral nörolojik bozukluklar da rapor edilmiştir. Biz hiperbilirubinemiye bağlı serebral palsisi olan 32 ve 41 yaşındaki iki kadın olguyu MSL açısından tartışmak istedik. Etiyolojide lipolizin duraklatıldığı, katekolaminlerle tetiklenen bir lipid metabolizması bozukluğu ve yağ dokusunun fonksiyonel denervasyonu sonucu gelişebildiği öne sürülmüştür. Bu yazıda olgularla birlikte MSL'nin nörobiyolojisi ve klinik tanımına ilişkin bir dizi çözümlenmemiş konulardan bahsedilmektedir. Literatürdeki verilerin bir araya toplanmasıyla altta yatan mekanizmaların açısından yakın bir gelecekte daha net bir sonuca varılabileceğini düşünmekteyiz.

**Anahtar Kelimeler:** Lipomatoz, multipl simetrik; serebral palsy

**Türkiye Klinikleri J Neur 2012;7(1):29-32**

**M**ultiple symmetrical lipomatosis (MSL) was first described by Sir Benjamin Brodie in 1846, but Otto Madelung reported the first series of patients in 1888. It is a rare disorder of unknown etiology defined as the presence of multiple and symmetrical fatty accumulations, usually involving the upper trunk, neck and head. The disorder usually oc-

curs in middle-aged male alcoholics.<sup>1</sup> Frequently associated findings include diabetes mellitus, hyperlipidemia, liver diseases, hypothyroidism, and polyneuropathy of unknown origin, but nevertheless, there are published reports of cognitive disorders in patients with MSL.<sup>2</sup> We describe, for the first time, the state of cerebral palsy because of hyperbilirubinemia, simultaneously involving the bilateral regions of fatty deposits in the neck, shoulders and the upper extremities.

## CASE REPORT

### CASE 1

A 32-year-old female, whose physical examination showed multiple subcutaneous lipomas on her upper trunk, arms and upper legs (Figure 1). It has been learned from the previous history of the patient that she had a treatment because of hyperbilirubinemia when she was a newborn. Athetoid type cerebral palsy was observed in her neurological examination. She was also seen at our clinic with the complaints of painful weakness and burning feet four months ago. Neurological examination revealed sensorimotor polyneuropathy. Nerve conduction studies showed reduction of the sensory conduction velocities. Mini-Mental Status Exam (MMSE) score was 24/30. Disoriented to date and day of the week, good registration but impaired ability to complete serial 7s, impaired attention, and very poor short-term memory were the findings in MMSE. Unable to recall any three items

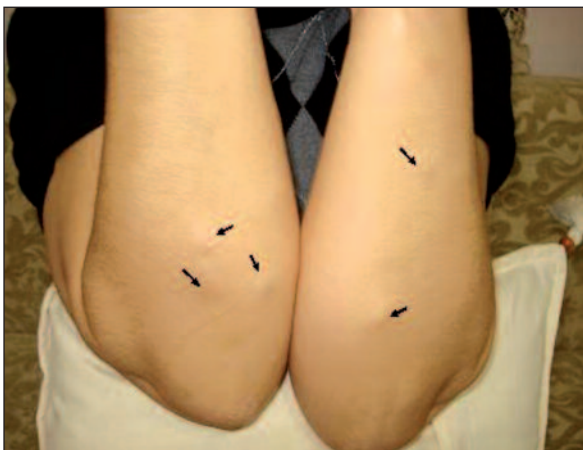

FIGURE 1: Multiple subcutaneous lipomas in both arms.

after 3 minutes. She was able to draw interlocking pentagons.

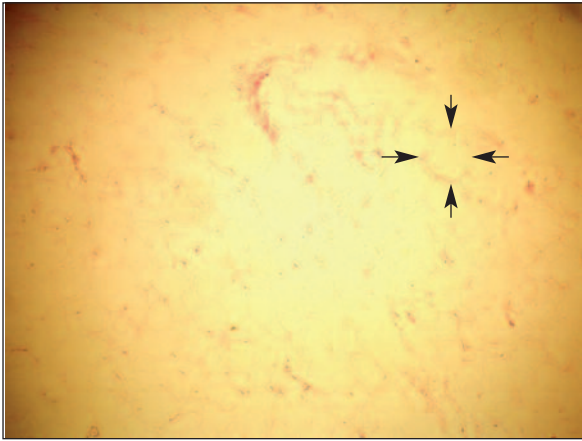
Slowing and sharp waves in the activity were observed in electroencephalography (EEG). Complete blood count, hepatic function panel, total cholesterol, LDL cholesterol, triglycerides and hormone tests (ACTH, cortisol, GH, TSH, fT3, fT4, insulin, LH, FSH, testosterone, androstenedione, estradiol, progesterone, prolactin and DHEA-SO<sub>4</sub>) were all resulted as normal. Brain tomography showed bilateral basal ganglia hyperdensity.

### CASE 2

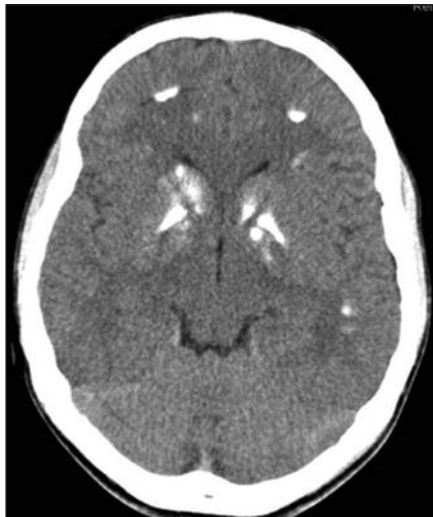A 41-year-old female reported multiple large neck masses that had enlarged progressively during the last 5 years. The patient was diagnosed as having MSL based on the physical examination findings and subcutaneous adipose tissue in biopsy. A fatty mass was excised. Histologically, the adipose tissue appeared normal and had smaller sized adipocytes with spindle cells without malignant changes (Figure 2). This patient also has similar previous history, neurological examination, EEG and laboratory results. Her MMSE score was also 24/30. According to test-retest findings, our patient presented cognitive deterioration, with defective control of complex attention and progressive neuropsychological deficits in memory function (immediate memory span, episodic/prose memory, efficiency of learning strategy, visual recall), visuospatial and spatioperceptual dexterities, as well as visual reasoning and executive processes. Contrary to fluid intelligence, crystallized verbal intelligence remains within the normal performance range. Complete biochemical analysis was normal. There was no history of alcohol abuse. Basal ganglia hyperdensity was also observed in the brain tomography (Figure 3). Informed consent was obtained from each family before study.

## DISCUSSION

MSL is characterized by diffuse deposits of fat arranged symmetrically around the neck and shoulder girdle. Association with alcoholism and some metabolic disturbances (abnormal glucose tolerance; hyperuricemia; dyslipidemia; renal tu-



**FIGURE 2:** Histopathological examination of adipose tissue from the right upper arm. Note the normal and smaller sized fat cells without malignant changes (arrows) (HE, x40).



**FIGURE 3:** Brain tomography, bilateral basal ganglia hyperdensity.

bular acidosis; alterations in liver enzyme levels; abnormal function of glands (thyroid, adrenal, pituitary; and abnormal testicular function) are common.<sup>3</sup> Kernicterus is a potentially fatal neurologic disorder induced by the neurotoxic effects of unconjugated bilirubin on the central nervous system. Cerebral palsy (CP) is a non-progressive disorder of motor function. It describes a diverse group of disorders of movement, posture and tone due to a central nervous system insult. Intraventricular

hemorrhage & hyperbilirubinemia have strong correlations with the subsequent development of CP. Cerebral palsy is classified according to extremities involved (monoplegia, diplegia, hemiplegia and quadriplegia) and the characteristics of the neurologic dysfunction (spastic, dyskinetic, ataxic, hypotonic or a combination).<sup>4</sup> The cause of MSL is not known. Gonzales-Garcia et al. postulated that a defect in adrenergic-stimulated lipolysis generates the autonomy of adipocytes in MSL and alcoholism seems to decrease  $\beta$ - adrenergic receptors and induce disturbance in the catalytic unit of adenylylase and in mitochondrial DNA in the adipocytes. Genetic mitochondrial pathologies usually result from point mutations or deletions in mitochondrial DNA that finally impair oxidative phosphorylation capacity. Interestingly, some mitochondrial disorders affect lipid metabolizing tissues such as muscular and adipose tissues. MSL is a pathology characterized by the formation of lipomas containing abnormal white adipocytes smaller than normal adipocytes showing a multivesicular phenotype.<sup>5</sup> Moreover, biochemical analyses have shown that cytochrome c oxidase activity is impaired in muscles from patients with MSL, supporting the fact that the disease is linked to mitochondrial dysfunction.<sup>6</sup>

Rarely, central nervous system may be involved. In a study, abnormal mitochondrial status has been observed in MSL patients. Klopstock et al. have clinically or electrophysiologically showed that 53% of the patients with MSL have central nervous system dysfunction.<sup>7</sup>

When we compare our results with the other results in the literature we find that our cases could be different from other cases because of the cerebral palsy caused by hyperbilirubinemia. There are also a number of unresolved issues regarding the neurobiology of MSL and clinical definition together with the cases as noted in this paper. The underlying mechanism in our patients remains unknown and this questions should be the subject of a future study.

## REFERENCES

1. Hirose A, Okada Y, Morita E, Tanaka Y. Benign symmetric lipomatosis associated with alcoholism. *Intern Med* 2006;45(17):1001-5.
2. Saiz Hervás E, Martín Llorens M, López Alvarez J. Peripheral neuropathy as the first manifestation of Madelung's disease. *Br J Dermatol* 2000;143(3):684-6.
3. Tekin A, Ogetman Z. Central form of multiple symmetric lipomatosis: a case report. *Cases J* 2009;2:8427.
4. Davis DW. Review of cerebral palsy, part I: Description, incidence, and etiology. *Neuratel Netw* 1997;16(3):7-12.
5. González-García R, Rodríguez-Campo FJ, Sastre-Pérez J, Muñoz-Guerra MF. Benign symmetric lipomatosis (Madelung's disease): case reports and current management. *Aesthetic Plast Surg* 2004; 28(2):108-12.
6. Berkovic SF, Andermann F, Shoubbridge EA, Carpenter S, Robitaille Y, Andermann E. Mitochondrial dysfunction in multiple symmetrical lipomatosis. *Ann Neurol* 1991;29(5): 566-9.
7. Klopstock T, Naumann M, Schalke B, Bischof F, Seibel P, Kottlors M, et al. Multiple symmetric lipomatosis: abnormalities in complex IV and multiple deletions in mitochondrial DNA. *Neurology* 1994;44(5):862-6.