

# Giant Posterior Urethral Calculus Associated with Fournier's Gangrene: Case Report

## Fournier Gangreni ile Birlikte Görülen Posterior Üretral Dev Taş

Melih SUNAY, MD,<sup>a</sup>  
Mümtaz DADALI, MD,<sup>a</sup>  
Okan YALBUZDAĞ, MD,<sup>a</sup>  
Levent EMİR, MD,<sup>a</sup>  
Demokan EROL, MD<sup>a</sup>

<sup>a</sup>Clinic of 1<sup>st</sup> Urology,  
Ministry of Health Ankara Teaching and  
Research Hospital, Ankara

Geliş Tarihi/Received: 08.05.2009  
Kabul Tarihi/Accepted: 09.09.2009

Yazışma Adresi/Correspondence:  
Melih SUNAY, MD  
Ministry of Health Ankara Teaching and  
Research Hospital,  
Clinic of 1<sup>st</sup> Urology, Ankara,  
TÜRKİYE/TURKEY  
dr.m.sunay@gmail.com

**ABSTRACT** Urethral calculi are rare and most of them originate in the upper urinary tract or in the bladder. A review of the literature reveals that less than 2% of urinary tract stones are primarily located in the urethra. Urethral calculi are usually associated with urethral stricture or urethral diverticulum and may be lodged in the urethra during their passage. Calculi in the urethral diverticulum may cause recurrent urinary tract infections and a possible Fournier's gangrene. Fournier's gangrene is a form of necrotizing fasciitis affecting the male genitalia. Infection most commonly arises from the skin, urethra or rectal region. Herein, to our knowledge, the first case of an enormously large stone (4.8 x 8.9x 9.2 cm) in the proximal urethra presenting with Fournier's gangrene is reported.

**Key Words:** Urethral diseases; calculi; Fournier gangrene

**ÖZET** Üretra taşı az görülen bir klinik antidedir ve olguların çoğu üst üriner traktan veya mesaneden kaynaklanır. Literatürü gözden geçiren bir çalışma üriner trakt taşlarının %2'sinden daha azının primer olarak üretrada yerleştiğini göstermektedir. Üretral taş hastalarda genellikle üretral darlık veya üretral divertikül ile birlikte ve pasajları sırasında üretraya yerleşebilirler. Üretral divertiküldeki taşlar reküren üriner trakt enfeksiyonlarına ve hatta Fournier gangrenine yol açabilirler. Fournier gangreni nekrotizan fasiitisin erkek genital bölgesinde ortaya çıkan bir formudur. Enfeksiyon genellikle deri, üretra veya rektal bölgeden kaynaklanır. Burada bizim bigimize göre literatürde muhtemelen ilk kez Fournier gangreni ile prezente olan proksimal üretradaki çok büyük, dev bir taş (4.8 x 8.9 x 9.2 cm) olgusu sunulmaktadır.

**Anahtar Kelimeler:** Üretra hastalıkları; taşlar; Fournier gangreni

**Türkiye Klinikleri J Med Sci 2011;31(4):1019-21**

Urethral calculi are uncommon and may arise primarily in an urethral diverticulum.<sup>1</sup> Fournier's gangrene is a disease characterized by necrotizing fasciitis of the perineal and genital region. Predisposing factors include diabetes mellitus, local trauma, paraphimosis, periurethral extravasation of urine, perirectal or perianal infections, and surgery such as circumcision or herniorrhaphy.<sup>2</sup> If calculi stay in an urethral diverticulum for years, it may cause recurrent urinary tract infections, urethrocutaneous fistula<sup>3</sup> and probably Fournier's gangrene. We herein report, to our knowledge the first case in the English literature, of a posterior urethral calculus associated with Fournier's gangrene.

## CASE REPORT

A 48-year-old male patient was referred to the emergency service of our institution because of penoscrotal expansive erythema and swelling, perineal pain, weak stream and urinary retention. Neither pelvic injury nor chronic diseases (for example, diabetes mellitus) were presented in the medical history of the patient. Physical examination showed a firm and painful solid mass located in the proximal penile urethra and crepitation in scrotum. Leukocytosis was found on blood analysis. The other parameters were normal. Pelvic X-ray examination confirmed the diagnosis of the giant posterior urethral calculi. A retrograde urethrogram showed a large urethral stone, 8.6 x 8.1 cm in size at the prostatic urethra (Figure 1). Abdominal ultrasonography was normal.

First, a suprapubic catheter was placed. Then, surgery was performed by penoscrotal approach and posterior urethral stone was extracted (Figure 2). The dimension of the stone was 4.8 x 8.9 x 9.2 cm. Extended debridement was performed for Fournier's gangrene and surgical area closure was not applied for daily debridements (Figure 3).

Suprapubic urinary drainage was maintained and because wound culture yielded *Enterococcus fecalis*, suitable antibiotic treatment was administered and daily debridement was performed for 14 days after the initial surgery. When no microorganisms grew in wound culture and the patient's general conditions had improved, urethra closure was performed by penile pedicle island flap (Figure 4).

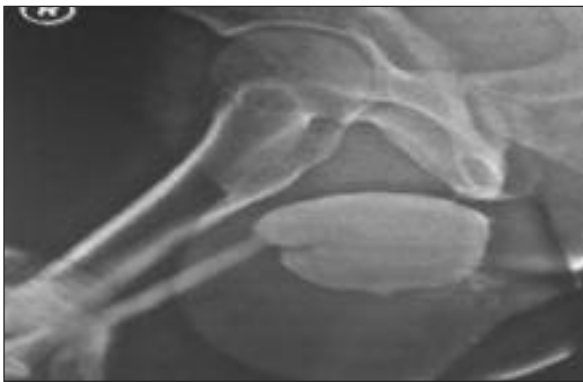


FIGURE 1: Giant stone on retrograde.

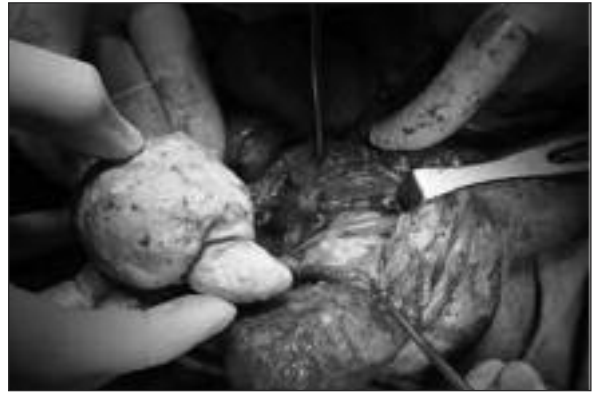

FIGURE 2: External urethrotomy and stone extraction.

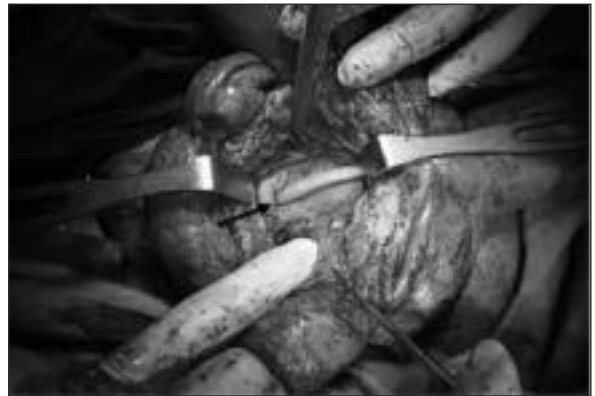

FIGURE 3: Surgical area after stone extraction and debridement (dark arrow is urethra).

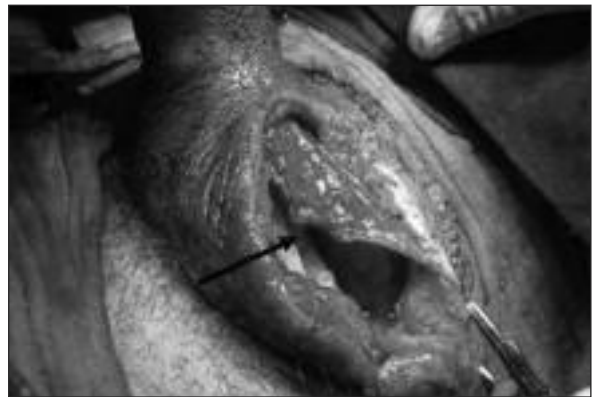

FIGURE 4: Penile pedicle island flap.

Suprapubic catheter was removed and a urethral 18-F Foley catheter placed for 14 days. After pericatheteral retrograde urethrogram examination had been performed (Figure 5), the indwelling catheter was removed and spontaneous voiding was observed.

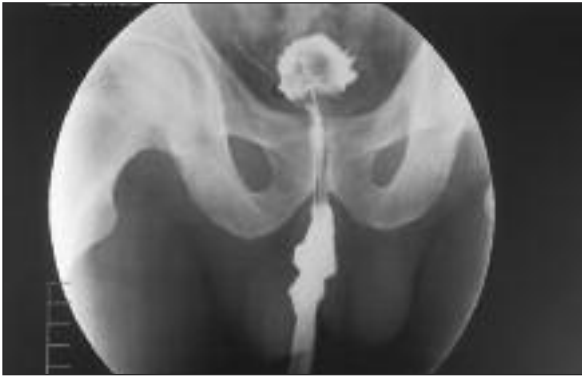

FIGURE 5: Pericatheter retrograde urethrogram.

He voided with a maximal urinary flow of 14 ml/s without residual urine at third month of follow up. X-ray diffraction analysis of the stone revealed the stone to be magnesium ammonium phosphate.

## DISCUSSION

Urethral stones represent less than 2% of all urinary stone disease and majority of them are formed in the bladder or kidney.<sup>4</sup> Native urethral calculi can be formed in association with abnormalities that predispose to urinary stasis and infection. Calculi may form proximal to urethral strictures, in congenital and acquired urethral diverticula, with chronic infection, with foreign bodies and with use of hair-bearing skin for urethroplasty.<sup>3-5</sup> Native urethral stones generally do not cause acute symptoms because of their slow development and growth. The main symptoms are acute urinary retention, frequency, dysuria, poor or interrupted urinary stream, incomplete emptying, and dribbling or incontinence. External palpation can reveal the stone if it

is lodged in the penile or bulbous urethra. Rectal examination may detect stones in the posterior urethra. Radiography can be helpful but endoscopy is diagnostic.

Fournier's gangrene is necrotizing fasciitis arising from the perineal skin, scrotum, urethra or rectum. The most common causes of Fournier's gangrene are anorectal infections, genitourinary infections and trauma, perineal and genital skin injuries.<sup>2</sup> Urethral calculi is not defined as an etiological factor in the English literature, to our knowledge. However, a Fournier's gangrene case with severe, deep, full penile thrombosis secondary to urethral calculi was reported in the Spanish literature.<sup>6</sup> Immediate surgical debridement and broad-spectrum antimicrobial agents are the essentials of treatment of Fournier's gangrene. Surgical debridement should be performed until reaching healthy, well-vascularized tissues, and infected and necrotic tissues should be removed.<sup>2</sup>

The management of urethral calculi varies according to the size, site, associated pathology and status of urethra. The aim of treatment is relief of obstruction and stone removal without damaging the urethra and periurethral tissues. If the urethral calculus is small, it can be pushed into the urinary bladder and litholapaxy can be applied. Because of the enormous size of the stone and its association with Fournier's gangrene in this case, we performed external urethrotomy to extract the stone and removed infected, necrotic tissues for the management of Fournier's gangrene.

This reported case reveals that the urethral calculus should be taken into consideration in the etiology of Fournier's gangrene.

## REFERENCES

1. Ho KL, Segura JW. Lower urinary tract calculi. In: Wein AJ, Kavoussi LR, Novick AC, Partin AW, Peters CA, eds. *Campbell-Walsh Urology*. 9<sup>th</sup> ed. Philadelphia: Saunders Elsevier; 2007. p.2663-73.
2. Morpurgo E, Galandiuk S. Fournier's gangrene. *Surg Clin North Am* 2002;82(6):1213-24.
3. Kaplan M, Atakan IH, Kaya E, Aktoz T, Inci O. Giant prostatic urethral calculi associated with urethrocutaneous fistula. *Int J Urol* 2006;13(5):643-4.
4. Koga S, Arakaki Y, Matsuoka M, Ohyama C. Urethral calculi. *Br J Urol* 1990;65(3): 288-9.
5. Hegele A, Olbert P, Wille S, Heidenreich A, Hofmann R. Giant calculus of the posterior urethra following recurrent penile urethral stricture. *Urol Int* 2002;69(2):160-1.
6. Campos JA, Martos JA, Gutiérrez del Pozo R, Carretero P. Synchronous caverno-spongious thrombosis and Fournier's gangrene. *Arch Esp Urol* 1990;43(4):423-6.