

Sensitivity and Specificity of Main Parameters of Corneal Topography for Discriminating the Severity of Keratoconus

Keratokonusun Şiddetini Belirlemede Temel Korneal Topografi Parametrelerinin Duyarlık ve Özgüllüğünün Değerlendirilmesi

 Yeşim ALTAY,^a

 Hülya BOLU^b

^aDepartment of Ophthalmology,
Ufuk University Faculty of Medicine,
Ankara

^bEkol Eye Clinic,
İzmir

Received: 17.09.2017

Received in revised form: 14.10.2017

Accepted: 24.10.2017

Available online: 10.08.2018

Correspondence:

Yesim ALTAY

Ufuk University Faculty of Medicine,
Department of Ophthalmology, Ankara,
TURKEY/TÜRKİYE
altayye@yahoo.com

This study was presented verbally at the 50th
National Ophthalmology Congress,
9-13 November 2016, Antalya.

ABSTRACT Objective: To determine the sensitivity and specificity of main parameters; maximum keratometry readings (Kmax), pachymetry at the thinnest point of the cornea (TCT), and posterior elevation (PE) in discriminating mild-moderate keratoconus (KC) from severe keratoconus. **Material and Methods:** Eighty six (51 mild-moderate, and 35 severe) keratoconic patients were recruited in this study. Kmax, TCT, and PE were recorded using Scheimpflug camera system. In order to distinguish mild-moderate KC group from severe KC group, receiver operating characteristic (ROC) curves were generated and areas under the curves (AUC) were calculated for all parameters. Cut off points for Kmax, TCT and PE and sensitivity and specificity, positive likelihood ratio (LR+), and negative likelihood ratio (LR-) for these cut off points were also calculated. **Results:** Between the severe KC and mild-moderate KC, the most discriminating parameter was Kmax (AUC = 0.913), followed by TCT (AUC = 0.848) and PE (AUC = 0.566). The cut off value was 66.70 D for Kmax with a sensitivity of 88.6% and a specificity of 78.4%. The cut off value was 359.50 µm for TCT with a sensitivity of 80.0% and a specificity of 74.5%. And the cut off value of PE was 171.50 µm with a sensitivity of 54.3% and a specificity of 62.7%. When KC became severe the diagnostic efficiency of characteristic parameters decreased from the Kmax, TCT to PE. **Conclusion:** In our study, ROC curve analyses indicated that Kmax and TCT were the most important measurements with Pentacam in progression from mild-moderate to severe keratoconus.

Keywords: Keratoconus; corneal topography

ÖZET Amaç: Hafif-orta keratokonusu (KC) şiddetli keratokonustan ayırt etmede temel parametrelerin (maksimum keratometri ölçümü (Kmax), korneanın en ince noktasının pakimetrisi (TCT), ve posterior elevasyon (PE) duyarlık ve özgüllüğünü belirlemek. **Gereç ve Yöntemler:** Bu çalışmaya 86 (51 hafif-orta ve 35 şiddetli) keratokonus hastası dahil edildi. Scheimpflug kamera sistemi kullanılarak Kmax, TCT, ve PE ölçümleri kaydedildi. Hafif-orta KC grubunu şiddetli KC grubundan ayırt etmek üzere bu parametrelerin hepsi için receiver operating characteristic (ROC) eğrileri oluşturularak eğri altında kalan alanlar (AUC) hesaplandı. Kmax, TCT ve PE için eşik değerler saptandı ve bu eşik değerler için duyarlık, özgüllük, pozitif olabirlik oranı (LR+) ve negatif olabirlik oranı (LR-) hesaplandı. **Bulgular:** Şiddetli KC ve hafif-orta KC için en ayırt edici parametre Kmax (AUC= 0,913) idi, bunu sırasıyla TCT (AUC= 0,566) ve PE (AUC= 0,566) izliyordu. Kmax için eşik değer 66,70 D idi ve %88,6 duyarlık, %78,4 özgüllüğe sahipti. TCT eşik değeri 359,50 µm idi ve %80,0 duyarlık, %74,5 özgüllüğe sahipti. PE eşik değeri 171,50 µm idi ve %54,3 duyarlık ve %62,7 özgüllüğe sahipti. KC şiddeti arttıkça temel parametrelerin tanusal etkinliği Kmax, TCT ve PE olarak azalıyordu. **Sonuç:** Bizim çalışmamızda, ROC eğrisi analizleri, keratokonusun hafif-ortadan şiddetliye ilerlemesinin değerlendirilmesinde Pentacam ile Kmax ve TCT ölçümlerinin en önemli ölçümler olduğunu gösterdi.

Anahtar Kelimeler: Keratokonus; kornea topografisi

Keratoconus (KC) is a non-inflammatory disease characterised by progressive corneal thinning and ectasia of the central or paracentral region. These corneal changes result in reduced visual acuity because

of irregular astigmatism in the early stages of the disease and severe visual loss can occur as a result of corneal scarring in the later stages of disease.¹ The prevalence of the disease is 0.2-2.3% of the population.^{2,3}

Keratoconus is mostly bilateral disease. The frequency of unilateral cases is ranging from 0.5-16%.⁴⁻⁷ The incidence of unilateral cases varies depending on examination techniques. As more advanced techniques used for examination, such as Scheimpflug imaging, more bilateral cases will be detected.^{8,9} There are many classification criteria of keratoconus.¹⁰ These classification systems use different parameters for grouping severity. Amsler – Krumeich classification has the highest correlation with other classifications.

Corneal topography is the most useful tool for the detection and progression monitoring of KC. The Scheimpflug rotating camera measures the curvature and elevation of the anterior and posterior corneal surface as well as pachymetry with high reproducibility and repeatability.^{8,9}

Some researchers evaluated compound indicators, such as KC percentage index KISA % (Keratometry, Inferior-superior dioptric asymmetry, Skew percentage, Astigmatism), corneal thickness spatial profile etc. for detection of KC.^{11,12} However, neither these indicators are sufficient for differentiating adjacent KC stages nor monitoring KC progression.

In this study, the diagnosing efficiency of main corneal topography parameters for differentiating adjacent Scheimpflug camera-derived Amsler Krumeich stages (mild-moderate keratoconus and severe keratoconus) was investigated.

MATERIAL AND METHODS

We examined the medical records of total 86 patients with keratoconus, retrospectively. The research followed the tenets of the Declaration of Helsinki. All patients had given written informed consent before their examinations. Patients with corneal scar, previous eye surgery, macular disease, optic nerve disease, corneal dystrophies and degenerations were excluded from the study. A diag-

nosis of keratoconus had been determined by cornea specialists using slitlamp biomicroscopy examination (Vogt's stria or Fleischer ring consistent with keratoconus, etc.) and corneal topography parameters (increased area of corneal power surrounded by concentric areas of decreasing power, inferosuperior power asymmetry, or skewing of the steepest radial axes above and below the horizontal meridian etc.).¹ All patients underwent clinical evaluation and testing with Pentacam™ corneal topography (Oculus, Wetzlar, Germany). The measurement results were accepted under the quality specification window (quality specification QS reads OK). Maximum keratometry readings (Kmax), pachymetry at the thinnest point of the cornea (TCT), and posterior elevation (PE) were recorded using Scheimpflug camera system.

For posterior corneal elevation measurements a best fit sphere (BFS) was used as a reference surface by using the float option over 9 mm fit. Posterior elevation at the thinnest point of the cornea, where ectasia was more prominent, was recorded.¹³ Patients were subgrouped to Amsler-Krumeich keratoconus classification using pentacam software.¹⁴ Keratoconus grading designated as Stage I, Stage I-II, Stage II, Stage II-III, Stage III, Stage III-IV, Stage IV. In order to make comparison of patients with adequate numbers, we divided the patients into two groups as mild-moderate keratoconus (keratoconus stage \leq III) and severe keratoconus (keratoconus stage $>$ III).

Statistical analyses were performed using SPSS software version 15. The variables were investigated using visual (histogram, probability plots) and analytical methods (Shapiro-Wilk's test) to determine whether or not they are normally distributed. Descriptive analyses were presented using means and standard deviations for normally distributed variables (Kmax, TCT, and PE). A p-value of less than 0.05 was considered to show a statistically significant result.

We compared Kmax, TCT and PE values between two groups. Box plot figures were employed to compare the distribution of Kmax, TCT, and PE values in mild-moderate KC group, and in severe KC group.

In order to discriminate mild-moderate KC group from severe KC group, receiver operating characteristic (ROC) curves were generated and areas under the curves (AUC) were calculated for all parameters. Cutoff points for Kmax, TCT and PE and sensitivity and specificity, positive likelihood ratio (LR+), and negative likelihood ratio (LR-) for these cut off points were also calculated.

RESULTS

A total of 86 keratoconic eyes were examined with Scheimpflug camera system. There were 51 patients (59.30%) in mild-moderate keratoconus group (group I) and 35 patients (40.70%) in severe keratoconus group (group II).

The mean ages were $26,35 \pm 11,66$ (range 13-53) and $29,26 \pm 11,60$ (range 14-63) years for the group I and II, respectively. There was no difference between the groups in relation to age of patients ($p=0,72$, student's t-test).

The male /female ratio was 27/24 in group I (mild-moderate keratoconus group), and 25/10 in group II (severe keratoconus group). There was no difference in relation to gender between the groups ($p=0,08$, Chi-square).

The mean Kmax value was $59,87 \pm 8,44$ in mild-moderate KC group and $81,80 \pm 14,81$ in severe KC group. The box plot graphic of Kmax was presented in Figure 1.

The mean thinnest corneal thickness was $397,14 \pm 59,75$ μm (ranged from 259.00 to 496.00) in mild-moderate KC group and $285,14 \pm 94,38$ μm (ranged from 115.00 to 484.00) in severe KC group. The box plot graphic of TCT was presented in Figure 2.

The mean PE value was $164 \pm 72,30$ and $180,00 \pm 74,90$ in mild-moderate and severe group respectively. The box plot graphic of PE was presented in Figure 3.

Comparison of Pentacam parameters between the groups are presented in Table 1.

To discriminate severe keratoconus from mild-moderate keratoconus, the diagnostic efficiencies

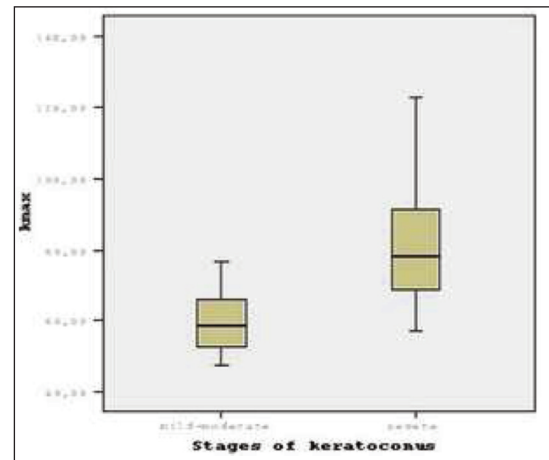


FIGURE 1: Box plot graphic comparing maximum K readings between mild-moderate keratoconus group and severe keratoconus group.

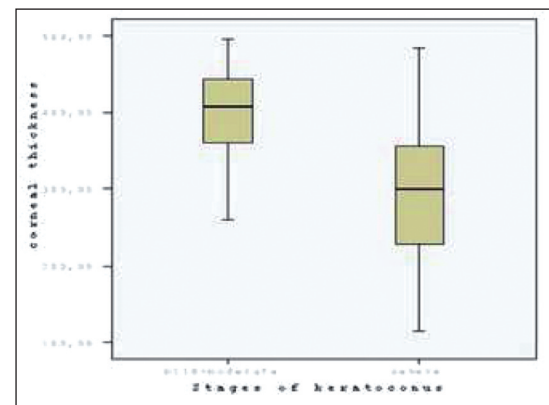


FIGURE 2: Box plot graphic comparing thinnest corneal thickness between mild-moderate keratoconus group and severe keratoconus group.

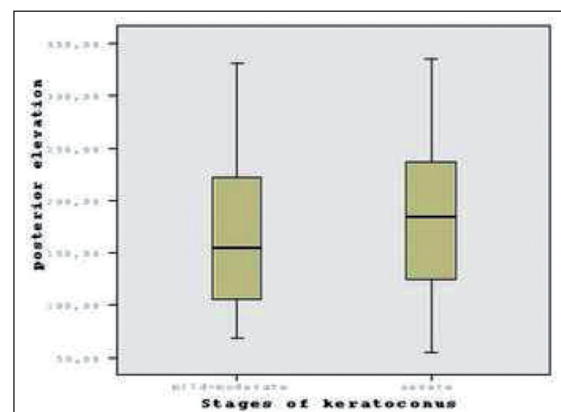


FIGURE 3: Box plot graphic comparing posterior elevation values between mild-moderate keratoconus group and severe keratoconus group.

TABLE 1: Comparison of age and gender, and Pentacam parameters between the mild-moderate keratoconus group and severe keratoconus group.

Variables	Groups according to stage of keratoconus		
	Mild-moderate N= 51	Severe N= 35	p
Age (years) (mean±standard deviation)	28.35±11.66	29.26±11.60	0.72 ^a
Gender (male/female)	27(51.9)/24(47.1)	25(71.4)/10(28.6)	0.08 ^b
Posterior elevation(µm) (mean±standard deviation)	164.39±72.30	180.00±74.90	0.33 ^a
Kmax (D) (mean±standard deviation)	59.87±8.44	81.80±14.81	0.0001 ^{a*}
Corneal thickness (µm) (mean±standard deviation)	397.14±59.75	285.14±94.38	0.0001 ^{a*}

^a t-test.^b Chi-square test.

* Statistically significant difference.

Ranges of variables:

age : mild-moderate 13-53 years; severe 14-63 years.

posterior elevation: mild-moderate 69-331 µm; severe 55-335 µm.

kmax: mild-moderate 47.60-76.60 D; severe 56.90-123.00 D.

corneal thickness: mild-moderate 259.00-496.00 µm; severe 115.00-484.00 µm.

of all parameters (Kmax, TCT, and PE) were significant (all AUC \geq 0.500).

The diagnostic efficiency of these parameters decreased orderly from Kmax, TCT and PE. Between the severe keratoconus and mild-moderate keratoconus stages, the most discriminating parameter was Kmax (AUC= 0.913), followed by thinnest CT (AUC= 0.848) and PE (AUC= 0.566) (Table 2) (Figure 4, 5).

The cut off value was 66.70 D for Kmax with a sensitivity of 88.6% and a specificity of 78.4%. The cutoff value was 359.50 µm for TCT with a sensitivity of 80.0% and a specificity of 74.5%. And the cut off value of PE was 171.50 µm with a sensitivity of 54.3% and a specificity of 62.7%.

DISCUSSION

Keratoconus is a progressive ectasia of the cornea and Pentacam Scheimflug corneal topography is

one of the most commonly used devices to monitor progression of corneal ectasia. There have been several clinical reports about topography for progression of keratoconus.^{10,15-18} Some researchers investigated compound indicators, such as the keratoconus percentage index KISA%, corneal thickness spatial profile and percentage thickness increase.^{11,12}

The purpose of this study was to determine the sensitivity and specificity of Kmax, TCT and PE data in discriminating Pentacam-derived Amsler-Krumeich stage (mild-moderate KC group from severe KC group). We chosed basic parameters rather than compound parameters so that the keratoconus developing course can be easily understood and the findings can be conveniently applied to daily clinical practice.

Previously, several authors evaluated changes of keratoconus at different stages. In a study by Du

TABLE 2: Area under curve and cut off values of ROC curve for the main Pentacam parameters in mild-moderate keratoconus / severe keratoconus.

Parameters	AUC	Cut off value	Sensitivity (%)	Specificity (%)	LR+	LR-
Kmax	0.913	\geq 66.70	88.6	78.4	4.101	0.145
TCT	0.848	\leq 359.50	80.0	74.5	3.137	0.268
PEV	0.566	\geq 171.50	54.3	62.7	1.455	0.728

ROC curve receiver operating characteristic curve

AUC: area under curve; Kmax: maximum K value; TCT: thinnest corneal thickness; PEV: posterior elevation value; LR+: positive likelihood ratio; LR-: negative likelihood ratio.

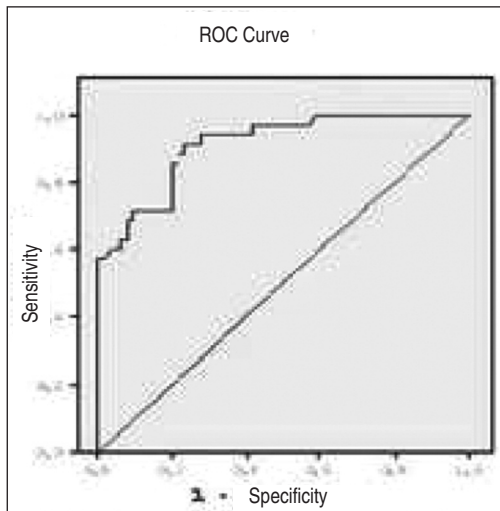


FIGURE 4: Receiver operating characteristic (ROC) curve for maximum K readings (Kmax) to discriminate severe keratoconus.

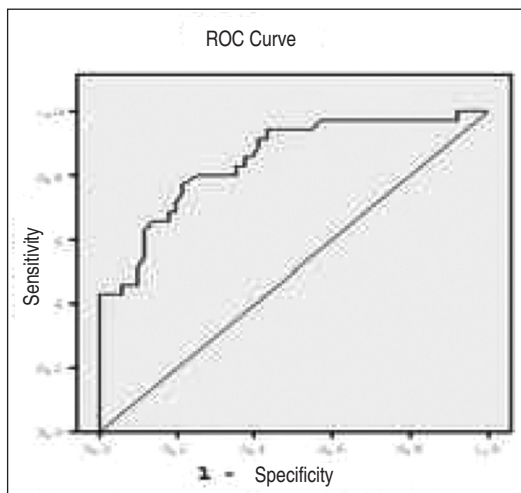


FIGURE 5: Receiver operating characteristic (ROC) curve for thinnest corneal thickness (TCT) to discriminate severe keratoconus.

et al. between the subclinical and moderate stages, diagnostic efficiency of Pentacam indices decreased orderly from posterior elevation, anterior elevation, anterior Kmax and posterior Kmax. In their report, between the two adjacent stages (subclinical and moderate stages), the most characteristic index was PE (AUC=0.988), with a sensitivity of 95% and a specificity 92.7%.¹⁹ When KC became severe, the diagnostic efficiency of characteristic indices changed from the anterior Kmax, posterior Kmax, anterior SimKm, anterior Kmin to PE in decreasing order (all AUC > 0.9).¹⁶

These results were consistent with our findings. In our study, all AUCs of the main parameters were larger than 0.5 for comparison of severe KC and mild-moderate KC. But the Kmax (AUC=0.913) showed the highest discriminating capacity. This means that, the cornea protruded to a wider range with disease progression. As KC progressed diagnostic efficiency of PE values (AUC = 0.566) declined compared to other parameters.

Naderan et al. reported that TCT is the most important and also the most sensitive and specific parameter for distinguishing all stages of KC severity classification. Sensitivity of TCT was 0.806, 0.792 and 0.851, and specificity was 0.767, 0.745 and 0.811 for Amsler- Krumeich quartile.²⁰

However, Flynn et al. reported that corneal thickness was the second efficient diagnostic index for the subclinical KC stage (AUC=0.852). The diagnostic value of corneal thickness was high in the subclinical stage, but declined when KC became moderate. They reported AUC values of ROC curve for severe vs moderate KC eyes as 0.795.¹⁶ In our study TCT (AUC = 0.848) was also second highest diagnostic Pentacam derived parameter for differentiating mild-moderate KC from severe KC. During the progression from moderate keratoconus to severe keratoconus, accompanied with the thinning of cornea, the diagnostic value increased in anterior curvature readings. These changes indicated that when keratoconus progressed to severe stage, the cornea appeared entirely protruding.

In conclusion, Kmax, posterior elevation and thinnest pachymetry values appear to be the most critical components in the diagnosis and follow up of keratoconus patients. These data describe the precision of important topographic measures with Pentacam in mild-moderate and severe keratoconus. In our study, ROC curve analyses indicated that Kmax and TCT were the most important measures with Pentacam in disease progression from mild-moderate to severe keratoconus. These data will help clinicians to more accurately identify topographic progression of keratoconus.

Source of Finance

During this study, no financial or spiritual support was received neither from any pharmaceutical company that has a direct connection with the research subject, nor from a company that provides or produces medical instruments and materials which may negatively affect the evaluation process of this study.

Conflict of Interest

No conflicts of interest between the authors and / or family members of the scientific and medical committee members or

members of the potential conflicts of interest, counseling, expertise, working conditions, share holding and similar situations in any firm.

Authorship Contributions

Idea/Concept: Yeşim Altay; **Design:** Yeşim Altay; **Control/Supervision:** Yeşim Altay; **Data Collection and/or Processing:** Yeşim Altay, Hülya Bolu; **Analysis and/or Interpretation:** Yeşim Altay, Hülya Bolu; **Literature Review:** Yeşim Altay, Hülya Bolu; **Writing the Article:** Yeşim Altay; **Critical Review:** Yeşim Altay, Hülya Bolu.

REFERENCES

- Davidson AE, Hayes S, Hardcastle AJ, Tuft SJ. The pathogenesis of keratoconus. *Eye (Lond)* 2014;28(2):189-95.
- Hashemi H, Beiranvand A, Khabazkhoob M, Asgari S, Emamian MH, Shariati M, et al. Prevalence of keratoconus in a population-based study in Shahroud. *Cornea* 2013; 32(11):1441-5.
- Millodot M, Shneur E, Albou S, Atlani E, Gordon-Shaag A. Prevalence and associated factors of keratoconus in Jerusalem: a cross-sectional study. *Ophthalmic Epidemiol* 2011;18(2):91-7.
- Chopra I, Jain AK. Between eye asymmetry in keratoconus in an Indian population. *Clin Exp Optom* 2005;88(3):146-52.
- Abu Ameerh MA, Al Refai RM, Al Bdour MD. Keratoconus patients at Jordan University Hospital: a descriptive study. *Clin Ophthalmol* 2012;6:1895-9.
- Weed KH, MacEwen CJ, Giles T, Low J, McGhee CN. The Dundee University Scottish Keratoconus study: demographics, corneal signs, associated diseases, and eye rubbing. *Eye (Lond)* 2008;22(4):534-41.
- Wei RH, Zhao SZ, Lim L, Tan DT. Incidence and characteristics of unilateral keratoconus classified on corneal topography. *J Refract Surg* 2011;27(10):745-51.
- Chen D, Lam AK. Intrasession and intersession repeatability of pentacam system on posterior corneal assessment in the normal human eye. *J Cataract Refract Surg* 2007;33(3):448-54.
- Ambrósio R Jr, Belin MW. Imaging of the cornea: topography vs tomography. *J Refract Surg* 2010;26(11):847-9.
- Zadnik K, Barr JT, Edrington TB, Everett DF, Jameson M, McMahon TT, et al. Baseline findings in the Collaborative Longitudinal Evaluation of Keratoconus (CLEK) Study. *Invest Ophthalmol Vis Sci* 1998;39(13):2537-46.
- Li X, Yang H, Rabinowitz YS. Keratoconus: classification scheme based on videokeratography and clinical signs. *J Cataract Refract Surg* 2009;35(9):1597-603.
- Ambrósio R Jr, Alonso RS, Luz A, Coca Velarde LG. Corneal-thickness spatial profile and corneal-volume distribution: tomographic indices to detect keratoconus. *J Cataract Refract Surg* 2006;32(11):1851-9.
- Henriquez MA, Izquierdo L Jr, Mannis MJ. Intereye asymmetry detected by Scheimpflug imaging in subjects with normal corneas and keratoconus. *Cornea* 2013;32(6):779-82.
- Kanellopoulos AJ, Asimellis G. Revisiting keratoconus diagnosis and progression classification based on evaluation of corneal asymmetry indices, derived from Scheimpflug imaging in keratoconic and suspect cases. *Clin Ophthalmol* 2013;7:1539-48.
- Qin B, Chen S, Brass R, Li Y, Tang M, Zhang X, et al. Keratoconus diagnosis with optical coherence tomography-based pachymetric scoring system. *J Cataract Refract Surg* 2013; 39(12):1864-71.
- Flynn TH, Sharma DP, Bunce C, Wilkins MR. Differential precision of corneal Pentacam HR, measurements in early and advanced keratoconus. *Br J Ophthalmol* 2015;100(9):1183-7.
- Kamiya K, Ishii R, Shimizu K, Igarashi A. Evaluation of corneal elevation, pachymetry and keratometry in keratoconic eyes with respect to the stage of Amsler-Krumeich classification. *Br J Ophthalmol* 2014;98(4):459-63.
- de Sanctis U, Loiacono C, Richardi L, Turco D, Mutani B, Grignolo FM. Sensitivity and specificity of posterior corneal elevation measured by Pentacam in discriminating keratoconus/subclinical keratoconus. *Ophthalmology* 2008;115(9):1534-9.
- Du XL, Chen M, Xie LX. Correlation of basic indicators with stages of keratoconus assessed by Pentacam tomography. *Int J Ophthalmol* 2015;8(6):1136-40.
- Naderan N, Shoar S, Kamaledin MA, Rajabi MT, Naderran M, Khodadadi M. Keratoconus clinical findings according to different classification. *Cornea* 2015;34(9):1005-11.