



Acquired Partial Lipodystrophy with Autoimmune Thyroiditis

 Ahu YORULMAZ,^a

 Esra ARI,^a

 Başak YALÇIN^a

^aClinic of Dermatology,
Ankara Numune Training and
Research Hospital,
Ankara

Received: 17.01.2018

Received in revised form: 10.06.2018

Accepted: 11.06.2018

Available online: 17.09.2018

Correspondence:

Ahu YORULMAZ

Ankara Numune Training and

Research Hospital,

Clinic of Dermatology,

Ankara, TURKEY

ahuyor@gmail.com

ABSTRACT Lipodystrophies are a group of rare diseases characterized by selective loss of adipose tissue. Lipodystrophies have been classified on the basis of whether the disease is familial or acquired, or whether the adipose tissue loss is generalized, partial or localized. Acquired partial lipodystrophy, also known as Barraquer-Simons syndrome or cephalothoracic lipodystrophy, is a rare form of lipodystrophy, of which etiopathogenesis has been closely linked with autoimmunity. Acquired partial lipodystrophy is typically characterized by symmetrical loss of fat from face, neck, upper extremities and trunk with spared or increased adiposity in the lower body. There is a growing body of evidence which suggests that autoimmunity plays a role in the etiopathogenesis of acquired partial lipodystrophy. Here, we report a very rare case of acquired partial lipodystrophy accompanied by autoimmune thyroiditis. Thus, we highlight the rarity of the condition and review the available literature on the subject.

Keywords: Acquired partial lipodystrophy; barraquer-simons syndrome; autoimmune thyroiditis; membranoproliferative glomerulonephritis; metabolic abnormality

Lipodystrophies are familial or acquired diseases characterized by a paucity or complete absence of adipose tissue. According to fat tissue loss, lipodystrophies have been classified as generalized, partial or localized lipodystrophy.^{1,2} Acquired partial lipodystrophy is a rare form of lipodystrophy, which is also known as Barraquer-Simons syndrome or cephalothoracic lipodystrophy.³ Acquired partial lipodystrophy is also recognized as having a close association with autoimmune diseases.⁴⁻¹⁶ Here, we report a very rare case of acquired partial lipodystrophy accompanied by autoimmune thyroiditis. As far as we know, this is the second case report describing an association between acquired partial lipodystrophy with autoimmune thyroiditis.

CASE REPORT

A 55-year-old man was admitted to our outpatient clinic with a several-months' history of painless erythematous lesions on the right side of his neck and on the proximal part of his left upper extremity. He told that the lesions gradually expanded leaving depressed areas. He also had a history of similar lesions which had begun in the early adulthood firstly on his both

earlobes. Subsequent lesions developed over the years on his left cheek and lately on the proximal part of the right arm, all of which left atrophic areas. There was no family and past history of any other diseases or medication. Upon dermatological examination, we observed symmetrical sclerosis on bilateral earlobes, virtually absence of subcutaneous adipose tissue at the left cheek and multifocal loss of adipose tissue on bilateral upper extremities (Figures 1-4). Dermatological examination also revealed an erythematous firm plaque with a central depressed area on the right side of his neck and erythematous plaques with partial loss of adipose tissue on the left upper extremity (Figures 2, 4).

Although we wanted to perform a skin biopsy, the patient did not agree with it. Laboratory studies including complete blood count with differential, serum chemistry profile, urinalysis revealed no abnormalities. Serologic tests for hepatitis B, C, syphilis and human immunodeficiency virus (HIV) were negative. Serum vitamin B12 and ferritin levels were within normal range. The thyroid panel was normal, on the other hand anti-thyroglobulin (anti-Tg) and anti-thyroid peroxidase (anti-TPO) values were increased (376.8 IU/ml and 742.3 IU/ml, respectively). In addition, erythrocyte sed-

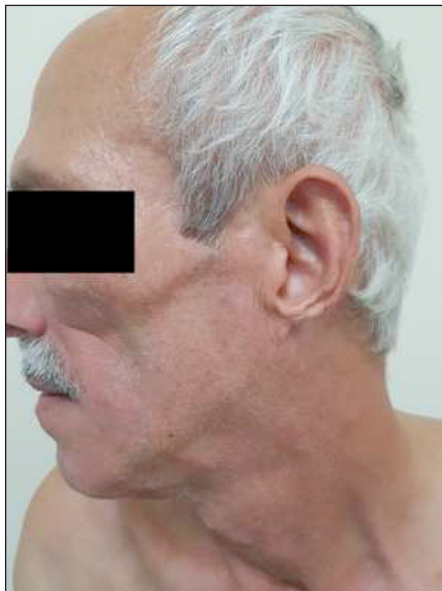

FIGURE 1: Sclerosis of the left earlobe, marked lipoatrophy causing sunken cheek and prominent zygomatic arch on the left side of the face.

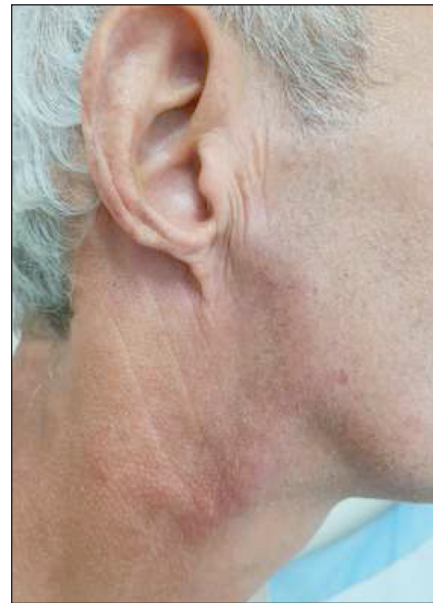

FIGURE 2: An erythematous plaque with an infiltrative border and a central depressed area, sclerosis of the right earlobe.

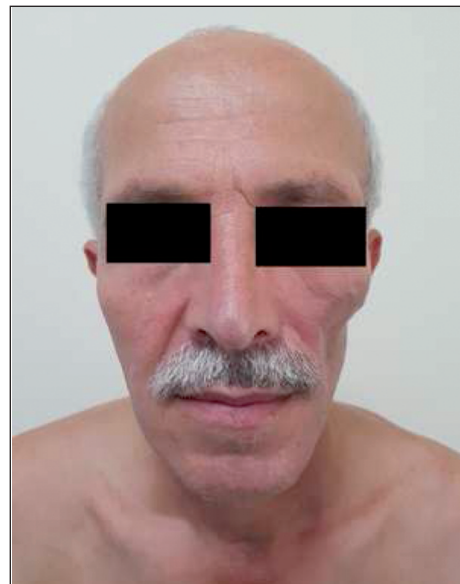

FIGURE 3: Prominent lipoatrophy on the left cheek.

imentation rate and serum C-reactive protein were elevated (42 mm/h and 14 mg/L, respectively). Antinuclear antibody was homogeneously positive at a titre of 1/3200. Based on history, clinical and laboratory findings, we made a diagnosis of acquired partial lipodystrophy accompanied by autoimmune thyroiditis. The patient was referred to endocrinology department for the management of autoimmune thyroiditis and investigation of other

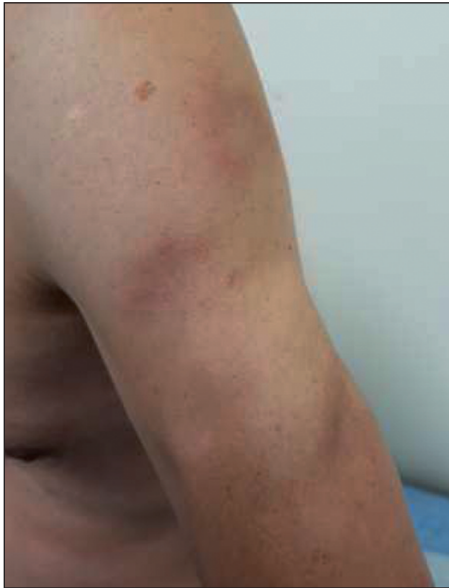

FIGURE 4: Erythematous plaques and partial loss of adipose tissue on the left proximal part of upper extremity.

possible metabolic abnormalities. We informed the patient about the condition and referred to plastic surgery department for improvement of cosmetic appearance.

DISCUSSION

Lipodystrophies are rare diseases and acquired partial lipodystrophy is a rare form of this unique disease group. Also known as cephalothoracic lipodystrophy, acquired partial lipodystrophy is characterized by loss of adipose tissue, which begins in the face and proceeds cephalocaudally. Gradual fat loss is typically bilateral and symmetrical in nature and limited to upper part of the body.^{1,3-6} The clinical feature, which distinguishes acquired partial lipodystrophy from other lipodystrophies is the downward spreading adipose tissue loss, which spares lower extremities.^{1,3-6,15,17} Our patient typically demonstrated main clinical characteristics of the disease. Progressive adipose tissue loss firstly occurred on his earlobes. In a time frame of several years, fat loss also developed gradually on his face and upper extremities. Acquired partial lipodystrophy is known to be four times more common in women than in men.^{3,4} Disease onset is usually in the childhood or adolescence period,

although rare cases of adult onset acquired partial lipodystrophy have been described.³⁻⁵ The onset of the disease and the gender of our patient were not consistent with the most common characteristics of acquired partial lipodystrophy. Thus, we suggest that even with these factors, our patient is a particular presentation of this extraordinary disease.

Besides, the most important feature of our patient was accompanying autoimmune thyroiditis. Autoimmunity has been questioned in the etiopathogenesis of acquired partial lipodystrophy. A detailed literature research reveals a noticeable number of reports on the association of autoimmunity with acquired partial lipodystrophy.⁴⁻¹⁶ It is well-known that metabolic abnormalities, including diabetes mellitus, insulin resistance, cardiovascular diseases and dyslipidemia are quite common in other types of lipodystrophies, although they are relatively rare in acquired partial lipodystrophy.^{2,4,18} It has been suggested that preserved fat in the lower body, which is not the case in other types of lipodystrophy, might be protective for metabolic abnormalities in acquired partial lipodystrophy.¹⁸ On the other hand, the most frequently reported comorbidity in acquired partial lipodystrophy is membranoproliferative glomerulonephritis that might cause subsequent chronic renal failure.^{4,18}

The pathogenesis of membranoproliferative glomerulonephritis in acquired partial lipodystrophy has not been fully understood yet. It has been suggested that activation and amplification of alternative complement pathway is the underlying process for membranoproliferative glomerulonephritis in acquired partial lipodystrophy. Misra et al. established that approximately 83% of acquired partial lipodystrophy patients had low complement (C) 3 levels and the presence of polyclonal immunoglobulin C3 nephritic factor (C3NeF).⁴ Generated immune complexes are implicated in initiating renal damage. Moreover, although pathogenesis of fat loss in patients with acquired partial lipodystrophy may be mediated by other mechanisms, activation of alternate

complement pathway is also presumed to cause lipodystrophy. Indeed, sera containing C3NeF were shown to induce lysis of adipocytes through the complement pathway.⁴

The exact cause and effect relationship of acquired partial lipodystrophy and autoimmunity is difficult to assess. There might be several factors included, however activation of alternate complement pathway likely to play the central role. As far as we know, our case is the second case in the literature describing association of autoimmune thyroiditis with acquired partial lipodystrophy.¹⁶ Misra et al. demonstrated that compared those without autoimmune diseases, acquired partial lipodystrophy patients with associated autoimmune diseases were predominantly female and had later onset of lipodystrophy. Acquired partial lipodystrophy itself occurs more commonly in females and gender predominance seems to be closely related with the prevalence of autoimmunity. In our opinion, autoimmunity explains the late onset of the disease in our patient. However, as we pointed earlier, as a male patient with autoimmune thyroiditis, our patient is an exceptional example of this unique disease. On the other

hand, the most important limitation of our case report is lack of demonstrating histopathological findings of our patient. The patient did not agree with any invasive procedure. Typical clinical findings of the patient led to the diagnosis of acquired partial lipodystrophy. We suggest that further reports are needed to establish a possible explanation of relationship of autoimmunity with acquired partial lipodystrophy.

Source of Finance

During this study, no financial or spiritual support was received neither from any pharmaceutical company that has a direct connection with the research subject, nor from a company that provides or produces medical instruments and materials which may negatively affect the evaluation process of this study.

Conflict of Interest

No conflicts of interest between the authors and / or family members of the scientific and medical committee members or members of the potential conflicts of interest, counseling, expertise, working conditions, share holding and similar situations in any firm.

Authorship Contributions

All authors contributed equally while this study preparing.

REFERENCES

- Garg A. Lipodystrophies. *Am J Med* 2000; 108(2):143-52.
- Capeau J, Magré J, Lascols O, Caron M, Béréziat V, Vigouroux C, et al. Diseases of adipose tissue: genetic and acquired lipodystrophies. *Biochem Soc Trans* 2005;33(Pt 5):1073-7.
- Oliveira J, Freitas P, Lau E, Carvalho D. Barraquer-Simons syndrome: a rare form of acquired lipodystrophy. *BMC Res Notes* 2016;9(1):175.
- Misra A, Peethambaram A, Garg A. Clinical features and metabolic and autoimmune derangements in acquired partial lipodystrophy: report of 35 cases and review of the literature. *Medicine (Baltimore)* 2004;83(1): 18-34.
- Muto Y, Fujimura T, Kakizaki A, Tsuchiyama K, Kusakari Y, Aiba S. Adult-onset acquired partial lipodystrophy accompanied by rheumatoid arthritis. *Case Rep Dermatol* 2015;7(1): 70-4.
- Payavpipapong K, Niumpradit N, Nakakes A, Buranawuti K. A rare case of acquired partial lipodystrophy (Barraquer-Simons syndrome) with localized scleroderma. *Int J Dermatol* 2014;53(1):82-4.
- Pretel M, Navedo M, Marqués L, Aguado L. Adult dermatomyositis associated with lipodystrophy. *Actas Dermosifiliogr* 2013;104(8): 724-5.
- Pope E, Janson A, Khambalia A, Feldman B. Childhood acquired lipodystrophy: a retrospective study. *J Am Acad Dermatol* 2006;55(6):947-50.
- Biasi D, Caramaschi P, Carletto A, Bambara LM. A case of acquired partial lipodystrophy associated with localized scleroderma and undifferentiated connective tissue disease. *Rheumatol Int* 1999;19(1-2):75-6.
- Cronin CC, Higgins TJ, Molloy M. Lupus, C3 nephritic factor and partial lipodystrophy. *QJM* 1995;88(4):298-9.
- Font J, Herrero C, Bosch X, Cervera R, Ingelmo M, Mascaró JM. Systemic lupus erythematosus in a patient with partial lipodystrophy. *J Am Acad Dermatol* 1990;22(2 Pt 2):337-40.
- Quecedo E, Febrer I, Serrano G, Martinez-Aparicio A, Aliaga A. Partial lipodystrophy associated with juvenile dermatomyositis: report of two cases. *Pediatr Dermatol* 1996;13(6): 477-82.
- Walport MJ, Davies KA, Botto M, Naughton MA, Isenberg DA, Biasi D, et al. C3 nephritic factor and SLE: report of four cases and review of the literature. *QJM* 1994;87(10):609-15.
- Torrelo A, España A, Boixeda P, Ledo A. Partial lipodystrophy and dermatomyositis. *Arch Dermatol* 1991;127(12):1846-7.

15. Prasad NR, Reddy PA, Menon B, Karthik TS, Ahmed F, Chakravarthy M. Recurrent stroke as a presenting feature of acquired partial lipodystrophy. *Indian J Endocrinol Metab* 2012;16(Suppl 2):S455-7.
16. Robertson DA, Wright R. Cirrhosis in partial lipodystrophy. *Postgrad Med J* 1989;65(763): 318-20.
17. Garlapati K, Rembers A, Dara B, Boringi M. Acquired partial lipodystrophy: an atypical presentation with therapeutic challenge. *J Indian Acad Oral Med Radiol* 2015; 27(3):464-7.
18. Akinci B, Koseoglu FD, Onay H, Yavuz S, Altay C, Simsir IY, et al. Acquired partial lipodystrophy is associated with increased risk for developing metabolic abnormalities. *Metabolism* 2015;64(9):1086-95.