

Stridor as the Initial Presenting Symptom of Infant Tuberculosis: Case Report

Stridor ile Başvuran Tüberkülozlu Süt Çocuğu Olgusu

Seçil ARSLANSOYU CAMLAR, MD,^a
Arzu BABAYIĞIT, MD,^b
Balahan MAKAY, MD,^c
Duygu ÖLMEZ, MD,^b
Pakize KARAKAYA, MD,^a
Nevin UZUNER, MD,^b
Özden ANAL, MD^c

Departments of

^aPediatrics

^bPediatric Allergy,

^cPediatric Immunology,

Dokuz Eylül University

Faculty of Medicine, İzmir

Geliş Tarihi/Received: 09.05.2009

Kabul Tarihi/Accepted: 24.09.2009

Yazışma Adresi/Correspondence:

Seçil ARSLANSOYU CAMLAR, MD

Dokuz Eylül University

Faculty of Medicine,

Department of Pediatrics, İzmir,

TÜRKİYE/TURKEY

secilars@yahoo.com

ABSTRACT Tuberculosis is still a major health problem in developing countries in endemic areas and household contact is an important risk factor in contamination. The clinical manifestations and laboratory findings of tuberculosis may be insidious and non-specific. Severe stridor may rarely be the presenting symptom of tuberculosis especially in infants. Here, a previously healthy infant admitted with severe stridor and diagnosed as disseminated tuberculosis was reported. We emphasize that tuberculosis is a very rare cause of stridor in infancy but should be considered in differential diagnosis, especially in infants who have risk factors and live in endemic areas for TB.

Key Words: Infant; tuberculosis; respiratory sounds

ÖZET Tüberküloz gelişmekte olan endemik ülkelerde hala önemli bir sorun oluşturmaktadır ve bulaşmada ev içi temas önemli bir risk faktörüdür. Tüberkülozun klinik ve laboratuvar bulguları sinsi seyredebilir ve özgül olmayabilir. Ciddi stridor, tüberküloz için özellikle de süt çocukluğu döneminde oldukça nadir bir başvuru semptomudur. Burada öncesinde sağlıklı olan, ağır stridor ile başvurup dissemine tüberküloz tanısı alan bir süt çocuğu olgusu sunulmuştur. Tüberküloz süt çocukluğu döneminde stridorun oldukça nadir bir nedenidir ve ayırıcı tanıda özellikle risk faktörü olan ve tüberküloz için endemik bölgede yaşayan çocuklarda göz önünde bulundurulması gerekir.

Anahtar Kelimeler: Bebek; tüberküloz; solunum sesleri

Türkiye Klinikleri J Pediatr 2010;19(4):334-7

Tuberculosis (TB) is still a major health problem in developing countries in endemic areas. Disseminated TB is caused by the hematogenous spread of *Mycobacterium tuberculosis* from a pulmonary or extrapulmonary focus.^{1,2} Extrapulmonary tuberculosis forms such as meningeal disease and disseminated tuberculosis occur more frequently in young children.³

The clinical manifestations and laboratory findings of TB, may be insidious and non-specific.^{1,4} The common presentations in children are cough and respiratory symptoms, weight loss and anorexia, and low grade fever.⁵ Severe dyspnea and rarely stridor may be the presenting symptom of TB especially in infants.^{6,7} Stridor is commonly observed in children with croup, foreign bodies, trauma, and congenital anomalies such as laryngomalacia or tracheomalacia.⁸

Herein, we report a three-months-old girl admitted with severe stridor, cough and dyspnea that diagnosed as disseminated tuberculosis.

CASE REPORT

A three months old girl was admitted with stridor and cough. Stridor has started three weeks prior to admission; cough was added ten days ago. She was diagnosed as croup and given nebulised steroid and bronchodilator therapy by her family physician, however; there was no relief of her symptoms. She continued to have cough attacks and stridor that woke her up at night. On physical examination; her weight (6.5 kg), height (58 cm) and head circumference (42 cm) were at 50th centiles for her age. She had one BCG scar. Her body temperature was 37 °C; respiratory rate was 52/min, and oxygen saturation was 94% in room air. She had tachypnea and severe stridor. She had no rales or ronchi on chest auscultation. The remainder of the physical examination was unremarkable. Laboratory findings were as follows: white blood cell count, 15.700/mm³ with 55% polymorphonuclear leukocytes, 34% lymphocytes, 10% monocytes; hemoglobin 11 g/dl; platelets 562.000/mm³; and C-Reactive Protein (CRP) 58.24 mg/L (N:0-5 mg/L). Lateral airway X ray was normal and neck computerized tomography (CT) (Figure 1) revealed necrotic lymph nodes, the largest one was two centimeters in diameter, compressing the trachea. Chest X ray (Figure 2) re-

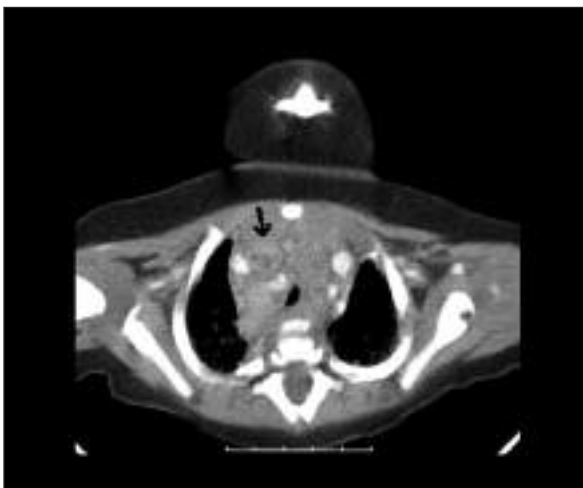


FIGURE 1: Neck CT; necrotic lymph nodes compressing the trachea.

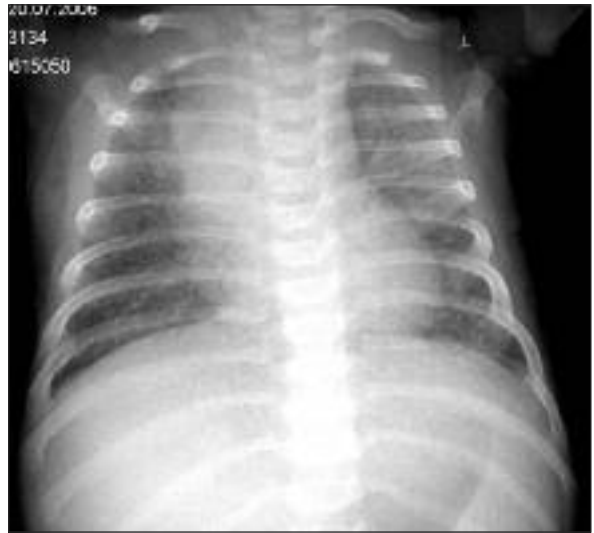

FIGURE 2: Chest X ray; bilateral reticulonodular densities.

vealed bilateral reticulonodular densities. Computerized tomography of thorax (Figure 3) revealed parenchymal diffuse micronodular pattern. These radiological findings strongly suggested tuberculosis. Multiple hypoechoic lesions in the spleen were detected in the abdominopelvic ultrasound. Lumbar puncture was performed in order to exclude central nervous system involvement. Laboratory findings of cerebrospinal fluid (CSF) were as follows: 10 cells/mL protein level 23 mg/dl (N:15-45 mg/dl), glucose 53 mg/dl (N:32-82 mg/dl) and chlorur 125. Polymerase chain reaction (PCR) for *Mycobacterium tuberculosis* was negative. Cultures of CSF grew no bacteria. Cranial CT was normal. She was started antituberculosis therapy. Isoniazid, rifampicin, morphpzinamide, and streptomycin were given for the first two months, continued as isoniazid and rifampicin for the following ten months. Prednisolone therapy was used for the lymph nodes compressing the airways. *Mycobacterium tuberculosis* was ultimately yielded in the three consecutive morning gastric aspirates of the patient (sensitive to streptomycin, isoniazid, rifampicin, pyrazinamide and ethambutol). Family screening revealed that her father had TB. There was a cavitation on the father's chest X-ray. *Mycobacterium tuberculosis* was detected on his sputum cultures. Index case was treated with four antituberculosis drugs. The other family members, mother

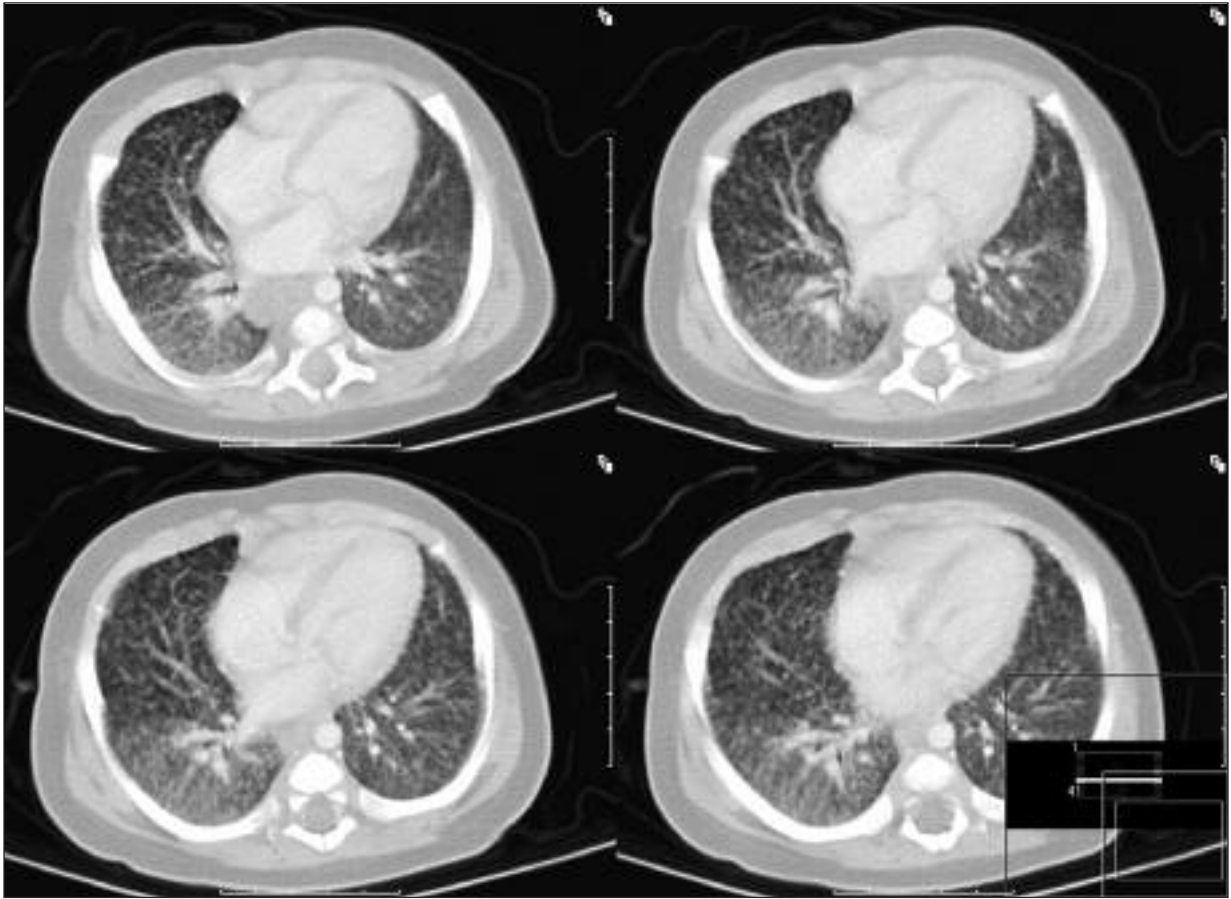


FIGURE 3: Thorax CT; parenchymal diffuse micronodular pattern.

and grandmother, living in the same house with the patient were healthy, and they were given isoniazid prophylaxis.

DISCUSSION

Children presenting with stridor, dyspnea and cough are quite regularly seen with a large variety of causes. Stridor, associated with obstruction of the laryngeal area or the extrathoracic trachea, is commonly observed in children with croup, foreign bodies, trauma, and congenital anomalies such as laryngomalacia or tracheomalacia.⁸ The presented case had no history of either foreign body aspiration or trauma, and her complaints had started 3 weeks prior to admission. Her complaints did not started after birth that usually seen in congenital anomalies. When she was admitted with stridor, her lateral airway X ray and neck CT were evaluated in the emergency department. Necrotic lymph

nodes, the largest two centimeters in diameter, compressing the trachea were detected at the upper mediastinum. With the aid of both radiologic and microbiologic findings, the definitive diagnosis in the presented infant was established.

The diagnosis of disseminated TB can be difficult and a high index of suspicion is required.⁹ It may mimic many diseases.² Although the clinical picture may be acute, more often it is indolent and prolonged, with spiking fever accompanying the release of organisms into the bloodstream.^{1,2,9} Impaired cell-mediated immunity underlies the development of disease,¹ and it is more commonly seen in infants and children under 5 years of age.^{1,10} The clinical manifestations and laboratory findings of TB may be insidious and non-specific.^{1,4} Stridor is an unusual presenting symptom for children with tuberculosis. The mechanism for stridor in patients with tuberculosis is either intrinsic airway com-

pression secondary to a laryngeal or endobronchial lesion or extrinsic airway compression secondary to lymphadenopathy or abscess.^{6,7} Approximately one-quarter of patients with hilar adenopathy may have bronchial compression in children with pulmonary tuberculosis,¹¹ but rarely results in obstruction.⁶ Stridor may also be a symptom of laryngeal TB.¹² There are only few case reports describing laryngeal TB in children.¹³ Ramadan et al. describe three children with laryngeal TB who presented with stridor.¹⁴

Tuberculosis is still a major health problem in developing countries in endemic areas and household contact is an important risk factor. In our case, the father was diagnosed as pulmonary TB with chest x-ray and microbiologic findings. *Mycobacterium tuberculosis* was also detected in the cultures of sputum.

Miliary TB is uniformly fatal if not treated. The American Academy of Pediatrics advocates 9 months of treatment. In the presence of associated TB meningitis, treatment needs to be given for at least 12 months.¹ Corticosteroid treatment is a useful adjunct in treating some forms of extrapulmonary TB, specifically meningitis and pericarditis caused by drug-susceptible organisms.^{4,9,15} The presented case was given antituberculosis therapy with four drugs and prednisolone as the lymph nodes were compressing the airways.

In conclusion, we report a pediatric case presented with stridor and diagnosed as disseminated TB affecting the airways, lung and spleen. In the differential diagnosis of stridor, TB should be taken into consideration, especially in infants who have risk factors and live in endemic areas for TB.

REFERENCES

- Sharma SK, Mohan A, Sharma A, Mitra DK. Miliary tuberculosis: new insights into an old disease. *Lancet Infect Dis* 2005;5(7):415-30.
- Hasibi M, Rasoulinejad M, Hosseini SM, Davari P, Sahebani A, Khashayar P. Epidemiological, clinical, laboratory findings, and outcomes of disseminated tuberculosis in Tehran, Iran. *South Med J* 2008;101(9):910-3.
- Uysal G, Dogru U. [Immunology of childhood tuberculosis and recent advances]. *Turkiye Klinikleri J Pediatr* 1999;8(3):158-63.
- Mert A, Bılır M, Tabak F, Ozaras R, Oztürk R, Sentürk H, et al. Miliary tuberculosis: clinical manifestations, diagnosis and outcome in 38 adults. *Respirology* 2001;6(3):217-224.
- Ozcelik U. Clinical findings and diagnosis in childhood tuberculosis. *Turkiye Klinikleri J Pediatr Sci* 2006;2(3):26-31.
- De Ugarte DA, Shapiro NL, Williams HL. Tuberculous mediastinal mass presenting with stridor in a 3-month-old child. *J Pediatr Surg* 2003;38(4):624-5.
- Matthews PC, Pickles J, Berry J, Salisbury JR, Barker RD, Ervine M. Airway emergency in tuberculosis. *J Infect* 2006;52(5):e147-50.
- Boat TF. Chronic or recurrent respiratory symptoms. In: Behrman RE, Kliegman RM, Jenson HB, eds. *Nelson Textbook of Pediatrics*. 17th ed. Philadelphia: Saunders; 2004 p.1403-4.
- Munoz FM, Starke JR. Tuberculosis. In: Behrman RE, Kliegman RM, Jenson HB, eds. *Nelson Textbook of Pediatrics*. Philadelphia: Saunders; 17thed. 2004 p. 964-972, 1417-9.
- Cruz AT, Starke JR. Clinical manifestations of tuberculosis in children. *Paediatr Respir Rev* 2007;8(2):107-17.
- Andronikou S, Joseph E, Lucas S, Brachmeyer S, Du Toit G, Zar H, et al. CT scanning for the detection of tuberculous mediastinal and hilar lymphadenopathy in children. *Pediatr Radiol* 2004;34(3):232-6.
- Wang CC, Lin CC, Wang CP, Liu SA, Jiang RS. Laryngeal tuberculosis: a review of 26 cases. *Otolaryngol Head Neck Surg* 2007; 137(4):582-8.
- Singh K, Kaur G, Parmar TL. Pseudo tumoral laryngeal tuberculosis. *Indian Pediatr* 2003; 40(1):49-52.
- Ramadan HH, Wax MK. Laryngeal tuberculosis. A cause of stridor in children. *Arch Otolaryngol Head Neck Surg* 1995;121(1): 109-12.
- Blumberg HM, Burman WJ, Chaisson RE, Daley CL, Etkind SC, Friedman LN, et al; American Thoracic Society, Centers for Disease Control and Prevention and the Infectious Diseases Society of America. American Thoracic Society/Centers for Disease Control and Prevention/Infectious Diseases Society of America: treatment of tuberculosis. *Am J Respir Crit Care Med* 2003;167(4):603-62.