

# Diffuse Venous Thrombosis, Intracardiac Thrombus and Coronary-Pulmonary Artery Fistula in a Patient with Behçet's Disease: Case Report

## Behçet Hastalığı Olan Bir Vakada Yaygın Venöz Tromboz, İnttrakardiyak Trombüs ve Koroner-Pulmoner Arter Fistülü

Dilek ÇİÇEK, MD,<sup>a</sup>  
Ahmet ÇAMSARI, MD,<sup>a</sup>  
Türkyay ÖZCAN, MD<sup>a</sup>

<sup>a</sup>Department of Cardiology,  
Mersin University, Faculty of Medicine,  
Mersin

Geliş Tarihi/Received: 04.06.2008  
Kabul Tarihi/Accepted: 21.12.2008

Yazışma Adresi/Correspondence:  
Dilek ÇİÇEK, MD  
Mersin University, Faculty of Medicine,  
Department of Cardiology, Mersin,  
TÜRKİYE/TURKEY  
drdilekcecek@hotmail.com

**ABSTRACT** Behçet's disease is a systemic inflammatory disease. Cardiovascular manifestations are reported in some patients. We report a young man with Behçet's disease with intracardiac thrombus, diffuse venous thrombosis, Budd-Chiari syndrome and a fistula between coronary artery and pulmonary artery. Thrombi in the right heart cavities can be seen in Behçet's disease and may lead to recurrent pulmonary emboli. Additionally, we have to be careful about myocardial ischemia in patients with Behçet's disease.

**Key Words:** Behçet's syndrome, thrombosis, myocardial ischemia

**ÖZET** Behçet hastalığı sistemik inflamatuvar bir hastalıktır. Bazı hastalarda kardiyovasküler tutulum rapor edilmiştir. Bu yazıda, intrakardiyak trombüs, yaygın venöz tromboz, Budd-Chiari sendromu ve koroner arter-pulmoner arter arası fistülü olan ve Behçet hastalığı tanısı konulan genç bir erkek hastayı sunduk. Behçet hastalığında sağ kalp boşluklarında trombüs olabilir ve tekrarlayan pulmoner emboliye neden olabilir. Ayrıca, Behçet hastalarında miyokard iskemisine de dikkat etmemiz gerekir.

**Anahtar Kelimeler:** Behçet sendromu, tromboz, miyokardiyal iskemi

Türkiye Klinikleri J Med Sci 2010;30(2):755-8

Behçet's disease was first defined by Professor Hulusi Behçet in 1937 as an illness characterized by oral aphthous lesions, iridocyclitis and genital ulcers.<sup>1</sup> Since Hulusi Behçet, various manifestations of the disease have been recognized like erythema nodosum, acne-like dermatological manifestations, arthritis and neurological and cardiovascular disorders.<sup>2</sup>

Cardiovascular manifestations are reported in 7-46% of patients and mortality occurs in up to 20% of the patients with marked vascular involvement.<sup>3</sup> The prevalence of Budd-Chiari syndrome in patients with Behçet's disease is reported less than 5%.<sup>4</sup> We report a young man with incomplete Behçet's disease with intracardiac thrombus, diffuse venous thrombosis, Budd-Chiari syndrome and a fistula between coronary artery and pulmonary artery.

## CASE REPORT

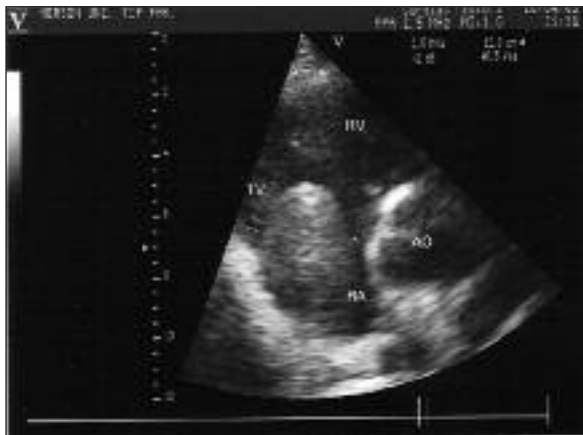A 26-year-old male was admitted to emergency department with dyspnea, fever, cough and hemoptysis. Physical examination revealed a systolic murmur of grade 2/6 in the thirth intercostal space, right parasternal region. He had hepatomegaly, ascites and blue-purple skin lesions on the lower extremities. Electrocardiography showed sinus rhythm and incomplete right bundle branch block. There was left paracardiac infiltration in the chest X-ray. Preliminary diagnosis was pulmonary embolism. Transthorasic echocardiography demonstrated a big atrial thrombus in the right atrium, attached to the septum (40 x 25 mm) (Figure 1a). In addition, mitral valve prolapse and mild mitral regurgitation were detected. Abdominal Doppler ultrasonography was concordant with suprahepatic vena cava thrombosis. In the spiral computed tomography, thrombus was detected in the hepatic veins, inferior vena cava, right atrium and left pulmonary artery. There were wedge shaped consolidations in the basal segments of the lungs that might be secondary to pulmonary emboli. There was a right sided pleural effusion and ascites in the abdomen.

Pathological laboratory findings included the fibrinogen 431 mg/dL (ranges between 146-400), Ig E levels 603.9 IU/mL (0-100), C-reactive protein 61 mg/L, sedimentation 54 mm/hr and protein-C levels 10% (78-134%). Anti nuclear antibody, ds DNA,

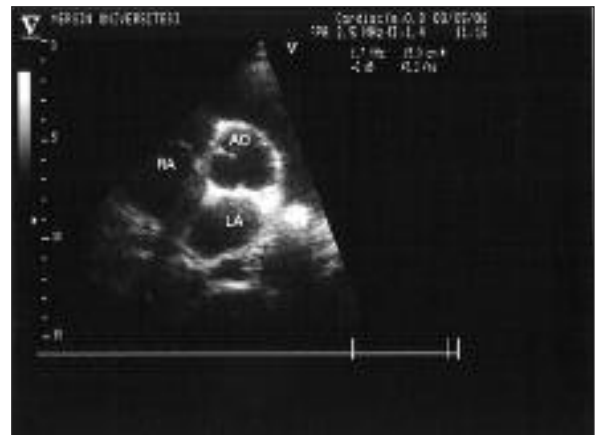Anti-ENA profile and ANCA were negative. Antithrombin III, rheumatoid factor, Ig G, Ig A, Ig M, C3 and C4 levels were normal. Pathergy test was negative. Ocular examination was normal. A varicocele was detected on urological examination.

Because of oral aphthosis, erythema nodosum-like lesions on the extremities, cardiac and inferior vena cava thrombosis, the patient was diagnosed as incomplete Behçet's syndrome. Budd-Chiari syndrome was diagnosed because of diffuse inferior vena cava and hepatic vein thrombosis, painful hepatomegaly, massive ascites and slightly increased liver enzymes. First, heparin infusion was started intravenously and anticoagulant treatment was continued with coumadin to maintain INR between two and three. Pulse therapy was performed using corticosteroid (1 gr/day) for three days and cyclophosphamide (1000 mg IV infusion) for five days followed by oral administration of colchicine 3 x 0.5 mg. Thrombus size has substantially decreased. After 13 months of therapy, thrombi in the right atrium and inferior vena cava resolved completely (Figure 1b).

During this period, patient complained of chest pain with exercise. Conventional electrocardiography showed no evidence of myocardial ischemia. Treadmill exercise testing showed no ST-T changes at a maximum heart rate of 176 beats/min. The technetium-99m-MIBI myocardial imaging



a



b

**FIGURE 1:** Transthoracic echocardiography, parasternal short-axis view a) image of a big thrombus in the right atrium (arrows) b) after treatment, complete resolution of the thrombus.

AO: aort valve, RA: right atrium, RV: right ventricle, TV: tricuspid valve, LA: left atrium.

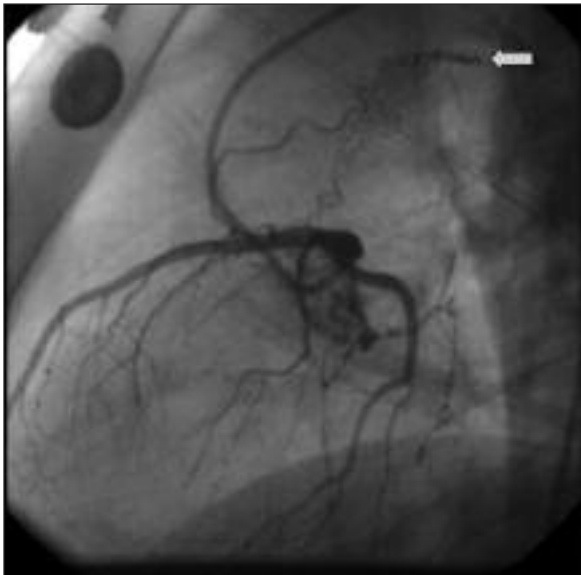scintigraphy (SPECT) with dipyridamole was performed to evaluate myocardial ischemia. Transient perfusion defects were identified in the apical anteroseptal and basal inferior segments of left ventricle. In the coronary angiography, a convoluted fistula was found between the left anterior descending artery and pulmonary artery (Figure 2). Fistula was not suitable for transcatheter closure and we did not plan surgery. No abnormal findings were noted in any other branches of the coronary artery.

## DISCUSSION

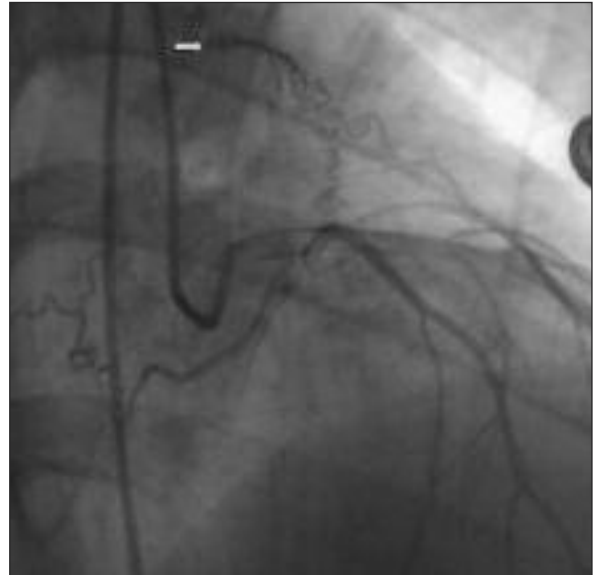
Behçet's disease is a systemic inflammatory disorder affecting multiple organs with a generalized vasculitis. Heart lesions include coronary arteritis, coronary artery aneurysm, endocarditis, ventricular arrhythmias, myocarditis, valvular regurgitation, mitral valve prolapse, pericarditis, acute myocardial infarction, silent myocardial ischemia, intracardiac thrombus, left ventricular aneurysm and congestive cardiomyopathy.<sup>3</sup> Vasculitis may involve large, medium, and small vessels of both the arterial and venous system and may cause thrombus formation in the lumen of vessels as well as aneurysmal lesions and arteriovenous fistula.<sup>5</sup> Budd-Chiari syndrome may be detected as a complication of Behçet's disease.<sup>4,6</sup>

Intracardiac thrombus formation is not very common in Behçet's disease. Mogulkoc and colleagues had reviewed intracardiac thrombus in Behçet's disease in 2000.<sup>7</sup> They found 24 cases in previously published 21 reports, mostly from the Mediterranean region and the Middle East. Young men appear to be most at risk with frequently right heart involvement.<sup>7</sup> After 2000, when we reviewed the National Library of Medicine's MEDLINE, we found that all of Behçet's disease cases with intracardiac thrombus had right heart involvement and most of them were young male patients.<sup>8-16</sup> In the differential diagnosis of intracardiac thrombus; hypereosinophilic syndrome, carcinoid syndrome and myxoma must be evaluated.

The reason for the tendency to intracardiac thrombus in Behçet's disease is still unclear. Endomyocardial fibrosis may have a role in the development of thrombus in some patients. Disseminated damage of endothelial tissue may be correlated with multiple endothelial cell dysfunctions and subsequent hemostatic abnormalities.<sup>17</sup> The coagulation abnormalities may also contribute to thrombotic complications.<sup>18</sup> The patient in our case had decreased protein-C levels. However, the cause of decreased levels of protein-C may be acute thrombosis and anticoagulation therapy. Medical



a



b

**FIGURE 2:** Coronary angiography, fistula from the left anterior descending artery to pulmonary artery (arrow) a) left lateral projection b) right anterior oblique projection.

treatment including corticosteroids, immunosuppressive drugs and anticoagulants should be considered as the first line treatment. If thrombus is massive and extensive, surgical treatment may be considered. Recurrence after surgery is very high.<sup>8,14,15</sup>

Budd-Chiari syndrome is a congestive hepatopathy caused by blockage of hepatic veins. Hepatic vein thrombosis in Behçet's disease is likely secondary to inferior vena cava thrombosis.<sup>4</sup>

A very rare complication in patients with Behçet's disease is the development of arterial fistula.<sup>5,19,20</sup> Our patient had a convoluted fistula detected in the coronary angiography. Although contrast material was not seen in the pulmonary artery, the fistula was thought to be between the left anterior descending artery and pulmonary artery because of its location. Definite orientation can be determined if three-dimensional tomography is performed. Apical anteroseptal and basal inferior myocardial perfusion defects were detected in SPECT. Basal inferior ischemia is not thought to be resulting from the coronary fistula. Coronary fistula may be an in-

cidental finding in addition to Behçet's disease. In some reports, silent myocardial ischemia was shown on myocardial perfusion scintigraphy, and vasculitis of coronary arteries was thought as the possible cause of the myocardial ischemia.<sup>21,22</sup>

Interesting issues about our case which must be emphasized are: (1) unusual presentation of Behçet's disease with intracardiac thrombus and pulmonary emboli, (2) diffuse inferior vena cava and hepatic vein thrombosis and Budd Chiari Syndrome (3) complete resolution of intracardiac and venous thrombosis and recovery of Budd-Chiari syndrome with immunosuppressive and anticoagulation therapy, and (4) fistula between coronary artery and pulmonary artery and myocardial ischemia.

We conclude that thrombi in the right heart cavities can be present in Behçet's disease and may lead to recurrent pulmonary emboli. Behçet's disease must be kept in mind in the differential diagnosis of intracardiac mass lesions. In addition, we have to be careful about myocardial ischemia in patients with Behçet's disease.

## REFERENCES

- Behçet H. [About recurrent aphthous ulcers in the mouth, on the eye and the genitals caused by a virus]. *Dermatol Wochenschr* 1937; 105(36):1052-7.
- Al-Otaibi LM, Porter SR, Poate TWJ. Behçet's disease: A review. *J Dent Res* 2005;(3):209-22.
- Kırımlı Ö, Pabuccu T. [Behçet's disease with multisystem involvements: cardiovascular complications]. *Türkiye Klinikleri J Int Med Sci* 2007;3(9): 36-9.
- Aydinli M, Bayraktar Y. Budd-Chiari syndrome: etiology, pathogenesis and diagnosis. *World J Gastroenterol* 2007;13(19):2693-6.
- Wechsler B, Lê Thi Huong Du LT, de Gennes C, Blétry O, Piette JC, Mathieu A, et al. [Arterial manifestations of Behçet's disease. 12 cases]. *Rev Med Interne* 1989;10(4):303-11.
- Bayraktar Y, Balkanci F, Bayraktar M, Calguneri M. Budd-Chiari syndrome: a common complication of Behçet's disease. *Am J Gastroenterol* 1997;92(5):858-62.
- Mogulkoc N, Burgess MI, Bishop PW. Intracardiac thrombus in Behçet's disease: a systematic review. *Chest* 2000;118(2):479-87.
- Ben Ghorbel I, Ibn Elhadj Z, Khanfir M, Braham A, Fekih M, Drissa H, et al. [Intracardiac thrombus in Behçet's disease. A report of three cases]. *J Mal Vasc* 2004;29(3):159-61.
- Hassikou H, Bono W, Bahiri R, Abir S, Benomar M, Hassouni NH. Vascular involvement in Behçet's disease. Two case reports. *Joint Bone Spine* 2002;69(4):416-8.
- Baykan M, Celik S, Erdöl C, Baykan EC, Durmus I, Bahadır S, et al. Behçet's disease with a large intracardiac thrombus: a case report. *Heart* 2001;85(4):E7.
- Kaya A, Ertan C, Gürkan OU, Fitöz S, Atasoy C, Kiliçkap M, et al. Behçet's disease with right ventricle thrombus and bilateral pulmonary artery aneurysms--a case report. *Angiology* 2004;55(5): 573-5.
- Ozer N, Ciftçi O, Demirci M, Atalar E, Ovünç K, Akşöyek S, et al. Right ventricular outflow tract thrombus in a case of Behçet's disease. *J Am Soc Echocardiogr* 2005;18(4):380-2.
- Hammami S, Mahjoub S, Ben-Hamda K, Brahem R, Gamra H, Ben Farhat M. Intracardiac thrombus in Behçet's disease: two case reports. *Thromb J* 2005;3:9.
- Vayá A, Forner MJ, Estellés A, Villa P, Mira Y, Ferrando F, et al. Intracardiac thrombosis in a case of Behçet's disease associated with the prothrombin 20210G-A mutation. *Haematologica* 2000;85(4): 425-8.
- Kaneko Y, Tanaka K, Yoshizawa A, Yasuoka H, Suwa A, Satoh T, et al. Successful treatment of re-
- current intracardiac thrombus in Behçet's disease with immunosuppressive therapy. *Clin Exp Rheumatol* 2005;23(6):885-7.
- Yakut ZI, Odev K. Pulmonary and cardiac involvement in Behçet disease: 3 case reports. *Clin Appl Thromb Hemost* 2007;13(3):318-22.
- Schmitz-Huebner U, Knop J. Evidence for an endothelial cell dysfunction in association with Behçet's disease. *Thromb Res* 1984;34(4): 277-85.
- Navarro S, Ricart JM, Medina P, Vayá A, Villa P, Todolí J, et al. Activated protein C levels in Behçet's disease and risk of venous thrombosis. *Br J Haematol* 2004;126(4):550-6.
- Nakanishi K, Shichijo T, Yunoki K, Kato G, Nakai M, Oba O. Left ventricle to pulmonary arterial fistula due to Behçet's disease. *Jpn J Thorac Cardiovasc Surg* 2004;52(3):135-8.
- Melua A, Campbell N, McCluskey D, MacGowan SW. Aorto-atrial fistula without aneurysm formation in Behçet's disease. *Heart* 1998;80 (2):200-1.
- Güllü IH, Benekli M, Müderrisoğlu H, Oto A, Kansu E, Kabakçı G, et al. Silent myocardial ischemia in Behçet's disease. *J Rheumatol* 1996;23(2): 323-7.
- Türkölmez S, Gökçora N, Alkan M, Gorer MA. Evaluation of myocardial perfusion in patients with Behçet's disease. *Ann Nucl Med* 2005; 19(3):201-6.