

Medical Treatment of Traumatic Pupillary Capture by Simple Pupil Dilation with Subconjunctival Adrenaline: Case Report

Travmatik Pupilla Yakalanmasının Subkonjonktival Adrenalin Uygulanarak Yapılan Basit Pupilla Dilatasyonu ile Tedavisi

Şaban GÖNÜL,^a
Bengü EKİNCİ KÖKTEKİR,^a
Şansal GEDİK,^a
Berker BAKBAK,^a
Kamil YAVUZER^a

^aDepartment of Ophthalmology,
Selçuk University Faculty of Medicine,
Konya

Geliş Tarihi/Received: 18.12.2012
Kabul Tarihi/Accepted: 16.03.2013

This study was presented as poster at
46th TOD National Congress,
17-21 October 2012, Antalya, Turkey.

Yazışma Adresi/Correspondence:
Şaban GÖNÜL
Selçuk University Faculty of Medicine,
Department of Ophthalmology, Konya,
TÜRKİYE/TURKEY
drsabangonul@gmail.com

ABSTRACT A 51-year-old male was admitted to our clinic with blurred vision, pain, and redness following blunt trauma to his right eye. The patient had a history of right-eye extracapsular cataract extraction, with intraocular lens implantation three years ago. On biomicroscopic examination, a 4+ cell reaction was detected in the anterior chamber, and pupillary capture (PC) was identified between the 9 and 2 o'clock points. In this case, the noninvasive treatment of traumatic PC and uveitis is reported. This case illustrates that, in order to achieve sufficient pupillary dilatation, a subconjunctival injection of adrenaline should be considered in the noninvasive treatment of such patients.

Key Words: Conjunctiva; epinephrine; pupil disorders

ÖZET Elli bir yaşında erkek hasta sağ gözde görme keskinliğinde azalma, ağrı ve kızarıklık şikayetleri ile polikliniğimize başvurdu. Hastanın sağ gözde geçirilmiş ekstra-kapsüler katarakt ekstraksiyonu ve göz içi lens implantasyonu öyküsü mevcuttu. Biyomikroskopik muayenede ön kamarada grade 4 hücre reaksiyonu ve saat 9 ile 2 arasında pupilla yakalanması tespit edildi. Bu olgu sunumunda travmatik pupilla yakalanması ve üveitin medikal tedavisi bildirilmektedir. Böyle olguların medikal tedavisinde yeterli pupilla dilatasyonu sağlamak için subkonjonktival adrenalin kullanımını göz önünde bulundurulmalıdır.

Anahtar Kelimeler: Konjonktiva; epinefrin; pupil bozuklukları

Türkiye Klinikleri J Med Sci 2013;33(4):1192-5

Pupillary capture (PC) is a rare condition where part of the pupillary margin is displaced posteriorly behind the intraocular lens (IOL) optic.¹ It may arise spontaneously or due to a trauma during the early or late postoperative period.¹ In the past, PC was relatively common with an incidence of 3%.² However, its incidence has decreased with modern surgical techniques and IOL designs. Although often being asymptomatic, PC can lead to a pupillary block, chronic uveitis, cystoid macular edema, and posterior capsule opacification.²⁻⁵

The medical treatment of pupillary capture is presented using a practical method, the subconjunctival adrenaline injection. To our knowledge, this is the first report in which subconjunctival adrenaline is used in the medical treatment of pupillary capture.

CASE REPORT

A 51-year-old male was admitted to our outpatient clinic with complaints of blurry vision, pain, and redness after experiencing a blunt trauma to the right eye 1 month ago. He had a history of extracapsular cataract extraction with a posterior chamber IOL implantation in the right eye three years ago, and phacoemulsification with an IOL implantation in the left eye one year ago. His corrected visual acuities were 5/100 in the right eye and 40/50 in the left eye. The biomicroscopic examination of the right eye revealed conjunctival and ciliary injection, and a 4+ cellular reaction in the anterior chamber. The optic of the IOL was entrapped in the pupillary aperture between the 9 and 2 o'clock points. Although the posterior capsule was not intact, there was no visible vitreous fluid in front of the IOL optic. There were no keratic precipitates, hypopyon, white plaques on the posterior capsule or capsular abscess (Figure 1). The intraocular pressures were 15 mmHg in the right eye and 12 mmHg in the left eye. The fundus examination of each eye, and the orbital computed tomography, were within the normal limits (Figure 2). The optical coherence tomography and fundus fluorescein angiography revealed no macular edema in either eye.

The pupillary capture was corrected with the noninvasive repositioning of the posterior chamber IOL after pupillary dilation. The patient was placed on his back, and tropicamide 1% and phenylephrine 2.5% were applied 3 times, at 10 minute intervals. After this application, however, the pupillary diameter did not reach an adequate size for the repositioning of the IOL due to the traumatic uveitis. Therefore, 0.1 ml (0.5 mg/ml) of adrenaline was injected subconjunctivally. Pilocarpine 2% was applied when the pupillary diameter became wider than the IOL optic. The patient was advised to remain on his back, and was kept under close observation, thus the pupil became smaller in front of optic of the IOL. After another dose of pilocarpine, the entire pupillary edge surpassed the optic edge.

On the following day, the pupil was round, the IOL was well centered in the posterior chamber, and there was no anterior chamber reaction (Figure

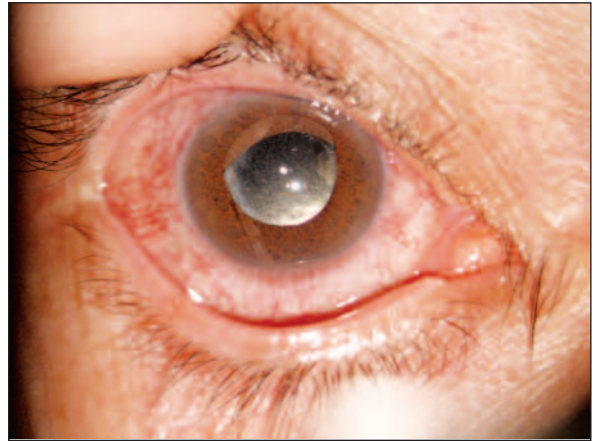

FIGURE 1: Conjunctival and ciliary injection. Pupillary capture between the 9 and 2 o'clock in the right eye.

(See color figure at <http://tipbilimleri.turkiyeklinikleri.com/>)

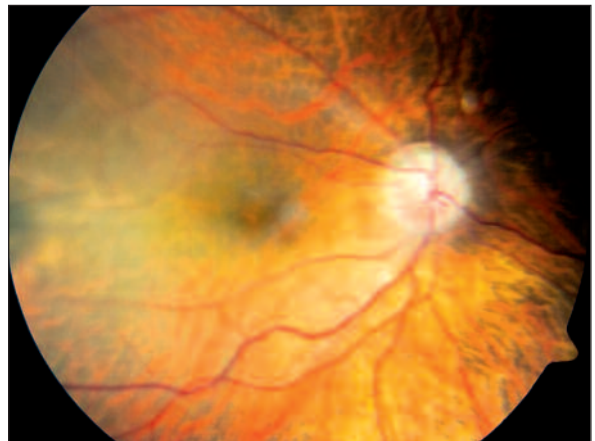

FIGURE 2: Fundus photography within the normal limits.

(See color figure at <http://tipbilimleri.turkiyeklinikleri.com/>)

3). Prednisolone acetate 1.5% was prescribed every 3 hours for 2 weeks, and was interrupted by tapering at first month. No pupillary capture was seen in the control visit 1 month later. The patient was followed for six months, and no recurrence of pupillary capture was seen at the subsequent follow up visits. Before the subconjunctival injection of adrenaline, the patient was questioned about having systemic diseases, including coronary heart disease or a history of by-pass surgery.

DISCUSSION

Pupillary capture is a rare clinical entity where any portion of an IOL optic is displaced anteriorly, in front of the pupillary margin. Small-incision

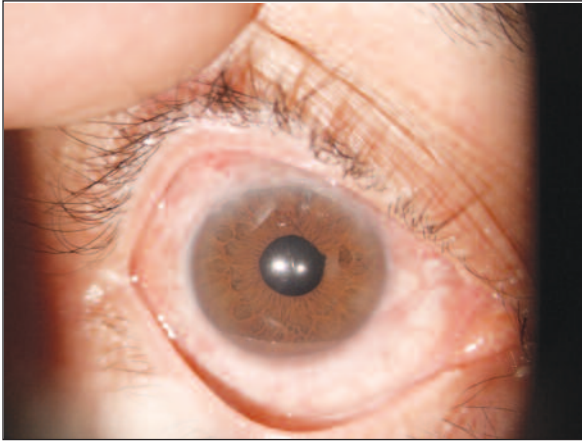


FIGURE 3: Round pupil and well centered IOL in the posterior chamber, after simple dilation.

(See color figure at <http://tipbilimleri.turkiyeklinikleri.com/>)

surgery, with the placement of the IOL in the capsular bag, has reduced the incidences of PC, however, physicians may still experience this complication.⁶ PC is often diagnosed during a follow up visit, and the patient is usually asymptomatic. However, PC causes some complications including a pupillary block, chronic uveitis, cystoid macular edema, and posterior capsule opacification.²⁻⁵ The management of the pupillary capture includes a simple dilation followed by the use of miotic agents, which have a relatively low success rate, and nonsurgical maneuvers including digital manipulation, and external loop manipulation with cotton-tipped swabs and a Posner 4-mirror lens.^{2,6,7} If the anterior chamber contains the vitreous fluid, another non-surgical treatment of the PC with a neodymium: YAG laser has been described.^{8,9} Some authors have also reported performing surgical repositioning and even lens exchange when pupillary capture recurs.⁴

The pseudophakic patients with cellular reaction in the anterior chamber may be considered as low-grade endophthalmitis in the differential diagnosis. However, the patient had no finding of low-grade endophthalmitis including keratic precipitates, hypopyon, white plaques on the posterior

capsule and capsular abscess. In addition, after the cessation of prednisolone acetate drops, the patient was asymptomatic and a slitlamp examination showed no changes during six months follow up visits. Therefore, the patient was not considered as low-grade endophthalmitis.

It is obvious that the invasive management of a PC could aggravate the intraocular inflammation in patients with accompanying uveitis. Therefore, surgical repositioning was not considered as the primary method on our patient, in order to avoid an invasive procedure. The non-surgical method using a neodymium: YAG laser treatment was not either preferred before simple dilation because there was no vitreous fluid in front of the IOL optic.

For these reasons, the simple dilation for the noninvasive treatment of PC was used in the patient with traumatic uveitis. In cases of pupillary capture, a simple dilation may be successful in resolving the capture, provided that the pupillary dilation is complete, surpassing the optic diameter by several millimeters. Since traumatic uveitis was present in our case, tropicamide and phenylephrine, which were previously reported in the treatment with a simple dilation of the PC, could not provide sufficient pupillary diameter. At this stage, cyclopentolate was not applied since it has a longer duration of action, and reduces the effects of the pilocarpine used after the mydriatic agents for a simple dilation. Therefore, adrenaline was injected subconjunctivally, supplying sufficient pupillary diameter, followed by topical pilocarpine application.

In conclusion, a simple dilation should be considered in patients with post traumatic pupillary capture and anterior uveitis, to prevent the need for another invasive surgical procedure. It should be encouraged as a practical method with the subconjunctival injection of adrenaline, in addition to the application of tropicamide and phenylephrine, to achieve sufficient pupillary dilation.

REFERENCES

1. Lavin M, Jagger J. Pathogenesis of pupillary capture after posterior chamber intraocular lens implantation. *Br J Ophthalmol* 1986;70(12):886-9.
2. Lindstrom RL, Herman WK. Pupil capture: prevention and management. *J Am Intraocul Implant Soc* 1983;9(2):201-4.
3. Rahman MQ, Hammer HM, Ramaesh K. Resolution of cystoid macular edema following removal of an anterior chamber intraocular lens with pupil capture. *Can J Ophthalmol* 2009;44(5):614-5.
4. Nagamoto S, Kohzuka T, Nagamoto T. Pupillary block after pupillary capture of an AcrySof intraocular lens. *J Cataract Refract Surg* 1998;24(9):1271-4.
5. Doğanay S, Fırat P, Çankaya C, Koç B. [Pupillary block glaucoma in a patient who underwent inverted implantation of intraocular lens: case report]. *Türkiye Klinikleri J Med Sci* 2012;32(2):524-8.
6. Galvis V, Tello A, Montezuma S. [Delayed pupillary capture and noninvasive repositioning of a posterior chamber intraocular lens after pupil dilation]. *J Cataract Refract Surg* 2002;28(10):1876-9.
7. Bowman CB, Hansen SO, Olson RJ. Noninvasive repositioning of a posterior chamber intraocular lens following pupillary capture. *J Cataract Refract Surg* 1991;17(6):843-7.
8. Steinert RF, Puliafito CA. New applications of the Nd:YAG laser. *J Am Intraocul Implant Soc* 1984;10(3):372-6.
9. Bartholomew RS. Incidence, causes, and neodymium:YAG laser treatment of pupillary capture. *J Cataract Refract Surg* 1997;23(9):1404-8.